



# **Optimal Morphological Criteria Evaluated by Intravascular Ultrasound to Predict Future Clinical Outcomes in the Complex Percutaneous Coronary Intervention Lesions**

**Hanan Saad Salem<sup>a\*</sup>, Atul Mathur<sup>b</sup>, Ehab Abdel Wahab Hamdy<sup>a</sup>,  
Hanan Kamel Kassem<sup>a</sup>, Mai M. Abdel Moniem Salama<sup>a</sup>  
and Seham Fahmy Badr<sup>a</sup>**

<sup>a</sup> *Department of Cardiovascular Medicine, Faculty of Medicine, Tanta University, Tanta, Egypt.*

<sup>b</sup> *Department of Cardiovascular Medicine, Fortis Escorts Heart Institute and Research Center, New Delhi, India.*

## **Authors' contributions**

*This work was carried out in collaboration among all authors. All authors read and approved the final manuscript.*

## **Article Information**

DOI: 10.9734/JAMMR/2022/v34i2031502

## **Open Peer Review History:**

This journal follows the Advanced Open Peer Review policy. Identity of the Reviewers, Editor(s) and additional Reviewers, peer review comments, different versions of the manuscript, comments of the editors, etc are available here: <https://www.sdiarticle5.com/review-history/89163>

**Original Research Article**

**Received 10 May 2022**  
**Accepted 19 July 2022**  
**Published 26 July 2022**

## **ABSTRACT**

**Background:** Intravascular ultrasound (IVUS) guidance of stent implantation can help optimal stent deployment in comparison to angiographic guidance alone. Thus, IVUS guidance might enhance short and long-term clinical outcomes of cases performing percutaneous coronary intervention (PCI). The purpose of this work was to investigate the optimal morphological criteria evaluated by IVUS to predict the clinical outcomes in PCI of complex lesions.

**Methods:** This observational prospective study was carried out on 56 patients who underwent PCI for complex coronary lesions guided by IVUS. All patients were subjected to standard 12-lead electrocardiogram (ECG), routine laboratory examinations [complete blood count (CBC), blood urea and serum creatinine, prothrombin time, and international normalized ratio (INR)], echocardiography, coronary angiography, PCI and IVUS guidance (both pre and post stenting).

**Results:** 7 of 45 cases with coronary bifurcation lesion (CBL) were treated with a two-stent technique that was planned upfront in 5 of them and was applied as a bail-out strategy in 2 cases.

\*Corresponding author: E-mail: [hanan.salem@med.tanta.edu.eg](mailto:hanan.salem@med.tanta.edu.eg);

Whereas, in the remaining 38 cases, provisional stenting strategy was adopted and ended up with one-stent technique that went smooth and uneventful as guided and optimized by adjunctive IVUS. Only one patient (2%) had a non-fatal myocardial infarction 4 months post-index procedure. No incidence of other composite endpoint was encountered during the 6 months follow-up period of the study.

**Conclusions:** Intravascular ultrasound (IVUS) guidance is associated with favourable procedural and clinical results for cases undergoing complex PCI procedures. This well-established evident role of IVUS in complex PCI procedures is driven mainly by the insights it offers that help better upfront procedural planning in addition to acute procedural result optimization.

**Keywords:** Intravascular ultrasound; PCI; complex coronary lesions.

## LIST OF ABBREVIATIONS

|       |   |
|-------|---|
| CABG  | : Coronary artery bypass surgery;             |
| CAD   | : Coronary artery disease;                    |
| CAG   | : Coronary artery angiography;                |
| CBC   | : Complete blood count;                       |
| CBL   | : Coronary bifurcation lesion;                |
| CN    | : Calcified nodule;                           |
| CS    | : Covered stent;                              |
| CSA   | : cross sectional area;                       |
| CTO   | : Chronic total occlusion;                    |
| DES   | : Drug-eluting stent;                         |
| ECG   | : electrocardiogram;                          |
| ESC   | : European Society of Cardiology;             |
| INR   | : international normalized ratio;             |
| IRB   | : Institutional review board;                 |
| IVUS  | : Intravascular ultrasound;                   |
| LAD   | : left anterior descending artery;            |
| LASM  | : late acquired stent malapposition;          |
| LSD   | : longitudinal stent deformity;               |
| LDL   | : Low-density lipoproteins;                   |
| LCX   | : left circumflex artery;                     |
| LVEF  | : Left ventricular ejection fraction;         |
| MACE  | : Major adverse cardiovascular events;        |
| MI    | : Myocardial infarction;                      |
| MLA   | : Minimal lumen area;                         |
| MSA   | : Minimal stent area;                         |
| NC    | : Non-compliant;                              |
| OA    | : Orbital atherectomy;                        |
| PB    | : Plaque burden;                              |
| PCI   | : Percutaneous coronary intervention;         |
| SVG   | : Saphenous venous graft;                     |
| ST    | : stent thrombosis;                           |
| STEMI | : ST-segment elevation myocardial infarction; |
| TLR   | : Target lesion revascularization;            |

demonstration of a 3-dimensional coronary lumen. So, it fails to delineate the anatomy accurately [1].

In addition, lesion features can impair and complicate accurate angiographic evaluation of the disease severity as in patients of lesion foreshortening, eccentricity, angulations, diffuse reference vessel disease, calcification, vessel overlap and streaming of contrast [1].

Complex coronary lesions show unique challenges to the interventional cardiologist and are remaining connected with high risk as represented by higher rates of technical difficulties, stent failure and procedural complications, their outcomes are often not satisfactory [2].

These complex lesions are classifiable by anatomic criteria, involving heavily calcific lesions, thrombus containing culprit lesions, extremely tortuous or angulated vessels and chronic total occlusions, or by location, as bifurcations, saphenous vein grafts and unprotected left main [3,4].

Intravascular ultrasonography (IVUS) has been an essential tool in the cardiac catheterization laboratory for more than two decades, providing valuable information about the coronary vascular lumen anatomy, dimensions, and wall. It has been found to be more accurate and reproducible than traditional angiography for assessing the severity of atherosclerotic disease [1,5,6].

Compared to angiographic guidance alone, IVUS guiding of stent implantation leads to optimal stent deployment. Thus, IVUS guidance might improve short and long-term clinical results of cases performing percutaneous coronary intervention (PCI) [7].

## 1. INTRODUCTION

Coronary angiography remains the gold standard test for the evaluation and diagnosis of coronary artery disease (CAD) as well as for providing reliable effective therapeutic options. But it has a critical limitation as it generates a 2-dimensional

Thus, it is important to evaluate IVUS driven morphological criteria needed to optimize PCI of complex lesions and their role in prediction of clinical results [8,9].

The purpose of this work was to analyse the optimal morphological criteria evaluated by IVUS to predict the clinical outcomes in PCI of complex lesions.

## 2. PATIENTS AND METHODS

This observational prospective study included 56 cases who had unprotected left main lesions, bifurcation lesions, calcified lesions, chronic total occlusions (CTO), thrombus containing lesions, stent failure revascularizations and saphenous vein graft lesions. They underwent PCI for complex coronary lesions guided by IVUS in the period from July 2019 to May 2021.

Exclusion criteria were unsuccessful PCI procedure, intolerance to contrast media, indications for urgent coronary artery bypass surgery (CABG) and cardiogenic shock.

All cases were subjected to history taking, complete clinical assessment, standard 12-lead ECG, routine laboratory analyses [complete blood count (CBC), blood urea and serum creatinine, prothrombin time and international normalized ratio (INR)], echocardiography, coronary angiography, PCI and IVUS guidance (before and after stenting).

### 2.1 Coronary Angiography [10]

Significant coronary lesions are defined according to 2018 ESC/EACTS Guidelines on myocardial revascularization as left main lesion more than 50% stenosis, or proximal left anterior descending artery (LAD) lesion more than 50% stenosis, or more than 90% stenosis in other LAD segments or 70 – 90% stenosis in other major coronary vessel with non-invasive evidence of myocardial ischemia.

Calcification was categorised as moderate (radiopacities noticed only with cardiac motion before contrast injection) or severe (radiopacities noted only with cardiac motion before contrast injection) (radiopacities noted without cardiac motion before contrast injection generally compromising both sides of the arterial lumen). Aorto-ostial lesion was located within 3 mm of the origin of an epicardial artery arising from the aorta. Coronary perforation was demonstrated by dye extravasation during or after the

interventional operation and categorized as type I (extraluminal crater), II (myocardial or pericardial blushing), or III (contrast streaming or cavity spilling) [11]. A computer-aided, automated algorithm (QAngio XA 7.3; Medis Medical Imaging Systems, Leiden, The Netherlands) was utilized for quantitative analysis employing Standard Methodology [12].

**PCI:** All procedures were IVUS-guided, were performed and patients received medications during and after procedures according to the current PCI guidelines [10]. The used stents were all second-generation drug eluting stents.

### 2.2 IVUS Guidance

IVUS was performed using 1 of 3 commercially available systems (OptiCross, Boston Scientific Corporation, Maple Grove, Minnesota; Refinity, Philips, Rancho Cordova, California. Kodama HD, ACIST Medical Systems, Eden Prairie, Minnesota) and automated pullback at 0.5 mm/s or 1.0 mm/s. IVUS run was performed before and after stenting, IVUS catheter was advanced at least 10 mm distal to the lesion after intracoronary administration of nitroglycerin (100 to 200 mg). All IVUS images were stored onto a DVD thereafter for off-line measurements using echoPlaque 3.0 (INDEC Medical Systems, Inc., Mountain View, California). IVUS measurements were done by the treating physician and  $\geq 1$  experienced IVUS technician.

Pre-stenting IVUS run was used to assess lesion severity and morphologic characteristics as composition of plaque, degree of calcification in the plaque to guide the decision of using atherectomy (rotational or orbital) or cutting balloon or to use the regular semi-compliant balloon if no extensive calcifications is there. Calcium was hyperechoic plaque with acoustic shadowing and was classified as superficial when the calcium's leading edge was within the superficial 50 percent of the plaque. Severe calcium was maximum superficial calcium arc  $\geq 270^\circ$ . Protruding calcium was convex-shaped calcium in the lumen. Calcified nodule (CN) was defined as protruding calcium with distinct IVUS features: irregular convex luminal surface and is typically eccentric [13].

Reference segment was defined as a cross-sectional image adjacent to the lesion with less than 40 percent plaque burden. The diameter of the stent was computed using the lumen diameter of the distal reference (ratio of 0.8 to media diameter or 1:1 to lumen diameter).

IVUS was used as well to determine the length of the stents by calculating distance between proximal and distal landing zones with no or less than 50% plaque burden [14].

In moderate left main lesions, IVUS was used to calculate the minimal lumen area (MLA) to evaluate the lesion significance, defining the lesion significant if MLA is less than 6 mm<sup>2</sup>. In moderate non-left main lesions, IVUS was used to measure MLA. For vessels larger than 3.5 mm the lesion will be stented if MLA is <3.6 mm<sup>2</sup>, for vessels larger than 3 mm but smaller than 3.5 mm, lesion will be stented if MLA is < 2.7 mm<sup>2</sup>, for vessels smaller than 3 mm the lesion will be stented if MLA is < 2.4 mm<sup>2</sup> [15].

Post-stenting IVUS run was done to detect stent apposition, expansion and edge dissection/hematoma with proper management accordingly thereafter.

The proximal and distal reference segments were examined statistically and qualitatively for stent edge dissections. Effective lumen cross sectional area (CSA) at the point of the smallest lumen CSA during the dissection segment (lumen CSA minus area behind the dissection flap), maximum dissection angle, and dissection length were measured [16].

### 2.3 Clinical Follow-Up

Incidence of major adverse cardiac events (MACE) in the form of (Death, non-fatal myocardial infarction or target vessel

revascularization) was recorded at 1 and 6 months after hospital discharge.

### 2.4 Statistical Analysis

Continuous data with a normal distribution have been expressed as the mean and standard deviation. Categorical data have been documented as frequency and percent. Statistical analysis was conducted using version 10.0 of SPSS (SPSS Inc., Chicago, Illinois).<sup>7</sup>

### 3. RESULTS

Table 1 shows baseline clinical demographics.

Table 2 shows target vessels, lesions characteristics and procedural details in the studied cases.

Table 3 shows morphological criteria evaluated by IVUS.

Table 4 shows follow up and clinical outcomes in the studied cases.

Patient with significant ostio-proximal LAD lesion with distal left main (LM) that showed ambiguous moderate stenosis by angiography, two IVUS pullbacks from both LAD and left circumflex artery (LCX) were carried out to assess LM lesion, Minimal lumen area (MLA) was more than 6 mm<sup>2</sup>, also ostial LCX showed no significant plaque burden/stenosis, so only a single stent was deployed in ostio-proximal LAD with good results Fig. 1.

**Table 1. Baseline clinical demographics (n = 56)**

|   | <b>Total (n=56)</b> |
|---|---------------------|
| <b>Age, years</b>                               | 73.8±12.2           |
| <b>Male sex</b>                                 | 43 (77)             |
| <b>Hypertension</b>                             | 43 (77)             |
| <b>Dyslipidemia</b>                             | 40 (71)             |
| <b>Diabetes mellitus</b>                        | 29 (52)             |
| <b>Current smoker</b>                           | 24 (43)             |
| <b>Creatinine clearance &lt;60mL/min</b>        | 27 (48)             |
| <b>Prior myocardial infarction</b>              | 12 (21)             |
| <b>Prior percutaneous coronary intervention</b> | 21 (38)             |
| <b>Prior coronary bypass grafting</b>           | 25 (45)             |
| <b>Clinical presentation at index procedure</b> |                     |
| <b>Stable angina</b>                            | 27 (48)             |
| <b>Unstable angina</b>                          | 24 (43)             |
| <b>Non-STEMI or STEMI</b>                       | 5 (9)               |
| <b>Use of statin at admission</b>               | 38 (68)             |
| <b>LVEF%</b>                                    | 56.46±8.30          |

Data are presented as mean ± SD or frequency (%). STEMI=ST-segment elevation myocardial infarction. LVEF=left ventricular ejection fraction

**Table 2. Target vessels, lesions characteristics and procedural details in the studied patients (n=56)**

|                                    | <b>Total (n=56)</b> |
|------------------------------------|---------------------|
| <b>Three vessel disease</b>        | 28 (50)             |
| <b>Target vessel</b>               |                     |
| Left main                          | 34 (61)             |
| Left anterior descending           | 38 (68)             |
| Left circumflex                    | 13 (23)             |
| Right                              | 4 (7)               |
| <b>Saphenous venous graft</b>      | 3 (5)               |
| <b>Lesion type</b>                 |                     |
| Unprotected left main              | 21 (38)             |
| Bifurcation                        | 45 (80)             |
| Calcified                          | 46 (82)             |
| Chronic total occlusion            | 4 (7)               |
| Thrombus containing lesions        | 3 (5)               |
| Stent failure lesions              | 6 (11)              |
| Saphenous venous graft lesions     | 3 (5)               |
| Diffuse                            | 35 (63)             |
| Focal                              | 1 (2)               |
| Aorto-ostial                       | 4 (7)               |
| <b>Access site</b>                 |                     |
| Femoral                            | 44 (79)             |
| Radial                             | 12 (21)             |
| Total stent length, mm             | 46.8±25.0           |
| Maximum stent size, mm             | 3.36±0.42           |
| Maximum balloon pressure, atm      | 19.7±3.3            |
| Maximum device diameter, mm        | 3.72±0.51           |
| Pre-maximum diameter stenosis, %   | 82.7±10.4           |
| Final maximum diameter stenosis, % | 1.7±0.5             |
| Final TIMI flow 3                  | 56 (100)            |
| Contrast amount, mL                | 201±109             |
| Radiation dose, mGy                | 2617±1734           |
| Fluoro time, min                   | 37±16               |
| Procedural time, min               | 125±46              |

*Data are presented as mean ± SD or frequency (%)*

**Table 3. Morphological criteria evaluated by IVUS**

|   | <b>Total (n=56)</b> |
|---|---------------------|
| <b>Pre-stenting morphological criteria</b>                          |                     |
| Plaque burden in treated vessels, %                                 | 78.5 ±8.3           |
| Maximum superficial calcium arc, °                                  | 311 ±42             |
| Superficial calcium arc ≥270°                                       | 49 (88)             |
| Calcified nodule  | 8 (14)              |
| Thrombus  | 3 (5)               |
| <b>Bifurcation lesions</b>  |                     |
| Significant side-branch disease (upfront two-stent technique)       | 5 (9)               |
| Chronic total occlusion lesions                                     |                     |
| Intraplaque position of PTCA wire (along entire course of CTO body) | 2 (4)               |
| Partial subintimal position of PTCA wire                            | 2 (4)               |
| <b>Stent failure lesions (underlying mechanism)</b>                 |                     |
| Marked stent under-expansion due to severe calcium                  | 2 (4)               |
| Stent fracture/mechanical deformity                                 | 1 (2)               |
| Protruding calcified nodule   | 1 (2)               |
| Late acquired stent malapposition                                   | 1 (2)               |

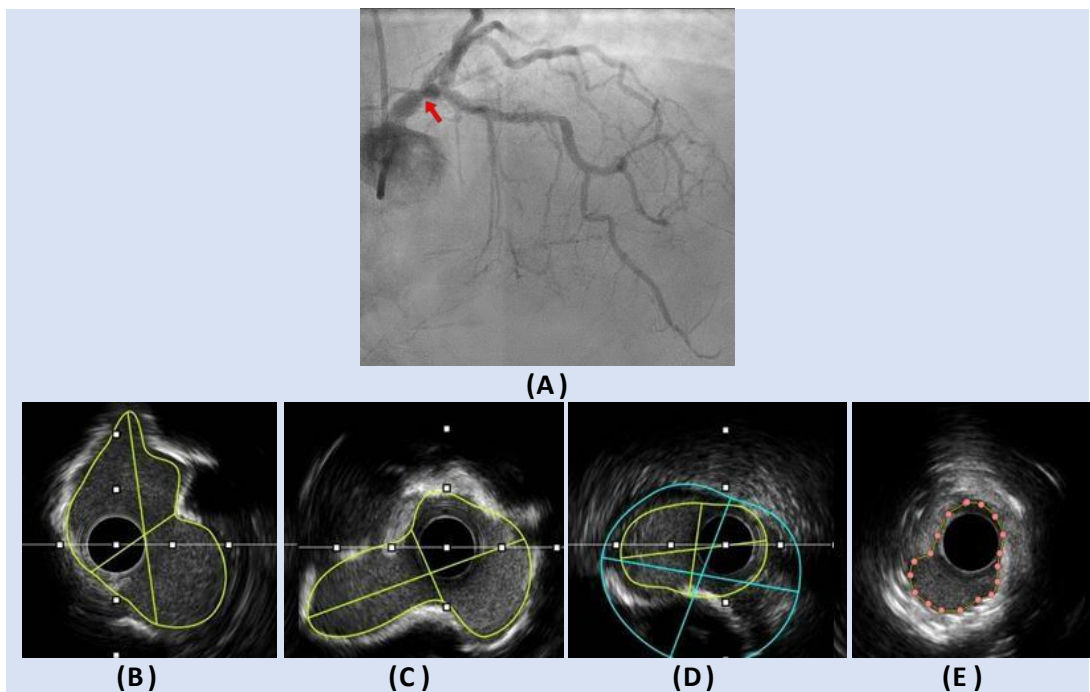
|  | Total (n=56) |
|--|--------------|
| <b>Thrombosis of bioresorbable vascular scaffold</b>     | 1 (2)        |
| <b>Post-stenting morphological criteria</b>              |              |
| Suboptimal stent expansion / incomplete stent apposition | 36 (64)      |
| Acute procedural complications                           | 6 (11)       |
| Medial dissection with intramural hematoma               | 2 (4)        |
| Perforation  | 1 (2)        |
| Geographic miss  | 1 (2)        |
| Longitudinal stent deformity                             | 1 (2)        |
| Accidental stent crushing                                | 1 (2)        |

*Data are presented as mean ± SD or frequency (%)*

**Table 4. Follow up and clinical outcomes (n=56)**

|                                 | Total (n=56) |
|---------------------------------|--------------|
| <b>MACE</b>                     |              |
| Non-fatal myocardial infarction | 1 (2)        |
| All-cause mortality             | 0            |
| Target vessel revascularization | 0            |

*Data are presented as frequency (%), MACE=major adverse cardiac events*



**Fig. 1. A) CAG showed distal LM moderate lesion (red arrow). B) LAD-LM IVUS pullback showed calcific plaque with MLA at distal LM = 6.5 mm<sup>2</sup>. C) LCX-LM IVUS pullback showed calcific plaque with MLA at distal LM = 6.3 mm<sup>2</sup>. D) IVUS image at ostial LCX showed no significant stenosis (MLA = 3.8 mm<sup>2</sup>, PB = 54%). E) IVUS image at proximal LAD lesion, showed significant concentric calcific plaque with MLA = 2.4 mm<sup>2</sup>**

Patient with mid LAD calcific lesion, IVUS run after pre-dilatation showed severe calcium (360° calcium arc) with limited localized calcium fracture achieved by balloon, then orbital atherectomy (OA) was used for adequate lesion preparation prior to stenting, final stent expansion was satisfactory Fig 2.

#### 4. DISCUSSION

IVUS also plays a pivotal role in guidance and optimization of PCI and can improve long-term clinical outcomes. However, IVUS usage in regular PCI remains controversial due to

additional time needed and due to cost consideration [17].

In the present study, only one patient (2%) had MACE in the form of non-fatal myocardial infarction (MI). No incidence of other composite endpoints (i.e., death and target vessel revascularization) was encountered during the six months follow up period of the research.

In agreement with the current research, Hong et al. [18] have recently investigated the effect of pre-stenting IVUS on acute procedural as well as clinical results in a meta-analysis of four clinical trials and concluded that, superior procedural results in terms of a bigger MSA and larger angiographic minimal lumen diameter were detected in pre-stenting IVUS guided PCI procedures. Acute procedural outcomes were significantly favoured in the subset of patients with acute myocardial infarction and small vessels lesions.

In ULTIMATE trial, IVUS identified optimal stent deployment criteria were: 1) the MSA in the stented segment is  $>5.0 \text{ mm}^2$ , or 90% of the MLA at the distal reference segment; 2) plaque burden (PB) less than 50% in the segment 5-mm proximal or distal to the stent edge; and 3) no edge dissection includes media with a length  $>3 \text{ mm}$  [19].

In agreement with the clinical benefits proved by follow-up of cases enrolled in the present research, Zhang et al. [20] reported that IVUS guidance has decreased overall MACE with myocardial infarction, early and late ST, and mortality during follow-up of at least 1 year.

On contrary to the present study, Park et al. [21] have denied any significantly different outcomes

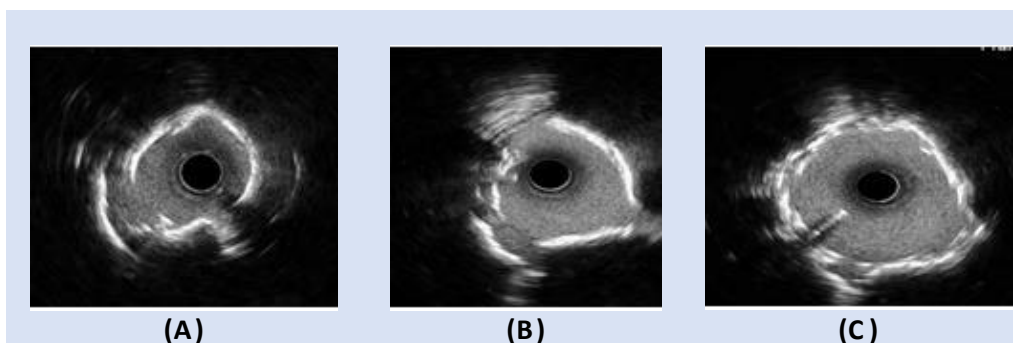
between IVUS- and angiography-guided PCI in terms of MACE or stent thrombosis or in-stent restenosis.

The present study reported that left main (LM) was revascularized in 34 cases (61%), of which 21 cases (38%) had unprotected LM. Acute procedural complications occurred in 2 cases; MACE was detected in only one case of this subgroup in the form of non-fatal MI in the six-month clinical follow up period of the study.

In agreement with these findings, Hernandez et al. [22] have reported that IVUS guidance of PCI with DES in LMS lesions is a predictor of less adverse outcomes. In contrast, the absence of IVUS in LMS PCI has been established as a predictor of MACE, including cardiac mortality, MI, the requirement for TLR, and ST.

Current study included 45 cases (80%) with bifurcation lesions (CBL). Two-stent technique was planned upfront in 5 cases as guided by pre-stenting IVUS evaluation of side-branch. In two cases with adopted provisional stenting strategy, post-stenting medial dissections with large intramural hematoma complicated the procedure and were treated with bailout stenting. One-stent technique was carried out in the remaining 38 cases with satisfactory results as guided and optimized by adjunctive IVUS. MACE was detected in only one case of this subgroup in the six-month clinical follow up time of the study.

In agreement with the present study, Yang et al. [23] have reported favourable clinical outcomes in terms of lower incidence of MACE associated with IVUS guidance of bifurcation lesions PCI method in a recent systematic review and meta-analysis that included five studies involving 7,830 cases with coronary bifurcation lesions.



**Fig. 2. A) IVUS after balloon pre-dilatation, 360° Ca arc can be seen with some fractures caused by balloon inflation, however, most of the calcium arc (2-3 quarters) remained continuous. B) IVUS post RA, islands of calcium can be seen widely separated by multiple nice fractures, and lumen CSA is way larger. C) Final IVUS run post-stenting with satisfactory stent expansion**



In the present study, calcified lesions with at least moderate calcification by angiography were found in 46 cases (82%). Pre-stenting IVUS evaluation demonstrated presence of superficial calcium arc  $\geq 270^\circ$  in 49 cases (88%) and the presence of calcified nodule (CN) in 8 cases (14%). Atherectomy (rotational or orbital) was used in 32 cases (57%) for adequate calcium modification/debulking followed by final optimum acute stent results. No MACE was detected among this lesions subset during clinical follow up period of the research.

Ueki et al [24] highlighted pre-stenting IVUS as a crucial tool to decide if the lesion requires to be modified with atherectomy devices.

Current study included 4 CTO lesions that were successfully treated guided by IVUS (3 cases antegradely and one case retrogradely). IVUS run after successful wire crossing delineated position of the PTCA guidewire indicating partial subintimal course in 2 cases. Also, pre-stenting IVUS has identified mechanical factors that may be incriminated in progression of the disease into CTO in 2 cases (both are in-stent CTO lesions), Post stenting IVUS guided optimization of final procedural results was used. LSD complicated one case and was managed successfully with appropriately sized high pressure balloon inflation. No MACE was encountered among cases of this subgroup during clinical follow up.

In concordance with the present study, Okamura et al. [25] stated that the usage of IVUS to guide CTO PCI might be linked with significant decrease in major adverse cardiac event frequency involving stent thrombosis.

In the present study, two cases of ST were treated; IVUS showed incompletely resorbed BVS in one case and in the other case, LASM of a first-generation DES associated with marked positive remodelling of the vessel were detected. Choi et al. [26] have emphasized the role of IVUS in treatment of ST, it helps the operator to use appropriate stent size as it is usually difficult to assess true vessel dimensions by Coronary artery angiography (CAG) in the presence of large thrombotic burden, so the last stent outcome might be suboptimal in lack of IVUS guidance.

The present study included 6 cases with stent failure. IVUS guidance helped to establish the process and choose the appropriate management accordingly.

In agreement with these findings, Hassan et al. [27] have conducted a meta-analysis which involved persistent and late acquired malapposition in 2,080 cases from 5 randomized trials of 1st generation DES and recommended that there was a rise of very late stent thrombosis (ST) in patients with late stent malapposition versus those without late stent malapposition.

In the current investigation, three cases of SVG lesions PCI were included. In one case, graft perforation complicated the procedure following aggressive NC balloon inflation to correct stent malposition, this was managed by Covered stent (CS) placement with good results. In another case, IVUS assessment of the lesion before stenting provided morphologic criteria suggestive of thickened venous valve. No MACE was found in this subgroup during follow up.

Chowdhury et al., [28] included 37 participants of graft perforation in a review of all participants of graft perforations. Risk factors for perforations involved: old grafts with more than 80% luminal stenosis. Perforations were observed following usage of various cardiac devices with stent placement (30%), balloon angioplasty (36%), post-dilation with NC balloon (16%), guide wire perforation (1 case), post IVUS imaging (1 case) and one case after use of thrombus extraction device.

In the present study, 35 cases (63%) with diffuse lesions were treated successfully with IVUS guidance. The case with reported non-fatal myocardial infarction during follow up period showed diffuse disease at index procedure.

The TULIP study [29] demonstrated favourable angiographic and clinical outcomes in patients with long coronary lesions (> 20 mm) treated under IVUS guidance.

On the contrary, Kim et al. [30] have compared IVUS guidance versus angiography guidance for long coronary stenosis in a randomized study and concluded that the strategy of routine IVUS for DES implantation in long lesions did not improve the 1-year MACE rates.

In the current study, aorto-ostial lesions were treated in 4 cases (7%). Post-stenting IVUS has identified acute procedural mechanical complications in two cases (i.e., geographic miss in one case and LSD in the other case) and they were managed properly under IVUS guidance with optimum results. No MACE was



encountered during clinical follow up of those patients.

In agreement with the present study, Costa et al. [31] have reported higher frequency of geographic miss in this subset of lesions; this is attributed to inadvertent movement of the stent or the so-called melon seeding" phenomenon.

## 5. CONCLUSIONS

IVUS guidance is associated with favourable procedural and clinical outcomes of cases undergoing complex PCI procedures. This well-established evident role of IVUS in complex PCI procedures is driven mainly from the insights it offers that help better upfront procedural planning as well as acute procedural result optimization.

## 6. LIMITATIONS

Small number of cases involved in the study and short – term clinical follow up.

## ETHICAL APPROVAL AND CONSENT

An informed written consent was taken from all cases. The research conformed to the Declaration of Helsinki. The institutional review board (IRB) of hospitals where study was conducted approved research protocol; also, the study was approved by the ethical committee of Tanta University.

## COMPETING INTERESTS

Authors have declared that no competing interests exist.

## REFERENCES

1. Fischer JJ, Samady H, McPherson JA, Sarembock IJ, Powers ER, Gimple LW, et al. Comparison between visual assessment and quantitative angiography versus fractional flow reserve for native coronary narrowings of moderate severity. *Am J Cardiol.* 2002;90:210-5.
2. Mohamed MO, Polad J, Hildick-Smith D, Bizeau O, Baisebenov RK, Roffi M, et al. Impact of coronary lesion complexity in percutaneous coronary intervention: one-year outcomes from the large, multicentre e-Ultimaster registry. *EuroIntervention.* 2020;16:603-12.
3. Baber U, Kini AS, Sharma SK. Stenting of complex lesions: an overview. *Nat Rev Cardiol.* 2010;7:485-96.
4. Krone RJ, Shaw RE, Klein LW, Block PC, Anderson HV, Weintraub WS, et al. Evaluation of the American College of Cardiology/American Heart Association and the Society for Coronary Angiography and Interventions lesion classification system in the current "stent era" of coronary interventions (from the ACC-National Cardiovascular Data Registry). *Am J Cardiol.* 2003;92:389-94.
5. Jensen LO, Thayssen P, Mintz GS, Egede R, Maeng M, Junker A, et al. Comparison of intravascular ultrasound and angiographic assessment of coronary reference segment size in patients with type 2 diabetes mellitus. *Am J Cardiol.* 2008;101:590-5.
6. Tobis J, Azarbal B, Slavin L. Assessment of intermediate severity coronary lesions in the catheterization laboratory. *J Am Coll Cardiol.* 2007;49:839-48.
7. Fitzgerald PJ, Oshima A, Hayase M, Metz JA, Bailey SR, Baim DS, et al. Final results of the Can Routine Ultrasound Influence Stent Expansion (CRUISE) study. *Circulation.* 2000;102:523-30.
8. Kim JS, Hong MK, Ko YG, Choi D, Yoon JH, Choi SH, Hahn JY, Gwon HC, Jeong MH, Kim HS, Seong IW. Impact of intravascular ultrasound guidance on long-term clinical outcomes in patients treated with drug-eluting stent for bifurcation lesions: Data from a Korean multicenter bifurcation registry. *American heart journal.* 2011 Jan 1;161(1):180-7.
9. Nissen SE, Yock P. Intravascular ultrasound: novel pathophysiological insights and current clinical applications. *Circulation.* 2001 Jan 30;103(4):604-16.
10. Neumann FJ, Sousa-Uva M, Ahlsson A, Alfonso F, Banning AP, Benedetto U, et al. 2018 ESC/EACTS Guidelines on myocardial revascularization. *Eur Heart J.* 2019;40:87-165.
11. Al-Mukhaini M, Panduranga P, Sulaiman K, Riyami AA, Deeb M, Riyami MB. Coronary perforation and covered stents: an update and review. *Heart Views.* 2011;12:63-70.
12. van der Hoeven BL. Qualitative and quantitative coronary angiography. In: Topol E TP, editor. *Textbook of Interventional Cardiology.* 2019;87-165.

13. Lee JB, Mintz GS, Lissauskas JB, Biro SG, Pu J, Sum ST, et al. Histopathologic validation of the intravascular ultrasound diagnosis of calcified coronary artery nodules. *Am J Cardiol.* 2011;108:1547-51.
14. Fujino A, Mintz GS, Matsumura M, Lee T, Kim SY, Hoshino M, et al. A new optical coherence tomography-based calcium scoring system to predict stent underexpansion. *EuroIntervention.* 2018; 13:e2182-e9.
15. Waksman R, Legutko J, Singh J, Orlando Q, Marso S, Schloss T, et al. FIRST: Fractional Flow Reserve and Intravascular Ultrasound Relationship Study. *J Am Coll Cardiol.* 2013;61:917-23.
16. Mintz GS, Nissen SE, Anderson WD, Bailey SR, Erbel R, Fitzgerald PJ, et al. American College of Cardiology Clinical Expert Consensus Document on Standards for Acquisition, Measurement and Reporting of Intravascular Ultrasound Studies (IVUS). A report of the American College of Cardiology Task Force on Clinical Expert Consensus Documents. *J Am Coll Cardiol.* 2001;37:1478-92.
17. Alberti A, Giudice P, Gelera A, Stefanini L, Priest V, Simmonds M, et al. Understanding the economic impact of intravascular ultrasound (IVUS). *Eur J Health Econ.* 2016;17:185-93.
18. Hong SJ, Kim D, Kim BK, Ahn CM, Kim JS, Ko YG, et al. Acute and one-year clinical outcomes of pre-stenting intravascular ultrasound: a patient-level meta-analysis of randomised clinical trials. *EuroIntervention.* 2021;17:202-11.
19. Zhang J, Gao X, Kan J, Ge Z, Han L, Lu S, et al. Intravascular Ultrasound Versus Angiography-Guided Drug-Eluting Stent Implantation: The ULTIMATE Trial. *J Am Coll Cardiol.* 2018;72:3126-37.
20. Zhang YJ, Pang S, Chen XY, Bourantas CV, Pan DR, Dong SJ, et al. Comparison of intravascular ultrasound guided versus angiography guided drug eluting stent implantation: a systematic review and meta-analysis. *BMC Cardiovasc Disord.* 2015;15:153.
21. Park SM, Kim JS, Ko YG, Choi D, Hong MK, Jang Y, et al. Angiographic and intravascular ultrasound follow up of paclitaxel- and sirolimus-eluting stent after poststent high-pressure balloon dilation: from the poststent optimal stent expansion trial. *Catheter Cardiovasc Interv.* 2011;77: 15-21.
22. de la Torre Hernandez JM, Baz Alonso JA, Gómez Hospital JA, Alfonso Manterola F, Garcia Camarero T, Gimeno de Carlos F, et al. Clinical impact of intravascular ultrasound guidance in drug-eluting stent implantation for unprotected left main coronary disease: pooled analysis at the patient-level of 4 registries. *JACC Cardiovasc Interv.* 2014;7:244-54.
23. Yang RR, Lv YH, Guo C, Li M, Zhang MB, Wang ZL, et al. Intravascular ultrasound-guided percutaneous coronary intervention for patients with coronary bifurcation lesions: A systematic review and meta-analysis. *Medicine (Baltimore).* 2020;99:e20798.
24. Ueki Y, Otsuka T, Hibi K, Räber L. The Value of Intracoronary Imaging and Coronary Physiology When Treating Calcified Lesions. *Interv Cardiol.* 2019;14: 164-8.
25. Okamura A, Iwakura K, Iwamoto M, Nagai H, Sumiyoshi A, Tanaka K, et al. Tip Detection Method Using the New IVUS Facilitates the 3-Dimensional Wiring Technique for CTO Intervention. *JACC Cardiovasc Interv.* 2020;13:74-82.
26. Choi SY, Witztenbichler B, Maehara A, Lansky AJ, Guagliumi G, Brodie B, et al. Intravascular ultrasound findings of early stent thrombosis after primary percutaneous intervention in acute myocardial infarction: A Harmonizing Outcomes with Revascularization and Stents in Acute Myocardial Infarction (HORIZONS-AMI) substudy. *Circ Cardiovasc Interv.* 2011;4:239-47.
27. Hassan AK, Bergheanu SC, Stijnen T, van der Hoeven BL, Snoep JD, Plevier JW, et al. Late stent malapposition risk is higher after drug-eluting stent compared with bare-metal stent implantation and associates with late stent thrombosis. *Eur Heart J.* 2010;31:1172-80.
28. Chowdhury MA, Sheikh MA. Coronary bypass graft perforation during percutaneous intervention. *Cardiovasc Revasc Med.* 2016;17:48-53.
29. Oemrawsingh PV, Mintz GS, Schaliq MJ, Zwinderman AH, Jukema JW, van der Wall EE. Intravascular ultrasound guidance improves angiographic and clinical outcome of stent implantation for long coronary artery stenoses: final results of a randomized comparison with angiographic guidance (TULIP Study). *Circulation.* 2003; 107:62-7.

30. Kim JS, Kang TS, Mintz GS, Park BE, Shin DH, Kim BK, et al. Randomized comparison of clinical outcomes between intravascular ultrasound and angiography-guided drug-eluting stent implantation for long coronary artery stenoses. JACC Cardiovasc Interv. 2013; 6:369-76.
31. Costa MA, Angiolillo DJ, Tannenbaum M, Driesman M, Chu A, Patterson J, et al. Impact of stent deployment procedural factors on long-term effectiveness and safety of sirolimus-eluting stents (final results of the multicenter prospective STLLR trial). Am J Cardiol. 2008;101: 1704-11.

---

© 2022 Salem et al.; This is an Open Access article distributed under the terms of the Creative Commons Attribution License (<http://creativecommons.org/licenses/by/4.0>), which permits unrestricted use, distribution, and reproduction in any medium, provided the original work is properly cited.

*Peer-review history:*

*The peer review history for this paper can be accessed here:*

*<https://www.sdiarticle5.com/review-history/89163>*