



Comparative Evaluation of Antibiotic Therapies for Subclinical Staphylococcal Mastitis in Goats

Manoj Patel ^{a++*}, Devendra Kumar Gupta ^{a#},
Mrinal Singh ^{a++}, Aditya Pratap ^{a†}, Ajay Kumar Rai ^{b‡},
Supnesh Jain ^{a++}, Nitesh Suryavanshi ^{c++},
Ranbir Singh Jatav ^{a^} and Bhoopendra Kumar Mudiya ^{d##}

^a Department of Veterinary Medicine, College of Veterinary Science and A.H., NDVSU, Jabalpur, India.

^b Department of Veterinary Microbiology, College of Veterinary Science and A.H., Arrabari, Kishanganj, Bihar, India.

^c Department of Veterinary Surgery and Radiology, College of Veterinary Science and A.H., NDVSU, Jabalpur, India.

^d Goat Breeding Center, Narsinghpur, Department of Animal Husbandry and Dairying, Govt. of Madhya Pradesh, India.

Authors' contributions

This work was carried out in collaboration among all authors. All authors read and approved the final manuscript.

Article Information

DOI: <https://doi.org/10.9734/jabb/2024/v27i101576>

Open Peer Review History:

This journal follows the Advanced Open Peer Review policy. Identity of the Reviewers, Editor(s) and additional Reviewers, peer review comments, different versions of the manuscript, comments of the editors, etc are available here: <https://www.sdiarticle5.com/review-history/125199>

Original Research Article

Received: 19/08/2024

Accepted: 21/10/2024

Published: 26/10/2024

⁺⁺MVSc;

[#]Professor and Head;

[†]PhD Scholar;

[‡]Associate Professor and Head;

[^]Assistant Professor;

^{##}Veterinary Assistant Surgeon;

^{*}Corresponding author: E-mail: patel1994manoj@gmail.com;

Cite as: Patel, Manoj, Devendra Kumar Gupta, Mrinal Singh, Aditya Pratap, Ajay Kumar Rai, Supnesh Jain, Nitesh Suryavanshi, Ranbir Singh Jatav, and Bhoopendra Kumar Mudiya. 2024. "Comparative Evaluation of Antibiotic Therapies for Subclinical Staphylococcal Mastitis in Goats". *Journal of Advances in Biology & Biotechnology* 27 (10):1542-51. <https://doi.org/10.9734/jabb/2024/v27i101576>.

ABSTRACT

Subclinical mastitis (SCM) is characterized by inflammation of the udder without visible signs of inflammation in the animal, udder and milk and hence could be diagnosed by laboratory examination only. Effective treatment of SCM in goats is crucial for maintaining quality milk production. This study was conducted at the Department of Veterinary Medicine, College of Veterinary Science and Animal Husbandry, Nanaji Deshmukh Veterinary Science University, Jabalpur (M.P.), India. A total of 236 lactating goats irrespective of age, breed, parity and stage of lactation, from both organized and unorganized sectors in and around Jabalpur, were screened over a period of six month. Based on modified California mastitis test scores, 83 goats tested positive for subclinical mastitis resulting in an overall occurrence of 35.17% (83/236). A total of 48 milk samples that tested positive for modified California mastitis test were further analyzed for bacterial isolation and identification. Among them, 34 (70.83%) samples were positive for only *Staphylococcus* spp., while 12 (25%) samples exhibited mixed infection with *Staphylococcus* spp. and Gram-positive bacilli. Then, 18 goats, positive for subclinical Staphylococcal mastitis were divided into three groups i.e. G1, G2 and G3 with six goats in each group for therapeutic study and six apparently healthy goats were taken as healthy control group (G4). G1 Goats were treated with Inj. Enrofloxacin LA @ 7.5 mg/kg b. wt. I/M single dose; G2 with Inj. Ceftizoxime @ 10 mg/kg b. wt. I/V single dose and G3 with Inj. Oxytetracycline LA @ 20 mg/kg b. wt. I/M single dose. The responses of therapeutic assessment were evaluated on the basis of somatic cell count and modified California mastitis test score. The most effective response for subclinical Staphylococcal mastitis in goats was observed with Ceftizoxime followed by Enrofloxacin LA and the least with Oxytetracycline LA.

Keywords: Subclinical mastitis; MCMT; SCC; Goats; *Staphylococcus* spp.

1. INTRODUCTION

Mastitis is the inflammation of mammary gland parenchyma, characterized by alterations in both the physical and chemical composition of milk, usually involving the presence of bacteria, accompanied by pathological alterations in the glandular tissues [1]. Subclinical mastitis is characterized by the absence of visible clinical symptoms, with the only indicators being an elevated somatic cell count, the presence of pathogenic organisms in the milk and an inflammatory response that can only be detected through screening or laboratory tests. It is a major infectious disease in small ruminants and poses a continuous risk to the entire herd. With increasing demands for higher milk production and stricter standards for quality goat milk, it is crucial to identify and prevent udder infections at an early stage, not only for the benefit of the farmer but also to ensure consumer safety [2].

In dairy goats affected by subclinical mastitis (SCM), Coagulase-negative *Staphylococcus* (CNS) species are the major threat and constitute between 44.7% and to 95.9% of the isolated pathogens from milk samples in dairy goats affected by subclinical mastitis (SCM). In contrast, *Staphylococcus aureus*, which is typically regarded as more pathogenic, accounts

just for 4.1% to 18.0% of the SCM cases in goats [3].

The treatment of subclinical mastitis (SCM) is crucial for maintaining milk production and various trials researches have been conducted using different antibacterial drugs to address mastitis in goats. Cephalosporins antibiotics are favored due to their low toxicity and broad-spectrum antibacterial antibiotic activity against wider ranges of bacteria (both gram-positive and gram-negative) due to their low toxicity. Third-generation cephalosporins such as ceftizoxime, long-acting fluoroquinolones like marbofloxacin and tetracyclines are commonly recommended for treating SCM in goats [4]. Additionally, certain treatments including a combination of vitamin E and selenium, organic selenium and enrofloxacin, have been proven to be effective and beneficial for managing SCM in goats [5].

Additionally, one of the most significant challenges in treating and controlling subclinical mastitis (SCM) is the rise of drug resistance, which is often caused by the indiscriminate use of antibacterial agents. This study addresses the therapeutic management of subclinical Staphylococcal mastitis in goats in and around the Jabalpur region of Madhya Pradesh.

2. MATERIALS AND METHODS

2.1 Location and Place of Work

This study was conducted over six months at Department of Veterinary Medicine, College of Veterinary Science and Animal Husbandry, Nanaji Deshmukh Veterinary Science University (N.D.V.S.U), Jabalpur, Madhya Pradesh (M.P.). Located at 23.17° latitude and 79.57° East longitude, Jabalpur is 410.87 mean sea level in southern part of the second agro-climatic zone, which includes Satpura Plateau and Kaymore Hills. A tropical climate prevails here with an average annual rainfall of 1241 millimeters.

2.2 Screening

A total of 236 female goats were screened for this study from different organized and

unorganized sectors in and around Jabalpur region. Goats were screened based on their history, presence of clinical symptoms and Modified California Mastitis Test (MCMT). Complete history of the case including age, breed, parity and stage of lactation, was recorded.

2.3 Modified California Mastitis Test (MCMT)

An equal volume of milk (5 ml) and MCMT reagent (5 ml) was added to a plastic paddle and gently swirled in a horizontal motion with minimal agitation. The score was recorded after 10 seconds, while continuing to rotate the paddle. The reaction was graded by intensity of gel formation and colour change as follows [6]: (Table 1 and Fig. 1).

Table 1. Grading of milk by modified california mastitis test

MCMT grade	Description
Negative	No change
Trace	Slime formation which disappeared with continuous movement of paddle
1+	Distinct slime but no gel formation
2+	Viscous with gel formation which adherent to the margin of the cup
3+	The gel formation with convex projection, the gel did not dislodge after swirling movement of the paddle

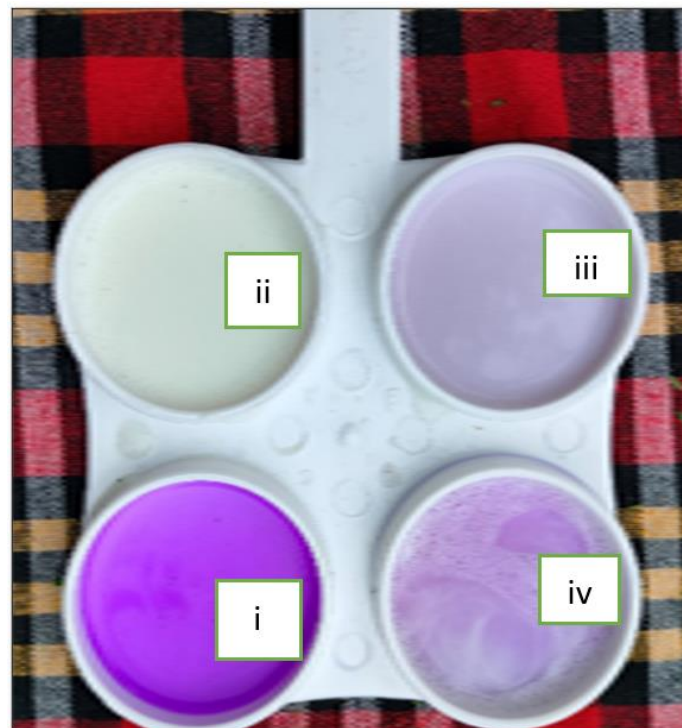


Fig. 1. Pictorial representation of MCMT test ((i) Only reagent (ii) Only milk (iii) Negative sample (iv) Positive sample

2.4 Sample Collection

To collect milk, udder of each goat was thoroughly washed with a 0.01% solution of potassium permanganate and wiped with clean cloth before collection of milk. Approximately 10 ml of mid-stream milk was collected aseptically from each half of the udder in sterilized vials and transported (in ice) for further examination.

2.5 Processing of Sample

2.5.1 Somatic Cell Count (SCC)

The somatic cell count was measured in milk samples on day '0' (pre-treatment) and on day '7' (post-treatment) for all the goats in different treatment groups. The SCC was counted with the help of somatic cell counter cum lactoscan (combo).

Procedure:

1. Milk sample was homogenized on vortex mixture for one minute.
2. 20µl homogenized sample was taken with the help of micropipette in eppendorf tube and again homogenized for half a minute
3. Then 0.8µl milk sample was taken from the Eppendorf tube and was loaded on to the cartridge.
4. Excess of milk was removed by cotton
5. Cartridge was then inserted into the cartridge slot of lactoscan machine and press to continue button
6. Result was displayed on the screen

2.5.2 Isolation and identification of *Staphylococcus* spp.

Pre Enrichment Using Muller Hinton Broth with 6.5 % Sodium Chloride: The culture media preparation and pre-enrichment of *Staphylococcus* spp. was done as per the procedure described by Markey et al. [7]. For pre-enrichment of *Staphylococcus* spp. milk samples were inoculated on Muller Hinton broth with 6.5 % sodium chloride and incubated at 37°C for 24 hours.

Inoculation of enriched sample on Mannitol Salt Agar:

Pre enriched samples were cultured to isolate the *Staphylococcus* spp. on mannitol salt agar. These isolates were incubated aerobically at 37°C for 24 hours. The yellow or pink colony on mannitol salt agar indicated the presence of *Staphylococcus* spp. [7].

Gram's Staining: Clean slide was prepared then a loopful of water was placed in the center of the slide. With the inoculating needle, very small amount of culture was picked up aseptically and mixed into the drop of water and was spread to 1/2-inch area. Slide was air dried and passed through a Bunsen burner flame three times to heat-fixed and to kill the bacteria. The heat fixed smear was placed on a staining receptacle and slide was covered with crystal violet solution for one minute and then washed off briefly with tap water and drained. The smear was then treated with few drops of Gram's Iodine and allowed to act for a minute. The slide was again washed in water and then decolorized in absolute ethyl alcohol. After the smear is decolorized, it was washed in water without any delay. The smear was finally treated with few drops of counter stain safranin and washed off with tap water. Excess water was removed using a blotting paper, dried in air and examined microscopically under the oil immersion lens. Gram positive cocci (violet color) arranged in grape-like clusters were observed [7].

2.6 Therapeutic Regimen

A total of 18 goats, positive for subclinical Staphylococcal mastitis was divided into three groups G1, G2 and G3 comprised of six goats in each group. Moreover, six apparently healthy goats, were taken as healthy control group (G4). The following therapeutic regimen was followed (Table 2).

2.7 Statistical Analysis

The alterations in different treatment groups at different intervals were analyzed using one-way ANOVA in R software using dplyr package and means were compared using post Hoc - Duncan's multiple range tests as per the standard procedure [8].

Table 2. Therapeutic regimen adopted against subclinical Staphylococcal mastitis in goats

Groups	No. of goats	Drug dosage
G1	06	Inj- Enrofloxacin LA @ 7.5 mg/kg b. wt. I/M single dose
G2	06	Inj- Ceftizoxime @ 10 mg/kg b. wt. I/V single dose
G3	06	Inj-Oxytetracycline LA @ 20 mg/kg b.wt. I/M single dose
G4	06	Healthy control

3. RESULTS AND DISCUSSION

3.1 Somatic Cell Count

Somatic cell counts were recorded on day 0 (pre-treatment) and day 7 (post treatment) in all the 18 female lactating goats under therapeutic and compared with the healthy control goats.

The findings revealed that mean SCC on day 0 before treatment in goats of groups G1, G2 and G3 were $14.63 \pm 0.80 \times 10^5$ cells/ml, $15.34 \pm 0.63 \times 10^5$ cells/ml and $14.10 \pm 0.89 \times 10^5$ cells/ml, respectively. After treatment, the mean SCC on day 7 in goats of groups G1, G2 and G3 were $11.57 \pm 1.52 \times 10^5$ cells/ml, $10.02 \pm 2.63 \times 10^5$ cells/ml and $12.42 \pm 1.72 \times 10^5$ cells/ml, respectively.

Significantly higher SCC was observed in goats having SCM on day 0 pre-treatment as compared to healthy control group. A significant reduction in the SCC of goats was observed maximum in group G2 and G1 on day 7 of post treatment. The details are summarized in Table 3.

The mean values of SCC recorded in Group I, Group II and Group III showed a significant difference ($P \leq 0.05$) when compared to apparently healthy goats. Similar findings were reported by Robertson and Muller [9], Min et al. [10], Koop et al. [11], Persoon and Olofsson [12] and Singh et al. [13] who observed an increase in SCC in the milk of goats affected by SCM.

These changes indicate a higher SCC in the milk of goats with subclinical mastitis. The most significant abnormality observed is the elevated SCC, which is higher in goats than in cows due to apocrine secretion [9]. Somatic cells primarily consist of milk-secreting epithelial cells shed from the mammary gland lining, along with white blood cells that enter the gland in response to injury or infection [14]. Given the direct correlation between inflammatory cells and intramammary infection, SCC is the most

commonly used indicator for monitoring udder health [15]. Typically, somatic cells in milk comprise about 75% leukocytes and 25% epithelial cells. An elevated leukocyte count is a response to bacterial infection, tissue injury, stress and an increase in SCC indicates a decline in the quality of raw milk [14].

3.2 Bacterial Isolation and Identification of *Staphylococcus* spp.

A total of 48 milk samples tested positive on MCMT in lactating goats. Out of them, 34 (70.83%) samples were positive for only *Staphylococcus* spp., while 25 % were harboring mixed infection (*Staphylococcus* spp. and Gram-positive bacilli) based on the distinctive colour on mannitol salt agar (yellow or pink colour colony) and colony morphology (Gram positive cocci arranged in grape-like clusters). The details are summarized in Table 4, Figs. 2 and 3.

These findings are closely similar with Najeeb et al. [16] and Omar and Mat-Kamir [17] who reported that *Staphylococcus* spp. isolated from SCM milk samples were 61.64 per cent and 73.2 per cent, respectively.

Staphylococcus bacteria are commonly found inside the teat canal, on udder skin and within mammary glands and are often transmitted through improper and unhygienic milking practices [18]. This can be due to increased risk of infection over time and the prolonged duration of infections, particularly in herds lacking a mastitis control program [19].

3.3 Therapeutic Response Study

For the response of therapy in different treatment groups was evaluated on the basis of somatic cell count and modified California mastitis test. However, for the therapeutic study goats with sub clinical mastitis in early lactation stage was targeted in all the treatment groups. The details are summarized in Table 5.

Table 3. Somatic cell count (Mean±SE) in goats in different treatment groups at different intervals

Groups (n=6)	SCC (10^5 cells/ml)	
	Day '0'	Day '7'
G1	$14.63^{aA} \pm 0.80$	$11.57^{abB} \pm 1.52$
G2	$15.34^{aA} \pm 0.63$	$10.02^{abB} \pm 2.63$
G3	$14.10^{aA} \pm 0.89$	$12.42^{aA} \pm 1.72$
G4	$04.35^b \pm 0.16$	$05.28^b \pm 0.15$

Mean values with different superscripts between group (lowercase) and between days (uppercase) differ significantly ($p < 0.05$)

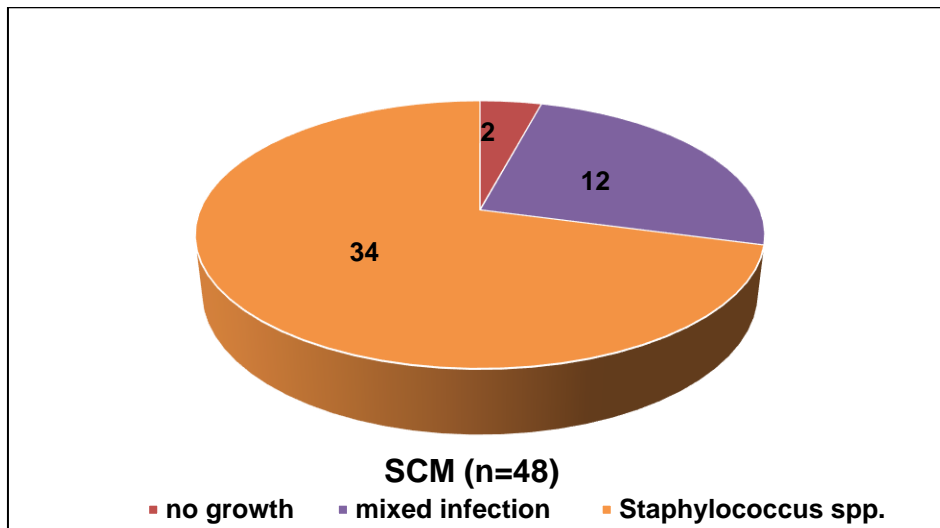


Fig. 2. Distribution of bacterial growth on Mannitol Salt agar

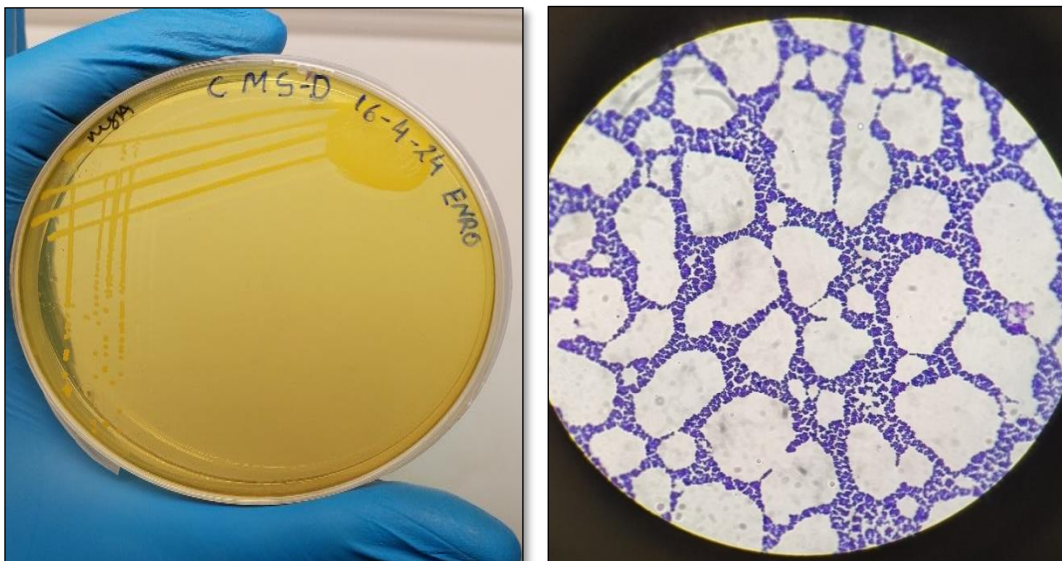


Fig. 3. (a) Yellow colored colonies of *Staphylococcus* on Mannitol salt agar (b) Smear from pure colony showing Gram positive cocci in branches (100x)

3.3.1 Group G1 (Enrofloxacin LA)

Out of the 6 goats, two exhibited a significant reduction in SCC i.e., from 15.6×10^5 to 07.4×10^5 and from 11.99×10^5 to 6.99×10^5 cells/ml. The similar goats showed MCMT score from +3 to +1 and +2 to +1 on day 7 (post treatment). However, in remaining 4 goats no significant difference was observed in terms of SCC and MCMT, on day 7 (post treatment).

The antibiotic used in the therapy of group G₁ suffered with subclinical Staphylococcal mastitis treated with Enrofloxacin LA @ 7.5 mg/kg b.wt. intramuscular single dose was also effective to

treat SCM during lactation period, which agrees with the observation made by Owens et al. [20] and Halmandge et al. [5], suggesting that Enrofloxacin may serve as an effective antibacterial agent for treating SCM in goats. Marin et al. [21] reported that enrofloxacin exhibited high in vitro sensitivity against isolates of caprine mastitis, further supporting its potential as a treatment option for SCM in goats. The mechanism of action of fluoroquinolones involves inhibiting DNA gyrase, which in turn inhibits bacterial cell division. In both beta-lactams and fluoroquinolones, the inhibition of bacterial replication is crucial to the development of persistence [22].

Table 4. Isolation and identification of *Staphylococcus* spp. in milk samples found positive for SCM

Total number of milk sample examined positive for SCM	Growth on Muller Hinton broth + 6.5% NaCl	Growth on Mannitol salt agar	Gram's Staining	Mixed infection (<i>Staphylococcus</i> spp.+ gram positive Bacilli)	Only <i>Staphylococcus</i> spp.
48	48	46	46	12 (25%)	34 (70.83%)

Table 5. Evaluation of therapeutic response in different treatment groups in subclinical Staphylococcal mastitis in goats

Groups	No. of goats	SCC ($\times 10^5$ cells/ml)		MCMT grade		Ranking
		Day '0'	Day '7'	Day '0'	Day '7'	
G1 (Enro. LA)	1	15.60	07.40	3	1	II
	2	16.00	15.90	3	3	
	3	12.20	11.98	2	2	
	4	11.99	06.99	2	1	
	5	15.80	12.20	3	2	
	6	16.20	15.00	3	3	
	Mean\pmSE		14.63 \pm 0.80 ^{aA}	11.57 \pm 1.52 ^{abB}		
G2 (Ceftizoxime)	1	12.20	04.11	2	Negative	I
	2	16.11	03.99	3	Negative	
	3	15.90	04.30	3	Negative	
	4	15.77	15.71	3	3	
	5	16.10	16.13	3	3	
	6	15.98	15.89	3	3	
	Mean\pmSE		15.34 \pm 0.63 ^{aA}	10.02 \pm 2.63 ^{abB}		
G3 (OTC LA)	1	11.99	12.00	2	2	III
	2	16.14	15.88	3	3	
	3	16.20	16.00	3	3	
	4	15.98	15.92	3	3	
	5	12.11	07.49	2	1	
	6	12.22	07.22	2	1	
	Mean\pmSE		14.10 \pm 0.89 ^{aA}	12.42 \pm 1.72 ^{aA}		

Mean values with different superscripts between group (lowercase) and between days (uppercase) differ significantly ($p < 0.05$)

3.3.2 Group G2 (Ceftizoxime)

5 out of 6 goats exhibited SCC of approximately 16×10^5 cells/ml in the milk samples, while the remaining goat had an SCC of approximately 12×10^5 cells/ml. Additionally, 5 of the 6 goats demonstrated a +3 grade on the MCMT, whereas single goat showed a +2 MCMT grade on day 0 (pre-treatment). However, 3 out of 6 goats exhibited SCC of approximately 16×10^5 cells/ml, while the other 3 goats had an SCC of approximately 4×10^5 cells/ml. Furthermore, 3 goats continued to show a +3 grade, while the remaining 3 goats tested negative for the MCMT on day 7 (post-treatment).

The antibiotic used in the therapy of group G₂ suffered with subclinical Staphylococcal mastitis treated with Ceftizoxime @10 mg /kg b.wt. intravenous single dose, potentially effective to get better recovery. The therapeutic effectiveness of ceftizoxime against the Staphylococcal mastitis is also noticed by Buragohain et al. [23]. In mastitis, the prolonged persistence of ceftizoxime in milk has been corroborated by the findings of Sar et al. [24], Karmakar et al. [4] and Kumar et al. [25]. Ceftizoxime is an amphoteric drug that exhibits increased persistence due to the shift towards alkaline pH in mammary secretions during mastitis, which promotes ion trapping. The concentration and pharmacokinetic parameters of ceftizoxime in milk suggest that it has a favorable antibacterial effect in cases of acute staphylococcal mastitis. Consequently, a single intravenous dose of ceftizoxime might be an effective treatment for the *S. aureus*. causing acute mastitis.

3.3.3 Group G3 (Oxytetracycline LA)

3 out of 6 goats exhibited SCC of approximately 16×10^5 cells/ml in the milk samples, while the remaining 3 goats had an SCC of approximately 12×10^5 cells/ml. Additionally, 3 of the 6 goats demonstrated a +3 grade, whereas remaining 3 goats showed a +2 grade on the MCMT, on day 0 (pre-treatment). However, 3 out of 6 goats continued to exhibit SCC of approximately 16×10^5 cells/ml, Of the remaining goats, 2 had an SCC of approximately 7.5×10^5 cells/ml and one had SCC of approximately 12×10^5 cells/ml. Furthermore, 3 goats showed a +3 grade, while 2 goats showed +1 grade and a remaining goat represented +2 grade on the MCMT on day 7 (post-treatment).

The antibiotic used to treat the group G₃ with Oxytetracycline LA @ 20 mg /kg b.wt intramuscular single dose was not well efficient to treat the subclinical Staphylococcal mastitis. This finding was closely related with the observation of Kirkan et al. [26]. This issue may stem from the misuse of antibiotics, as frequent use of the same antibiotics can lead to antibiotic resistance. Additionally, the bacteria may resist treatment because they can exist intracellularly, in L-forms, or within micro abscesses in the udder [27]. Virdis et al. [3] also reported that *Staphylococcus aureus* shows high resistance to doxycycline (28.0%), oxytetracycline (16.0%) and ampicillin (12.0%).

4. CONCLUSION

The most effective therapeutic response for subclinical Staphylococcal mastitis in goats was produced by Ceftizoxime followed by Enrofloxacin LA and the least with Oxytetracycline LA. Interestingly, the overall milk production of goat were observed to increase during the study period, reflecting the effective treatment regimen enhancing the udder health and the milk quality. Moreover, the incidence of newborn kid mortality too witnessed a significant decline (though data is not covered), further favoring the effective subclinical mastitis management. Hence, preventing or detecting udder infections at an early stage is essential, not only to increase the milk production and safeguard the farmer but also to ensure consumer safety.

5. FUTURE SCOPE

Thus, the current research offers pertinent data on the therapeutic management of subclinical Staphylococcal mastitis in goats in and around Jabalpur (M.P.). Detection of other *Staphylococcus* spp. responsible for subclinical mastitis in goats may be studied and alternative therapeutic strategies should be required to treat the cases of subclinical mastitis in terms to minimize drug residues in milk. Control programs aimed at improving the udder health of goats are needed and focus should be on educating farmers on which breed should be selected for better udder and teat traits.

DISCLAIMER (ARTIFICIAL INTELLIGENCE)

Author(s) hereby declares that NO generative AI technologies such as Large Language Models (ChatGPT, COPILOT, etc.) and text-to-image

generators have been used during the writing or editing of this manuscript.

ACKNOWLEDGEMENT

It is with great gratitude that the authors acknowledge the Dean, College of Veterinary Sciences and Animal Husbandry, NDVSU, Jabalpur for providing the necessary facilities for carrying out the study.

COMPETING INTERESTS

Authors have declared that no competing interests exist.

REFERENCES

1. Danmallam FA, Pimenov NV. Species composition of microflora isolated from the mammary gland of a healthy and sick mastitis goat. *Vet Zootekhniya*. 2017;4:6-12.
2. Bhanot V, Mehla OP, Kumar R. Prevalence of mastitis in goats. *J Krishi Vigyan*. 2017;6(1):232-3.
3. Virdis S, Scarano C, Cossu F, Spanu V, Spanu C, De Santis EPL. Antibiotic resistance in *Staphylococcus aureus* and coagulase negative staphylococci isolated from goats with subclinical mastitis. *Vet Med Int*. 2010;2010:517060.
4. Karmakar U, Datta BK, Patra PH, Prashant M, Suman S, Sar TK, Mandal TK. Disposition kinetics of ceftizoxime in healthy and mastitic goats after intravenous administration. *Pharmacol Online*. 2011;3(1):935-46.
5. Halmandge SC, Upendra HA, Kasaralika VR, Ramesh PT. Comparative therapeutic efficacy of subclinical mastitis in goats. *Indian J Vet Med*. 2021;41(2):34-7.
6. Radostits OM, Gay CC, Hinchcliff KM, Constable PD. Diseases of mammary glands. In: *Veterinary medicine: A textbook of the diseases of cattle, sheep, goat, pig and horses*. 10th ed. London: Saunders Elsevier. 2010;673-762.
7. Markey B, Leonard F, Archambault M, Cullinane A, Maguire D. *Clinical veterinary microbiology*. 2nd ed. London: Elsevier Publishing Co. 2012;118-344.
8. R Core Team. R: A language and environment for statistical computing. Vienna: R Foundation for Statistical Computing; 2013. Available:<http://www.R-project.org/>
9. Robertson NH, Muller CJC. Somatic cell count in goat's milk as an indication of mastitis. *Anim Sci*. 2005;6(1):1-6.
10. Min BR, Tomita G, Hart SP. Effect of subclinical intramammary infection on somatic cell counts and chemical composition of goat's milk. *J Dairy Res*. 2007;74(2):204-10.
11. Koop G, van Werven T, Toft N, Nielsen M. Estimating test characteristics of somatic cell count to detect *Staphylococcus aureus* infected dairy goats using latent class analysis. *J Dairy Sci*. 2011;94(6):2902-11.
12. Persson Y, Olofsson I. Direct and indirect measurement of somatic cell count as indicator of intramammary infection in dairy goats. *Acta Vet Scand*. 2011;53(15):1-5.
13. Singh B, Shukla PC, Gupta DK, Tiwari A, Mourya A. Occurrence and diagnostic aspects of subclinical mastitis in goats in and around Jabalpur region. *J Entomol Zool Stud*. 2019;7(5):289-95.
14. Sharma NK, Singh NK, Bhadwal MS. Relationship of somatic cell count and mastitis: an overview. *Asian-Australas J Anim Sci*. 2011;24(3):429-38.
15. Kaskous S, Farschtschi S, Pfaffl MW. Physiological aspects of milk somatic cell count in small ruminants - a review. *Dairy*. 2022;4(1):26-42.
16. Najeeb MF, Anjum AA, Ahmad MUD, Khan HM, Ali MA, Sattar MMK. Bacterial etiology of subclinical mastitis in dairy goats and multiple drug resistance of the isolates. *J Anim Plant Sci*. 2013;23(6):1541-4.
17. Omar S, Mat-Kamir NF. Isolation and identification of common bacteria causing subclinical mastitis in dairy goats. *Int Food Res J*. 2018;25(4):1668-74.
18. Manser PA. Prevalence, causes and laboratory diagnosis of subclinical mastitis in the goat. *Vet Rec*. 1986;118(20):552-4.
19. Gebrewahid TT, Abera BH, Menghistu HT. Prevalence and etiology of subclinical mastitis in small ruminants of Tigray regional state, north Ethiopia. *Vet World*. 2012;5(2):103-9.
20. Owens WE, Ray CH, Watts JL, Yancey RJ. Comparison of success of antibiotic therapy during lactation and results of antimicrobial susceptibility tests for bovine mastitis. *J Dairy Sci*. 1997;80(2):313-7.
21. Marin P, Escudero E, Fernandez-Varon E, Carceles CM, Corrales JC, Gomez-Martin A, Martinez I. Fluoroquinolone susceptibility of *Staphylococcus aureus* strains isolated from caprine clinical

- mastitis in southeast Spain. J Dairy Sci. 2010;93(11):5243-5.
22. Brauner A, Fridman O, Gefen O, Balaban NQ. Distinguishing between resistance, tolerance and persistence to antibiotic treatment. Nat Rev Microbiol. 2016;14(5):320-30.
 23. Buragohain R, Sar TK, Samanta I, Biswas U, Mandal TK. Disposition of ceftizoxime in Staphylococcal mastitis in Indian crossbred cows. Vet J. 2019;245:12-4.
 24. Sar TK, Mandal TK, Samanta I, Rahaman A, Chakraborty AK. Determination of ceftriaxone in plasma and ceftizoxime in milk of mastitic cows following single dose intravenous administration. Indian J Anim Sci. 2010;80(12):1182.
 25. Kumar R, Sar TK, Patra PH, Samanta I, Mishra A, Mandal TK. Disposition kinetics of ceftizoxime in acute mastitis in Murrah buffaloes. Indian J Anim Sci. 2016;86(2):140-2.
 26. Kirkan S, Erbas G, Savasan S, Ucan N, Gurpinar S, Ozavci V. Detection of antimicrobial resistance in *Staphylococcus aureus* isolated from Saanen goats with subclinical mastitis. Anim Health Prod Hyg. 2014;3(1):284-7.
 27. Sears PM, Fetting M, Marsh-Salin J. Isolation of L-form variants after antibiotic treatment in *Staphylococcus aureus* bovine mastitis. J Am Vet Med Assoc. 1987;191(6):681-4.

Disclaimer/Publisher's Note: The statements, opinions and data contained in all publications are solely those of the individual author(s) and contributor(s) and not of the publisher and/or the editor(s). This publisher and/or the editor(s) disclaim responsibility for any injury to people or property resulting from any ideas, methods, instructions or products referred to in the content.

© Copyright (2024): Author(s). The licensee is the journal publisher. This is an Open Access article distributed under the terms of the Creative Commons Attribution License (<http://creativecommons.org/licenses/by/4.0>), which permits unrestricted use, distribution, and reproduction in any medium, provided the original work is properly cited.

Peer-review history:
The peer review history for this paper can be accessed here:
<https://www.sdiarticle5.com/review-history/125199>