

When the Stars Align: Hypertriglyceridemic Pancreatitis Is Inevitable

Kamel El-Reshaid^{1*}, Abass Hakim², Reji Philip Athyal³

¹Department of Medicine, Faculty of Medicine, Kuwait University, Kuwait, Kuwait

²Department of Nephrology, Amiri Hospital, Ministry of Health, Kuwait, Kuwait

³Department of Radiology, Amiri Hospital, Ministry of Health, Kuwait, Kuwait

Email: *kamel@hsc.edu.kw

How to cite this paper: El-Reshaid, K., Hakim, A. and Athyal, R.P. (2024) When the Stars Align: Hypertriglyceridemic Pancreatitis Is Inevitable. *International Journal of Clinical Medicine*, 15, 233-239.
<https://doi.org/10.4236/ijcm.2024.157017>

Received: June 15, 2024

Accepted: July 16, 2024

Published: July 19, 2024

Copyright © 2024 by author(s) and Scientific Research Publishing Inc. This work is licensed under the Creative Commons Attribution International License (CC BY 4.0).

<http://creativecommons.org/licenses/by/4.0/>



Open Access

Abstract

Background: Acute pancreatitis (AP) is an inflammatory process affecting the pancreas. Hypertriglyceridemic AP (HTAP) is its third leading cause after gallstones followed by alcohol use. It develops when stars align viz. triggers (acquired surges) in patients with genetic hypertriglyceridemia. **Case:** severe and acute pancreatitis had developed in a 57-year-old man with type IIb familial hyperlipidemia after heavy fatty meals. The acute phase was controlled by holding oral intake with weekly Evolocumab therapy and long-term prevention by weight reduction and Fenofibrate alone. His pancreatic endocrine and exocrine functions remained normal after 2 years of follow-up. **Conclusion:** Those four measures were safe, practical and effective for short- and long-term management of HTAP.

Keywords

Fenofibrate, Genetic Hypertriglyceridemia, Hyperlipidemia, Pancreatitis, Triggers, Weight Reduction

1. Introduction

Acute pancreatitis (AP) is an inflammatory process affecting the pancreas. It is characterized by severe epigastric pain, 3X upper limit of normal increase serum amylase and lipase, and radiological evidence of pancreatic oedema or necrosis [1]. In 2019, its global age-standardized incidence rate was 34.8/100,000 [2]. The mortality of acute pancreas ranges from 3% in patients with mild edematous pancreatitis to as high as 20% in patients with pancreatic necrosis [3]. The most common causes of acute pancreatitis are gallstones (20% - 70%) followed by al-








cohol use (30%) [4]. Other notable causes are metabolic (hypercalcemia, hypertriglyceridemia), drug-induced, autoimmune, post-endoscopic retrograde cholangiopancreatography, trauma, infectious, congenital or genetic, and idiopathic. The rate of occurrence of each etiology of acute pancreatitis varies across geographic regions and socioeconomic strata [4]. Hypertriglyceridemic acute pancreatitis (HTAP) accounts for 9% of AP and is the second etiology of AP in Chinese women after cholelithiasis [5]. High-index of suspicion is indicated in early diagnosis and skilled management (treatment and prevention) is essential in prevention of long-term sequelae. In this case report, we present a late presentation of HTAP in an adult patient and outline a non-invasive new innovation in its management and disease prevention.

2. The Case

A 57-year-old man presented with recurrent epigastric pain for months that was worse a few days prior to admission. The pain was dull ache in character, lasted for hours, radiated to the back and worse on lying down. It was associated with nausea and vomiting that did not relieve the pain. Attacks mostly develop after fatty meals. The patient did not have a past history of other significant medical illness, surgery, allergy, or chronic intake of medications or alcohol. Family history was significant for hyperlipidemia. On his initial physical examination, he was drowsy, exhausted and in distress of epigastric pain that had required narcotics to relieve. His body weight was 116 kg, blood pressure was 90/50 mm Hg and was afebrile. Systemic examination did not show abnormality except for severe epigastric tenderness. Abnormal clinical data and laboratory investigations are summarized in **Table 1**. He had normal peripheral leucocytic and platelet counts. Hemoglobin was normal. Serum sugar, electrolytes and liver functions were normal. Serum urea and creatinine were elevated at 14 mmol/L and 240 umol/L, respectively. He had metabolic acidosis with high lactate levels. Serum amylase and lipase were elevated at 776 IU/L (N: 26 - 100) and 1691 IU/L (N: 13 - 60), respectively. Lipid profile showed high serum cholesterol at 9 mmol/L (N: < 5.2), LDL-cholesterol at 7 mmol/L (N: < 3), VLDL at 7 mmol/L (N: < 0.78), and triglycerides at 18 mmol/L (N: < 1.7). Lipoprotein electrophoresis showed absent chylomicrons, 21% alpha lipoproteins (HDL), 21% pre-beta lipoproteins ((VLDL) and 58% beta lipoproteins (LDL). Urine routine and microscopy were normal. Abdominal and pelvic ultrasound showed enlarged and edematous pancreas. Computerized tomography of abdomen revealed bulky pancreatic head and uncinate process with hazy outline, fat stranding with peripancreatic and pelvic free fluid and multiple subcentrimetric regional lymph nodes (**Figure 1**). It showed normal enhancement without pseudocyst formation or tumors. Grading of such pancreatitis (modified severity index) was at 4. Hence, diagnosis of hyperlipidemic pancreatitis was established which was associated with severe intravascular volume compromise due to external fluid loss and translocation of fluid into pancreatic bed. He was treated with saline and bicarbonate infusions

to restore intravascular volume as well as intravenous proton pump inhibitors. In the first few days, he was kept without oral feed and received Evolocumab 140 mg subcutaneously every week. The patient improved, clinically, within 3 days, and low fat diet was started with Simvastatin 40 mg daily as well as fenofibrate 145 mg daily (Table 1). By 2 weeks his clinical as well as his laboratory abnormalities had normalized and hence Evolocumab was held. He was instructed to avoid fatty meals, comply with statin and fibrate therapy and reduce his weight. After 2 years of follow-up the patient: a) remained stable without recurrence of clinical pancreatitis or high amylase/lipase, b) lipid profile remained normal, c) did not have malabsorption features with normal hemoglobin A1c, d) was able to reduce his weight to 87 kg, and e) had normal pancreatic architectures by repeat CT of abdomen (Figure 2).

Table 1. Flow chart of historic demographical data and biochemical changes after treatment of patient with hyperlipidemic pancreatitis.

Day	1	2	7	14	2 years later
Clinical data:					
Blood pressure (120-80 mm Hg)	90/60	110/70	120/80	120	120
Urine output (> 1500 ml/day)	< 100	600	1500	2000	2000
Body weight Kg	116	117	119	119	87
Laboratory tests*:					
Serum urea (4-6 mmol/L)	14	8	6	4	3
Serum creatinine (60-120 umol/L)	240	180	120	80	85
pH (7.4)	7.3	7.4	7.4	7.4	7.4
Serum bicarbonate (22-32 mmol/L)	18	20	24	25	24
Serum lactate (< 2 mmol/L)	4	2	1	1	1
Serum cholesterol (3-5.2 mmol/L)	9	8	7	3	3
Serum LDL-C (< 3 mmol/L)	7	5	4	1	1.5
Serum HDL-C (> 1.55 mmol/L)	0.5	0.6	0.6	0.6	0.8
Serum VLDL (< 0.78 mmol/L)	7	4	1.5	1.2	1.2
Triglycerides: (0.4-1.7 mmol/L)	18	9	4	2	2
Serum amylase (26-100 IU/L)	776	326	147	82	68
Serum lipase (13-60 IU/L)	1691	570	220	52	40
Therapy:					
IV saline					
IV bicarbonate					
Evolocumab 140 mg					
Simvastatin 40 mg/day					
Fenofibrate 145 mg/day					

Abbreviations: LDL-C: low density lipoprotein cholesterol, HDL: high density lipoprotein cholesterol, VLDL: very low density lipoproteins

* No significant changes in serum glucose, electrolytes, albumin, aminotransaminases, GGT, and hemoglobin.

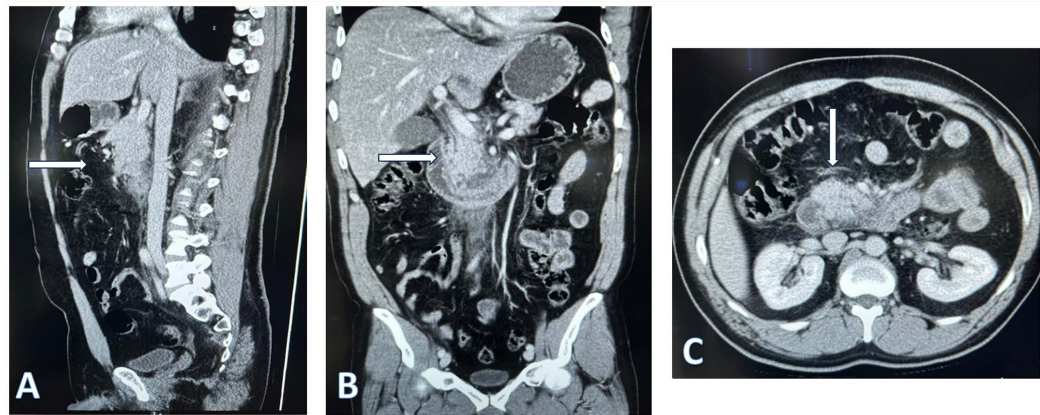


Figure 1. Coronal (A), sagittal (B) and transverse (C) views of a computerized tomography of abdomen revealed bulky pancreatic head and uncinus process (arrows) with hazy outline, fat stranding with peripancreatic and pelvic free fluid and multiple subcentimetric regional lymph nodes.

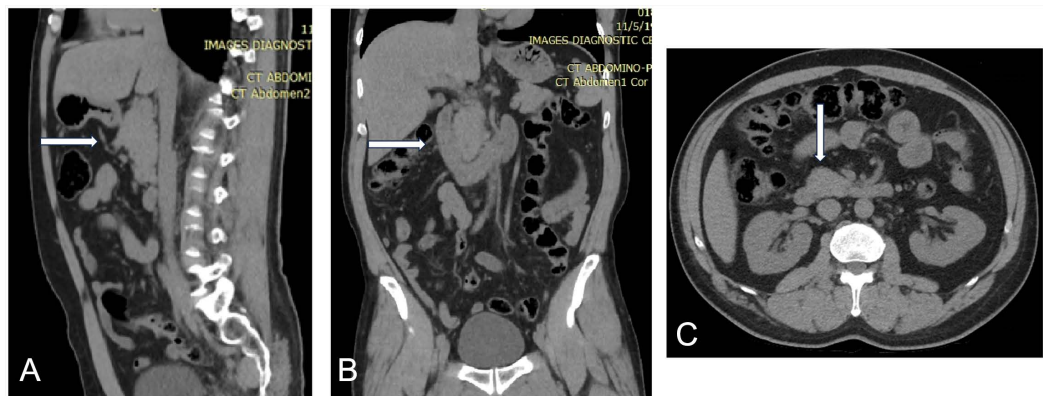


Figure 2. Coronal (A), sagittal (B) and transverse (C) views of computerized tomography of abdomen, 2 years after hyperlipidemic pancreatitis, showing normal pancreatic architectures (arrows).

3. Discussion

HTAP is a “two-hit phenomenon”. It develops when stars align viz. genetic hypertriglyceridemia and triggers (acquired surges). Our patient had severe type IIb genetic disorder (familial combined hyperlipidemia) according to Fredrickson’s classification of hyperlipidemia since, a) did not have hyperchylomicronemia (type I), b) isolated hypercholesterolemia (type IIa) or hypertriglyceridemia (type IV), c) presented at an adult age and lacked growth retardation, malabsorption, neurological and neuromuscular manifestations (type III), d) lacked eruptive xanthomata and hepatomegaly (type V) [6]. Type IIb is a common hyperlipidemic disorder with a prevalence of 1 in 40 and with an autosomal dominant inheritance as in our patient with a strong family history of hyperlipidemia [7]. In general, the list of triggers of HTAP includes uncontrolled diabetes mellitus, morbid obesity, therapeutic keto-genic or high-carbohydrate diets, hypothyroidism, cigarette smoking, alcohol consumption, pregnancy, obstructive liver diseases, renal diseases, drugs (anabolic steroids, corticosteroids, bile acid-binding resins, anticonvulsants, oral contraceptives, anti-retroviral therapy,

Isotretinoin and Depo-Provera), autoimmune diseases, and solid-organ transplants [8]. In our patient, the most plausible trigger was his fatty meals. Omitting fatty meals and weight reduction were cornerstones in his long-term disease prevention. In HTAP, a sudden rise of HTG, due to secondary cause/s, triggers the disorder. Such phenomenon should not be confused with the mild to moderate hyperlipidemia (4% - 20%) associated with other AP [9]. HTAP is increased in patients with plasma triglyceride (TG) levels > 1000 mg/dl (11.3 mmol/l) compared with patients with plasma TG levels ≤ 1000 mg/dl. Excess TGs are hydrolyzed by lipase enzymes excreted by pancreatic acinar cells to produce free fatty acids (FFAs). High levels of FFAs: a) have direct cytotoxic effect on acinar and vascular endothelial cells, and b) trigger inflammatory cascade of pancreatitis [10]. Moreover, activation of pancreatic proteolytic enzymes within acinar tissues, may progress to systemic inflammation [11]. In the management of HTAP, it should be noted that the risk of acute pancreatitis increases progressively with serum triglyceride levels over 500 mg/dL (5.6 mmol/L), with the risk increasing markedly with levels over 1000 mg/dL (11.3 mmol/L) [12]. Hence, aggressive measures, to lower TG below this level, are indicated in the acute phase and its prevention. Though early support is not different from that of other causes, a) rapid correction of triggers and b) rapid lowering of TG are indicated. The first measure indicates: a) nil by mouth to avoid fatty meals and rest the pancreas, b) insulin infusion to correct hyperglycemia, reverse the stress-associated release of fatty acids from adipocytes by inhibiting hormone-sensitive lipase in adipocytes, and c) plasmapheresis in multi-organ failure and systemic acidosis by rapid lowering of TG and chylomicrons (50% - 80%) and inflammatory cytokines [13]. Theoretically, heparin anticoagulation reduces the thrombotic mechanism of HTAP and stimulates lipoprotein lipase which lowers triglyceride levels by converting them to free fatty acids [14]. However, its effect is transient with a high risk of rebound HT and bleeding in the pancreatic bed in the setting of acute pancreatitis. Hemofiltration is another controversial therapy in the management of HTG. It removes amylase and urea nitrogen from the blood, and also reduces the level of cytokines in the plasma, downregulating systemic inflammatory response [15]. In refractory cases of HTG, newer pharmacologic treatments for the targeted treatment of hypertriglyceridemia are under investigation and may be promising for patients with very high TG levels at risk for acute pancreatitis. The most promising of these are ANGPTL3 inhibitors, ApoC-III inhibitors, and Pemaifibrate [16]. Lastly, it should be noted that hypercholesterolemia is a major risk factor for atherosclerosis yet it has not been shown to cause AP [17].

4. Conclusion

In type IIb-HTAP, a) triggers can be controlled by nil-by-mouth with weekly Evolocumab-therapy and b) long-term prevention can be achieved by weight reduction and Fenofibrate alone. The approach is safe, practical and effective.

Author's Contributions

Prof/Kamel El-Reshaid conceived the study, participated in its design, and drafted the manuscript. Dr. Abass Hakim participated in the study design and tabulated the data. Dr. Reji Philip Athyal participated in manuscript preparation regarding radiological issues. All authors read and approved the final manuscript.

Data Availability Statement

The data provided in the current review are available from the references.

Conflicts of Interest

The authors declare no conflicts of interest regarding the publication of this paper.

References

- [1] Ortiz Morales, C.M., Girela Baena, E.L., Olalla Muñoz, J.R., Parlorio de Andrés, E. and López Corbalán, J.A. (2019) Radiology of Acute Pancreatitis Today: The Atlanta Classification and the Current Role of Imaging in Its Diagnosis and Treatment. *Radiologia*, **61**, 453-466. <https://doi.org/10.1016/j.rxeng.2019.06.005>
- [2] Li, C.L., Jiang, M., Pan, C.Q., Li, J. and Xu, L.G. (2021) The Global, Regional, and National Burden of Acute Pancreatitis in 204 Countries and Territories, 1990-2019. *BMC Gastroenterology*, **21**, Article No. 332. <https://doi.org/10.1186/s12876-021-01906-2>
- [3] Werge, M., Novovic, S., Schmidt, P.N. and Gluud, L.L. (2016) Infection Increases Mortality in Necrotizing Pancreatitis: A Systematic Review and Meta-Analysis. *Pancreatology*, **16**, 698-707. <https://doi.org/10.1016/j.pan.2016.07.004>
- [4] Gapp, J., Tariq, A. and Chandra, S. (2023) Acute Pancreatitis. StatPearls Publishing.
- [5] Pancreas Study Group, Chinese Society of Gastroenterology, Chinese Medical Association, Editorial Board of Chinese Journal of Pancreatology and Editorial Board of Chinese Journal of Digestion (2019) Chinese Guidelines for the Management of Acute Pancreatitis (Shenyang, 2019). *Journal of Clinical Hepatology*, **35**, 2706-2711.
- [6] Fredrickson, D.S. and Lees, R.S. (1965) A System for Phenotyping Hyperlipoproteinemia. *Circulation*, **31**, 321-327.
- [7] Brahm, A. and Hegele, R.A. (2013) Hypertriglyceridemia. *Nutrients*, **5**, 981-1001. <https://doi.org/10.3390/nu5030981>
- [8] Bays, H.E., Jones, P.H., Orringer, C.E., Brown, W.V. and Jacobson, T.A. (2016) National Lipid Association Annual Summary of Clinical Lipidology 2016. *Journal of Clinical Lipidology*, **10**, S1-S43. <https://doi.org/10.1016/j.jacl.2015.08.002>
- [9] Dominguez-Muñoz, J.E., Malfertheiner, P., Ditschuneit, H.H., Blanco-Chavez, J., Uhl, W., *et al.* (1991) Hyperlipidemia in Acute Pancreatitis. Relationship with Etiology, Onset, and Severity of the Disease. *International Journal of Pancreatology*, **10**, 261-267. <https://doi.org/10.1007/BF02924164>
- [10] Pascual, I., Sanahuja, A., García, N., Vázquez, P., Moreno, O., *et al.* (2019) Association of Elevated Serum Triglyceride Levels with a More Severe Course of Acute Pancreatitis: Cohort Analysis of 1457 Patients. *Pancreatology*, **19**, 623-629. <https://doi.org/10.1016/j.pan.2019.06.006>

- [11] Vipperla, K., Somerville, C., Furlan, A., Koutroumpakis, E., Saul, M., Chennat, J., *et al.* (2017) Clinical Profile and Natural Course in a Large Cohort of Patients with Hypertriglyceridemia and Pancreatitis. *Journal of Clinical Gastroenterology*, **51**, 77-85. <https://doi.org/10.1097/MCG.0000000000000579>
- [12] Preiss, D., Tikkanen, M.J., Welsh, P., Ford, I., Lovato, L.C., *et al.* (2012) Lipid-Modifying Therapies and Risk of Pancreatitis: A Meta-Analysis. *The Journal of the American Medical Association*, **308**, 804-811. <https://doi.org/10.1001/jama.2012.8439>
- [13] Padmanabhan, A., Connelly-Smith, L., Aqui, N., Balogun, R.A., Klingel, R., Meyer, E., *et al.* (2019) Guidelines on the Use of Therapeutic Apheresis in Clinical Practice Evidence-Based Approach from the Writing Committee of the American Society for Apheresis: The Eighth Special Issue. *Journal of Clinical Apheresis*, **34**, 171-354. <https://doi.org/10.1002/jca.21705>
- [14] Jain, P., Rai, R.R., Udawat, H., Nijhawan, S. and Mathur, A. (2007) Insulin and Heparin in Treatment of Hypertriglyceridemia-Induced Pancreatitis. *World Journal of Gastroenterology*, **13**, 2642-2643.
- [15] Boyarinov, G.A., Zubeyev, P.S., Mokrov, K.V. and Voyennov, O.V. (2020) Hemofiltration in Patients with Severe Acute Pancreatitis (Review). *Sovremennyye Tekhnologii V Medicine (Modern Technologies in Medicine)*, **12**, 105-121. <https://doi.org/10.17691/stm2020.12.1.14>
- [16] Gouni-Berthold, I., Schwarz, J. and Berthold, H.K. (2023) Updates in Drug Treatment of Severe Hypertriglyceridemia. *Current Atherosclerosis Report*, **25**, 701-709. <https://doi.org/10.1007/s11883-023-01140-z>
- [17] Yadav, D. and Pitchumoni, C.S. (2003) Issues in Hyperlipidemic Pancreatitis. *Journal of Clinical Gastroenterology*, **36**, 54-62. <https://doi.org/10.1097/00004836-200301000-00016>