



# **Vasospastic Angina: The Journey to Understanding and Easy Management**

**P. M Mulendele <sup>a\*</sup>, M.S Bettar <sup>a</sup>, M. Njie <sup>a\*</sup>, M.B Charfo <sup>a</sup>,  
B.E Ovaga <sup>a</sup>, M. Bouziane <sup>a,b,++</sup>, M. Haboub <sup>a,b,++</sup>,  
S. Arous <sup>a,b,++</sup>, M.G Benouna <sup>a,b,++</sup>, A. Drighil <sup>a,b,++</sup>  
and R. Habbal <sup>a,b,c,++</sup>**

<sup>a</sup> Department of Cardiology P37, Ibn Rochd University Hospital, Casablanca, Morocco.

<sup>b</sup> Faculty of Medicine and Pharmacy, Hassan II university of Casablanca, Casablanca, Morocco.

<sup>c</sup> Department of Cardiology, Cheikh Khalifa University Hospital, Casablanca, Morocco.

## **Authors' contributions**

*This work was carried out in collaboration among all authors. Authors PMM, MSB, and MN did Conception of the clinical case and wrote the manuscript. Authors MGB and SA reviewed the manuscript. All authors contributed to conduct of this work. All authors read and approved the final manuscript.*

## **Article Information**

DOI: 10.9734/CA/2024/v13i2403

## **Open Peer Review History:**

This journal follows the Advanced Open Peer Review policy. Identity of the Reviewers, Editor(s) and additional Reviewers, peer review comments, different versions of the manuscript, comments of the editors, etc are available here: <https://www.sdiarticle5.com/review-history/115383>

**Review Article**

**Received: 05/02/2024**  
**Accepted: 10/04/2024**  
**Published: 13/04/2024**

## **ABSTRACT**

Vasospastic angina (VSA), initially described by Prinzmetal as a form of angina occurring at rest, in the second part of the night and associated with transient changes in repolarization such as ST segment elevation on the electrocardiogram. The phenomenon of coronary spasm can occur in patients with or without coronary atherosclerosis. It can be focal or diffuse in one or more epicardial arteries. Its incidence is unknown and highly dependent on the population studied, with higher rates in Asian populations. Several pathophysiological mechanisms have been put forward to explain its occurrence, in particular endothelial dysfunction and hyperreactivity of smooth muscle cells related

<sup>++</sup> Professor;

\*Corresponding author: E-mail: [mulendelepatrick2@gmail.com](mailto:mulendelepatrick2@gmail.com), [malick1njie@hotmail.com](mailto:malick1njie@hotmail.com);

to damage to Rhokinase. Increased sympathetic nerve activity at night has shown to be involved in the mechanism underlying multivessel coronary spasm and predisposing genetic factors. Diagnosis can be easily establish using Coronary Artery Vasospastic Disorders Summit diagnostic criteria for vasospastic angina; adapted from Beltrame et al. VSA is one of the main aetiologies of MINOCA as stipulated in the last guidelines of ESC on ACS. Management of vasospastic angina is well codified based on lifestyle changes, established pharmacological therapies, control of risk factors, avoidance of triggering factors and possibly the use of percutaneous coronary intervention in cases of associated obstructive coronary artery disease, or an automatic implantable defibrillator.

*Keywords: Vasospastic angina; electrocardiogram; provocation test; calcium channel blockers.*

## ABBREVIATIONS

AVB : Atrio-Ventricular Block  
CCB : Calcium Channel Blockers  
ACS : Acute Coronary Syndrome  
ICD : Implantable Cardiac Device

## 1. INTRODUCTION

“Vasospastic angina is a variant of angina, initially described by Prinzmetal, in which angina occurs at rest and is associated with transient changes in the electrocardiogram. Vasospastic angina is a clinical and pathophysiological entity that has been known for a long time but remains underdiagnosed because it is not mentioned enough and is not often looked for even though it is potentially serious with various complications, such as sudden death of cardiac origin, acute coronary syndrome, and ventricular rhythm disorders, which constitute the various clinical scenarios” [1].

Yet the diagnosis can be made using the pharmacological provocation test during coronary angiography and its treatment can be simple with lifestyle change and the use of coronary vasodilators [2]. This article treats in detail the understanding of the pathophysiological substrate of VSA, diagnosis modalities, and treatment.

## 2. LITERATURE REVIEW

### A. GENERAL

Vasospastic angina (VSA) was initially described by Prinzmetal as a form of angina occurring at rest, in the second part of the night, and associated with transient changes in repolarization such as ST segment elevation on the electrocardiogram with sometimes the concomitant occurrence of ventricular rhythm

disturbances or atrioventricular conduction disturbances [1]. Subsequently, and especially thanks to the work of the Japanese, it was noted that the spasm is not always associated with ST segment elevation. Therefore, the term “vasospastic angina” was used [2].

The phenomenon of coronary spasm can occur in patients with or without coronary atherosclerosis. It can be focal or diffuse in one or more epicardial arteries [3]. Although coronary spasm can be complicated by sudden death, acute coronary syndrome, ventricular arrhythmia or syncope [4], its exact frequency remains poorly known due to the great variability in the use of provocation tests in the diagnostic arsenal.

Recently, the European Society of Cardiology recommended the use of coronary spasm provocation tests in patients with acute coronary syndrome with ST segment elevation (STEMI) in cases of angiographically healthy coronary arteries or with the presence of non-significant atheroma not explaining ECG abnormalities [5].

### B. PREVALENCE

“The incidence of VSA is unknown and is highly dependent on the population studied, with higher rates in Asian populations; probably due to genetic and environmental determinism”. [6] “The prevalence rate may also vary depending on the practitioner's willingness to screen for VSA by provocation testing, which may differ between catheterization laboratories. However, coronary spasms are more common than we think and remain underdiagnosed. Indeed, according to a large American registry of more than 600,000 patients, 62% of patients who had coronary angiography for chest pain did not have coronary occlusion” [7]. Contrary to this study and what was published by Prinzmetal, there is a recent Japanese study which shows that in patients who

presented with stable typical angina and in whom coronary angiography did not show (significant) lesions, the systematic performance of a provocation test showed coronary spasm in 45% of cases [8].

“Among the aetiology of myocardial infarction with no obstructive arteries (MINOCA), the systematic performance of a provocation test found 50% of coronary spasm” [9,10].

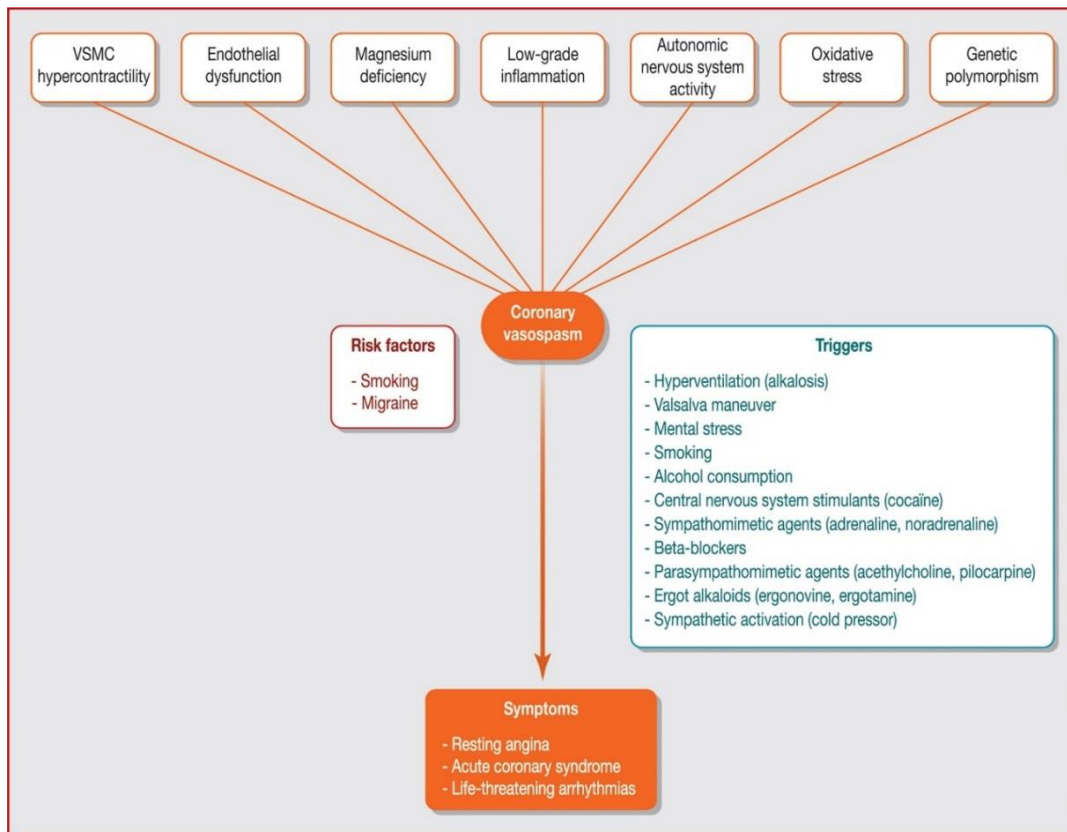
### C. PATHOPHYSIOLOGY

Coronary spasm is defined as an abnormal coronary vasoconstrictor response to an external stimulus. Several pathophysiological mechanisms have been put forward to explain its occurrence, in particular endothelial dysfunction, which can be increased by the genetic mutation of Nitric oxide (NO synthetase) and hyperreactivity of smooth muscle cells related to damage to Rho-kinase (a species of hypersensitivity of smooth muscles cells). Inflammation, oxidative stress, and an altered response of the autonomic nervous system potentially explained by genetic abnormalities

have also been implicated [11] (Fig.1). The Rho-kinase system is involved in the contractility of these cells and therefore plays a central role in spastic angina by inhibiting smooth muscle cell phosphatase and increasing the production of free radicals contributing to the dysfunction of the coronary endothelium. This explains the clinical effectiveness of inhibitors calcium and Rho-kinase inhibitors.

### I. Hyperactivity of smooth muscle cells

“Hyperresponsiveness of vascular smooth muscle cells (VSMCs) is thought to be one of the main substrates of spasms. VSMC contraction and relaxation are regulated by myosin light chain (MLC) kinase and MLC phosphatase via MLC phosphorylation and dephosphorylation, and are dependent on cytosolic calcium concentration and Rho-kinase activity. The small guanosine tri phosphatase RhoA and its downstream effector (Rho-kinase) is involved in the regulation of VSMC contractility and may play a crucial role in the pathogenesis of coronary artery spasm. Rho-kinase inhibits MLC phosphatase, leading to increased MLC



**Fig. 1. Pathophysiology of coronary artery spasm, risk factors and triggering factors. VSMC: vascular smooth muscle cell [11]**

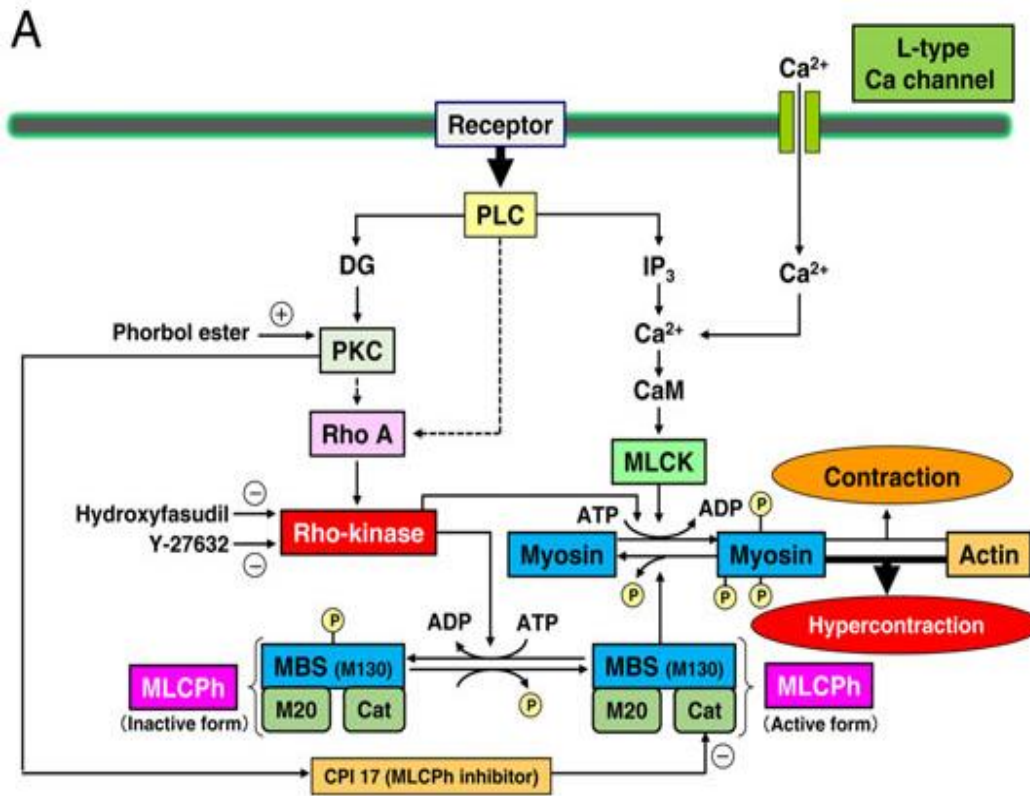


Fig. 2 A. Regulation of vascular smooth muscle contraction and relaxation. 5-HT, 5-hydroxytryptamine; ADP, adenosine diphosphate; Ang, angiotensin; ATP, adenosine triphosphate; ET-1, endothelin 1; IP<sub>3</sub>, inositol triphosphate; MLCK, myosin light chain kinase; MLCP, myosin light chain phosphatase; P, phosphorus; PLC, phospholipase C [14a]

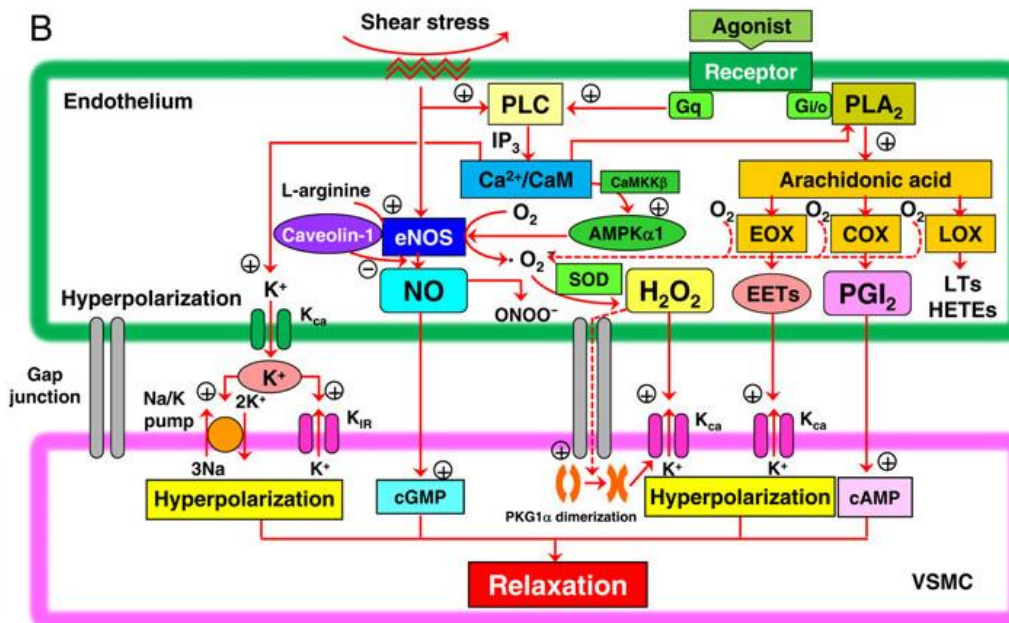


Fig. 2 B. Endothelial dysfunction [14a]

phosphorylation and calcium sensitization in response to vasoconstrictor stimuli and induces hypercontraction” [12]. “Rho-kinase is an important molecular switch that controls smooth muscle cell (SMC) contraction and relaxation independent of intracytosolic calcium concentration; it is upregulated at the spastic site and plays a key role in inducing VSMC hypercontraction [12a]. by inhibiting MLC phosphatase” [13]. “Increasing evidence indicates that Rho-kinase plays an important role in the pathogenesis of a wide range of cardiovascular diseases. Indeed, the RhoA/Rho-kinase pathway not only mediates VSMC hypercontraction through inhibition of MLC phosphatase, but also promotes cardiovascular disease by enhancing the production of reactive oxygen species” [12]. Coronary artery spasm can therefore be considered as a hypercontraction of coronary smooth muscle triggered by an increase in intracellular calcium (Fig 2 A).

## II. Endothelial dysfunction

The healthy endothelium plays a major role in the regulation of coronary vascular tone, mainly through its capacity to synthesize and release several vasodilator substances, notably NO, vasodilator prostaglandins and hyperpolarizing factors, by activation of the PLC and/or PLA2 (when binding an agonist such as serotonin or histamine), and this balances the response to vasoconstrictor stimuli, leading to vasodilation

Endothelial dysfunction will lead to a reduction in the synthesis and bioavailability of NO in the epicardial arteries and can lead to coronary spasm (Fig. 2 B), especially when it is associated with hyperactivity of the SMCs because its isolated role in the development of spasm was challenged by a study in a porcine spasm model, indicating that endothelial vasodilator function was preserved at the site of spasm [14].

### 1. Low-grade inflammation

“Chronic low-grade inflammation may play a role in coronary artery spasms; indeed, biomarkers of low-grade inflammation (C-reactive protein, monocyte chemoattractant protein-1, soluble intercellular adhesion molecule-1 and interleukin-6) are elevated in patients with VSA” [15].

### 2. Oxidative stress

“Oxygen free radicals damage vascular endothelial cells and degrade NO, leading to vasoconstriction. Biomarkers of oxidative stress

are increased and antioxidants (such as vitamin E) are decreased in patients with VSA” [16,17].

## III. Autonomic nervous system

Increased sympathetic nerve activity at night may be involved in the mechanism underlying multivessel coronary spasm. Yasue et al [18] also reported that “increased activity of the parasympathetic nervous system, which occurs at rest, may be involved in the initiation of seizures, by stimulating the sympathetic nerve and activating alpha receptors in large coronary arteries, which could, in turn, cause coronary spasms”. “Other studies have reported that sympatho-vagal imbalance may play a role in nocturnal VSA” [19].

## VI. Pathogenesis of Genetic Factors

Since coronary heart disease often runs in families and some cases occur even in patients without lifestyle problems, the involvement of "genetic factors" has been suggested. In recent years, many genes involved in the pathogenesis of coronary artery spasms have been cloned, and the 2013 guidelines for the diagnosis and treatment of patients with VSA [20] describe “the relationship between coronary artery spasms and genetic polymorphisms”. “More recently, - “786T/C eNOS” gene mutation, female gender, and diabetes mellitus was shown to correlate with Ach (Acetylcholine)-induced myocardial ischemia in patients with coronary artery spasm” [21].

## D. CLINICAL MANIFESTATIONS

Vasospastic angina can present itself in its classic form described by Prinzmetal in the form of anginal pain, occurring in the second part of the night or early in the morning, outside of any effort and associated with changes in the ECG, but it is a form that we only encounter exceptionally these days. In practice, two circumstances dominate the clinical field: patients with angina symptoms at rest and normal or near-normal coronary angiography (MINOCA); patients with an abnormal provocation test.

Vasospastic angina can also present in the form of a myocardial infarction (MI) as described in a prospective meta-analysis involving 488 patients and ¼ of the cases were associated with an MI [22]; Ventricular rhythm disturbances as well as death sudden are the other clinical presentations of VSA [23,24].

In a multicentre Japanese coronary heart disease registry study examining 1429 patients, 2% of patients had out-of-hospital cardiac arrest and 1% had AVB, ventricular arrhythmias were common and related to severity and duration of cardiac arrest.

A more recent study, performing a provocation test in patients who had an unexplained cardiac arrest (i.e. without ischemic heart disease or coronary stenosis) found up to 75% of coronary spasms and 10% ventricular rhythm disturbances [25].

### I. Risk factors

“Smoking has been reported as the major risk factor predisposing to coronary spasm, including electronic form” [26]. “Previous reports have shown a well-known association with migraine, and an association with Raynaud's phenomenon has been suggested, in the context of a generalized vasomotor disorder” [27]. However, although VSA appears to have a strong association with migraine, its association with Raynaud's phenomenon is less clear [28].

### II. Triggering factors

In addition to risk factors, certain elements can contribute to the triggering of coronary spasms, such as hyperventilation, Valsalva maneuver, mental stress [29], magnesium deficiency [30], alcohol consumption [31], cocaine [32], pharmacological molecules such as sympathomimetic agents (adrenaline, norepinephrine), beta-blockers, parasympathomimetic agents and ergot alkaloids (ergonovine, ergotamine, etc.).

### E. DIAGNOSIS OF VASOSPASTIC SPASM

Due to various clinical presentation and the fact that the coronary spasm is transient the diagnosis of VSA is difficult, with a diagnostic delay of more than 3 months, in 40% of cases, which is a bit dramatic because VSA is not a pathology without risk, since there is 56% of major cardiac events which can occur in 3 months, hence the importance of considering this diagnosis in the face of certain presentations and clinical characteristics mentioned above [33].

The ESC and Japanese guidelines recommend, for the diagnostic evaluation of vasospastic angina, in addition to the clinical characteristics, a standard 12-lead ECG during the attack, if one is lucky enough to have one, or a holter

monitoring, showing signs of myocardial ischemia; coronary angiography in patients who have resting angina with electrical changes and who respond to nitroglycerine or calcium antagonists and a provocation test in patients without angiographic lesions or non-hemodynamically significant angiographic lesions [25].

The diagnosis of VSA therefore involves three considerations: [1] the classic clinical manifestations of VSA; [2] documentation of non-critical myocardial ischemia; and [3] demonstration of significant coronary artery spasm [34] [Table 1]. The extent of evidence classifies VSAs as “definite” or “suspected.”

“**Definitive vasospastic angina**” is diagnosed if nitrate-responsive angina is evident during spontaneous episodes and transient ischemic ECG changes during spontaneous episodes or criteria for coronary artery spasm are met. “**Suspected vasospastic angina**” is diagnosed if nitrate-responsive angina is evident during spontaneous episodes, but transient ischemic electrocardiogram changes are equivocal or unavailable and criteria for coronary artery spasm are equivocal.

### 1. Clinical

The clinical criteria include anginal episodes at rest, particularly at night and in the early morning, responding to nitroglycerine and contrasting with an absence of symptoms during exercise. Painful episodes may be aggravated by hyperventilation and are improved by calcium antagonist drugs. The concurrent ECG, rarely available, finds an elevation of the ST segment, a depression of the ST segment or a negative of the T waves.

### 2. Electrocardiographic Changes

The electrocardiogram may appear normal at the start of VSA or when the spasm is mild. Total or subtotal spasm of a major coronary artery may result in a change in electrocardiogram leads, corresponding to the vasospastic coronary artery distribution. The most common electrocardiogram change during focal proximal coronary spasm is the appearance of a sharp, symmetrical T wave in approximately 50% of cases. Nevertheless, various changes may occur, including elevation and/or depression of the ST segment (Fig. 3), inversion of the T wave, an increase in the height and width of the R wave, a concomitant decrease of the magnitude



or disappearance of the S wave and the appearance of a negative U wave. Different forms of arrhythmia can also appear during a VSA, in particular, ventricular extrasystole, ventricular tachycardia and/or fibrillation (especially in the case of anterior ischemia), atrioventricular block (especially in the case of inferior ischemia), asystole and supraventricular tachycardias.

### 3. Provocation Tests and Their Indications

Provocation tests represent an essential diagnostic method. In case of strong clinical suspicion, a coronary angiography with provocation test (acetylcholine or Methergin-Methylergonovine) may be offered (Table 2). Different indication recommendations by specialist groups [20, 35] are summarized in Table 1.

Provocation tests should not be performed outside the context of conventional coronary angiography due to the possibility of refractory spasm not resolving with intravenous or sublingual vasodilator. The provocation test can

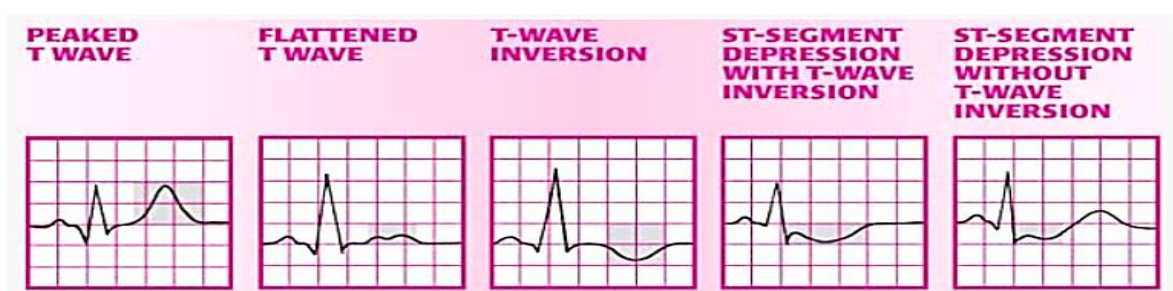
only be carried out outside the acute phase of an acute coronary syndrome with elevation of the ST segment and in the absence of significant stenosis on coronary angiography. In case of uncontrolled high blood pressure, it is also preferable to delay taking the test. The positivity (abnormality) of the test is based on the association of 3 criteria:

- a reduction in focal or diffuse coronary caliber of 90% or more;
- changes in the ECG;
- compatible anginal pain.

The test is considered contentious in the absence of one or two of the 3 components [20]. A test inducing anginal pain and ECG changes without angiographic abnormality is often associated with microvascular angina. The provocation test must be concluded by administering a nitrate derivative intravenously or sublingually in a systematic manner, including if it is normal. Potential challenge methods are summarized in Table 3.

**Table 1. Coronary Artery Vasospastic Disorders Summit diagnostic criteria for vasospastic angina; adapted from Beltrame et al [34]**

Vasospastic angina diagnostic criteria	
(1) <b>Nitrate-responsive angina-</b>	during spontaneous episode, with at least one of the following:
(a)	Rest angina-especially between night and early morning
(b)	Marked diurnal variation in exercise tolerance -reduced in morning
(c)	Hyperventilation can precipitate an episode
(d)	Calcium channel blockers (but not $\beta$ -blockers) suppress episodes
(2) <b>Transient ischemic ECG changes-</b>	during spontaneous episode, including any of the following in at least two contiguous leads:
(a)	ST segment elevation $\geq 0.1$ mV
(b)	ST segment depression $\geq 0.1$ mV
(c)	New negative U waves
(3) <b>Coronary artery spasm-</b>	defined as transient total or subtotal coronary artery occlusion (>90% constriction) with angina and provocative stimulus (typically acetylcholine, ergot, or hyperventilation)



**Fig. 3. Different ECG modifications type in vasospastic angina patients [20a]**

#### 4. Intracoronary Imaging

In some cases, the diagnosis of coronary vasospasm can be difficult, especially when it is spontaneous (after a myocardial infarction for example) and not induced by provocation tests. Intracoronary imaging, such as optical coherence tomography can address conformational changes of the intima and media

during vasospasm and can help provide information on the association of vasospasm with underlying sub-atherosclerotic plaque (is it a plaque which destabilizes with a classic ACS and which responds to the provocation test or is it a persistent significant spasm which is responsible for internal thrombosis of the artery), a rupture of the cuff fibrosis, erosion, thrombosis, necrosis or luminal irregularities [36].

**Table 2. Provocative coronary spasm testing indication by group recommendations [11]**

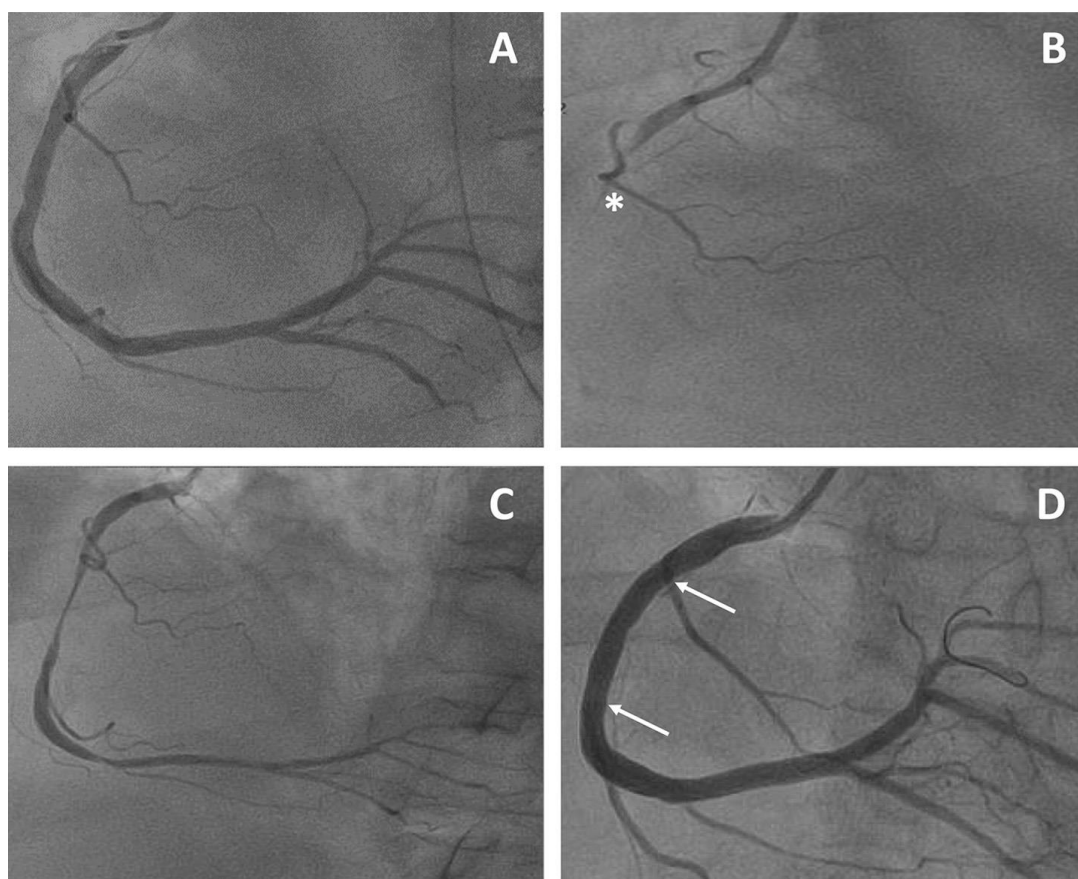
<b>COVADIS group</b>	
<b>Class I (strong indications)</b>	History suspicious of VSA without documented episode, especially if nitrate -responsive rest angina and /or marked diurnal variation in symptom onset/exercise tolerance and/or; rest angina without obstructive CAD; unresponsive to empiric therapy ACS presentation in the absence of culprit lesion Unexplained syncope with antecedent chest pain Recurrent rest angina following angiographically-successful PCI
<b>Class IIa (good indications)</b>	Invasive testing for non-invasively diagnosed patients unresponsive to drug therapy Documented spontaneous episode of VSA to determine the “site and mode” of spasm
<b>Class IIb (controversial indications)</b>	Invasive testing for non-invasively diagnosed patients responsive to drug therapy
<b>Class III (contraindications)</b>	Emergent ACS Severe fixed multivessel CAD, including left main stenosis Severe myocardial dysfunction (Class IIb if symptoms suggestive of vasospasm) Patients without any symptoms suggestive of VSA
<b>2013 Japanese Circulation Society Guidelines</b>	
<b>Class I (strong indications)</b>	Patients in whom VSA is suspected based on symptoms, but who have not been diagnosed with coronary spasm by non-invasive evaluation
<b>Class IIa (good indications)</b>	Patients who have been diagnosed with coronary spasm by non-invasive evaluation and in whom medical treatment is ineffective or insufficiently effective
<b>Class IIb (controversial indications)</b>	Acetylcholine provocation test during coronary angiography performed in patients who have been diagnosed with coronary spasm by non-invasive evaluation, and in whom medical treatment has been proven to be effective
<b>Class III (contraindications)</b>	Patients without symptoms suggestive of VSA Patients who are considered at high risk of a life-threatening complication of induced coronary spasm (e.g. patients with left main coronary trunk lesions, those with multivessel coronary lesions, including obstructive lesions, those with severe cardiac dysfunction and those with untreated congestive heart failure); however in cases in which the onset of severe cardiac dysfunction or congestive heart failure may be a consequence of coronary spasm, the criteria for Class IIb apply Patients with ACS
<b>2013 ESC guidelines on the Management of stable CAD</b>	
<b>Class IIa, Level of Evidence C</b>	Intracoronary provocative testing should be considered to identify coronary spasm in lesions on coronary angiography and the clinical picture of coronary spasm

ACS: acute coronary syndrome; CAD: coronary artery disease; COVADIS: Coronary Vasomotion Disorders International Study Group; ESC: European Society of Cardiology; PCI Percutaneous coronary intervention; VSA: Vasospastic angina



**Table 3. Provocation tests dosing protocols reported in the literature [11].**

<b>Provocative Molecule</b>	<b>Dosage</b>	<b>Protocol</b>
Ergonovine maleate	IV: 100 µg (up to 400 µg)	<ol style="list-style-type: none"> <li>1. Simultaneous electrocardiogram monitoring</li> <li>2. Angiography of LCA and RCA</li> <li>3. 100 µg of IV bolus of ergonovine maleate (up to 400 µg) at 5-minute intervals</li> <li>4. Control angiography of the LCA and RCA immediately after chest pain with ST segment elevation or depression is observed or 5 minutes after the last dose of ergonovine maleate</li> <li>5. LCA and RCA Angiography after IC/IV/Sublingual Nitrate administration</li> </ol>
	IC: ACV 20 to 60 µg; RCA 20 to 60 µg	<ol style="list-style-type: none"> <li>1. Simultaneous electrocardiogram monitoring</li> <li>2. Angiography of LCA and RCA</li> <li>3. Injection of 20 to 60 µg of ergonovine maleate into the LCA over a period of several (about 2 to 5) minutes</li> <li>4. Perform an LCA angiogram 1 to 2 minutes after the end of the injection; in the event of an ischemic change on the electrocardiogram or chest symptoms, perform an angiogram at the time of its onset; in case of a negative result of the provocation test, proceed to the RCA provocation test 5 minutes later</li> <li>5. Injection of 20 to 60 µg of ergonovine maleate into the RCA over a period of several (about 2 to 5) minutes; the timing of angiography is the same as for LCA</li> <li>6. LCA and RCA angiography after IC nitrate administration</li> </ol>
Methylergonovine	IV: 400 µg	<ol style="list-style-type: none"> <li>1. Simultaneous electrocardiogram monitoring</li> <li>2. Angiography of LCA and RCA</li> <li>3. 400 µg IV bolus of methylergonovine</li> <li>4. Control angiography of the LCA and RCA immediately after chest pain with ST segment elevation or depression is observed or 5 minutes after the last dose of methylergonovine</li> <li>5. LCA and RCA Angiography after IC/IV/Sublingual Nitrate Administration</li> </ol>
Acetylcholine	IC: ACV 20 to 100 µg; RCA: 20 to 50 µg	<ol style="list-style-type: none"> <li>1. Simultaneous electrocardiogram monitoring</li> </ol>
Ergonovine maleate	IV: 100 µg (up to 400 µg)	<ol style="list-style-type: none"> <li>2. Insertion of a temporary pacing electrode; administration of acetylcholine, especially in RCA, may cause transient episodes of severe bradycardia.</li> <li>3. Angiography of LCA and RCA</li> <li>4. Injection of 20, 50 or 100 µg of acetylcholine (concentration adjusted to obtain 5 mL of solution volume for each quantity of acetylcholine) into the LCA over a period of 20 seconds; perform an angiogram 1 minute after the start of each injection; in the event of an ischemic change in the electrocardiogram or chest pain, perform an angiogram at that time; doses of acetylcholine should be administered at 5-minute intervals</li> <li>5. Injection of 20 or 50 µg of acetylcholine (each in 5 mL of solution) into the RCA over a period of 20 seconds; the timing of angiography is the same as for LCA</li> <li>6. LCA and RCA angiography after IC nitrate administration</li> </ol>



**Fig. 4. Right coronary artery occlusive vasospasm refractory to medical treatment treated by drug-eluting stent implantation. A. Basal right coronary artery. B. Right coronary artery vasospasm after methylergonovine administration (\*). C. Refractory vasospasm under two calcium channel blockers (verapamil and amlodipine) and nitrates. D. Stent implantation to treat refractory vasospasm (arrows indicate the drug-eluting stent margins) [11]**

## F. MANAGEMENT OF VASOSPASTIC ANGINA

Conventional management of vasospastic angina is based on lifestyle modifications, established pharmacological therapies, control of risk factors, avoidance of triggering factors and possibly the use of percutaneous coronary intervention in cases of associated obstructive coronary artery disease, or an automatic implantable defibrillator.

### I. Lifestyle Modification

As vasospasm is linked to endothelial dysfunction, control of factors likely to influence oxidative stress and endothelial function is very important; thus, all cardiovascular risk factors must be controlled because atherosclerosis itself can promote the occurrence of coronary spasm. Total and definitive smoking cessation must be implemented, both active and passive. It is also important to reduce the factors that sometimes trigger spasm attacks: avoid extreme

cold, intense stress, taking cocaine, excessive consumption of alcohol, nasal vasoconstrictors, beta-blockers and ergot derivatives.

### II. Pharmacotherapy

#### 1. Calcium Channel Blockers

Medical treatment is dominated by the use of calcium channel blockers (dihydropyridines and non-dihydropyridines), drugs that reduce the contractility of smooth muscle cells and have shown effectiveness in reducing the frequency of spastic angina attacks [37,38]. Non-dihydropyridine calcium antagonists (verapamil) are more often prescribed as first-line treatment because they are better tolerated (less hypotension). In certain particularly severe or recurrent cases under anti-calcium monotherapy, the combination of two anti-calcium agents may be necessary (verapamil and diltiazem).

## 2. Nitrogen Derivatives

“Nitrates may help reduce symptoms of VSA by dilating the coronary vasculature and also by reducing ventricular filling pressures, which decreases myocardial oxygen demand and thereby decreases myocardial ischemia. Their effectiveness is rapid and even constitutes a diagnostic test. They can be prescribed as a disease-modifying treatment where they reduce the number of attacks, particularly in the long-acting form” [39]. “Several prospective randomized trials comparing the effect of long-acting nitrates alone or in combination with CCBs have demonstrated that nitrates are an effective treatment for reducing the frequency of angina in patients with VSA” [40]. “Currently, European recommendations favours nitrate derivatives in combination with calcium antagonists in the event of recurrence of spastic angina crisis under calcium inhibitors monotherapy” [5].

## 3. Statins

“Statins have been tested and validated in several studies in the prevention of coronary artery vasospasm. A prospective randomized study found that adding fluvastatin to conventional medical treatment with CCBs for 6 months significantly reduced acetylcholine-induced spasms in patients with VSA without obstructive coronary artery disease” [41]. “A retrospective study found a correlation between statin administration and reduction in long-term cardiovascular events in patients with VSA without obstructive CAD” [42]. Thus, statin treatment should be considered as an effective and safe treatment in addition to conventional treatment in patients with VSA, particularly in cases of plaque spasm on coronary angiography.

## 4. Alpha 1-Adrenergic Receptor Antagonists

“There is little evidence of their effectiveness in treating patients with spastic angina. These medications (prazosin) can be reserved, in combination with calcium antagonists, for certain patients with refractory spasm if they are tolerated; although current guidelines do not provide a specific class recommendation for their use” [43].

## 5. Rho-Kinase Inhibitors

Inhibition of Rho-kinase activity is associated with a reduction in smooth muscle cell contractility. In a study in patients with induced

spasm, intracoronary treatment with “Fasudil” reduced acetylcholine-induced spasm and prevented recurrence of chest pain [44]. “Since the mechanism of vasodilation by “Fasudil” is completely different from that of nitrates, additional administration of “Fasudil” after nitrates could promote an additive effect in coronary vasodilation” [45]. “Although numerous case reports strongly suggest the utility of intracoronary administration of fasudil in patients with multi-resistant or refractory coronary spasms” [46-48], no randomized controlled trial or observational study has objectively demonstrated that the Fasudil is superior to conventionally used vasodilators, such as nitrates and nicorandil in the relief of coronary artery spasms. This promising therapeutic class is not recommended in European guidelines.

## 6. Nicorandil

Nicorandil produces an effect similar to that of a nitrate by opening potassium channels sensitive to adenosine triphosphate and has been successfully tested in spastic angina [49]. However, current guidelines do not recommend the use of nicorandil as first-line treatment [20, 21a]. It is reserved for refractory spastic angina.

## 7. Kampo Medicines

“Kampo (Shigyakusan) medications may be considered for VSA. The association between coronary heart disease and anxiety and depression is well known. As a result, more patients with VSA have been reported to suffer from anxiety and depression than those with organic CAD” [50]. The usefulness of Kampo medications used for anxiety and depression in VSA has been noted.

## 8. Aspirin

“The use of aspirin in VSA without coexisting obstructive coronary artery disease remains debated. It has been reported that the administration of high doses of aspirin exacerbates the symptoms of VSA by blocking the production of prostacyclin which is a powerful vasodilator” [51]. “The administration of low doses of aspirin (<100 mg) remains controversial; Low doses of aspirin are known to block thromboxane A<sub>2</sub>, which is involved in coronary artery spasms, but results from clinical studies are conflicting” [52,53,54]. Thus, aspirin is not recommended in patients with VSA without significant organic stenosis.

### III. Management of Refractory Spasms

#### 1. Role of Percutaneous Coronary Intervention

The indication for treatment by angioplasty and stent implantation may arise in the event of failure of medical treatment including 1 or 2 calcium antagonists, a nitrate derivative and a statin. It is expected to be reserved for refractory focal spasms occurring in moderate atherosclerotic plaques [54].

#### 2. Implantable automatic defibrillator

"It has been reported that sudden cardiac death (SCD) from ventricular arrhythmia can occur in patients with VSA and is more common in cases refractory to medical treatment or with a history of cardiac arrest outside of the hospital" [55]

Although there are not many reports on the prognosis and availability of ICDs in VSA [55-57], a recent systematic review [56] found that "after a mean follow-up of 4.2 years, 6 % of patients with VSA died, and the mortality rate was higher in patients with sudden aborted death syndrome (ASCD) than in patients without a history of cardiac arrest (9% vs. 5%)". "Among ASCD patients, those who underwent ICD implantation had a lower mortality rate than those who did not (3% vs. 14%), and appropriate ICD treatment was observed in 17% of patients. Thus, in these patients and those with potentially fatal ventricular arrhythmias due to a VSA, an ICD should be considered due to the risk of recurrence despite optimal medical management, current recommendations consider the implantation of an implantable cardioverter defibrillator for the secondary prevention of resuscitated sudden cardiac death" [55-57].

#### 3. Stellate ganglion block, thoracic sympathectomy

Autonomic dysfunction is thought to be involved in the pathogenesis of coronary artery spasm [58], and that an imbalance between the sympathetic and parasympathetic nervous systems caused a predominance of sympathetic nervous system activity, which in turn affected coronary artery spasms. [59].

Stellate ganglion block and/or thoracic sympathectomy may be considered as one of the non-pharmacological treatments for refractory angina associated with increased sympathetic

tone (often during the day and induced by stress or activity physical). A Prospective Randomized Study of the Effect of Thoracic Sympathectomy on Coronary Artery Spasm [60], Evaluating the Effect of Thoracoscopic Thoracic Sympathectomy on MACE for 24 Months in 79 Patients with Drug-Refractory VSA Randomized to Undergo Sympathectomy thoracoscopic chest or medical treatment. The MACE rate at 24 months was significantly lower in the thoracic sympathectomy group than in the medical treatment group. Thus, a stellate lymph node block and/or thoracic sympathectomy may be considered in cases of refractory or severe VSA.

#### 4. Assessment of the refractory nature of the spasm

The place of provocation tests in treated spastic patients is poorly defined. These provocation tests can highlight abnormal vasoconstriction effect despite calcium antagonists' treatment and lead to an increase in this, or even to a proposal for coronary angioplasty in the event of focal spasm [61] but can, in patients with ASCD due to coronary artery spasm, be an option when deciding on a mechanics [62]. The disappearance of any spastic phenomenon under treatment during a new provocation test conversely encourages the continuation of the treatment thus validated.

### G. PROGNOSIS

Undiagnosed, and therefore untreated, coronary spasm can be complicated by rhythm disturbances, conduction disturbances and sudden death, whereas the overall prognosis of spastic angina is good with calcium antagonists' treatment. In a Japanese study of 245 patients with AVS, the survival rate at 1, 3, 5 and 10 years was 98%, 97%, 97% and 93%. The myocardial infarction-free survival rates at 1, 3, 5 and 10 years were 86%, 85%, 83% and 81%, respectively [63]. However, it is important to note that patients with spastic angina suffering from a heart attack or acute coronary syndrome have a worse prognosis than others [64].

### 3. CONCLUSION

Vasospastic angina is an entity known for a long time and well codified, still underdiagnosed and of multifactorial origin. Provocation tests performed during normal coronary angiography or without significant coronary lesions occupy a central place and are essential in diagnosis and

therapeutic evaluation. The spontaneous prognosis is severe while calcium antagonist treatments are very effective and help limit the serious complications associated with undiagnosed vasospastic angina.

## CONSENT

It is not applicable.

## ETHICAL APPROVAL

It is not applicable.

## COMPETING INTERESTS

Authors have declared that no competing interests exist.

## REFERENCES

1. Prinzmetal M, Kennamer R, Merliss R et al. Angina pectoris. I. A variant form of angina pectoris; preliminary report. *Am J Med.* 1959; 27:375-388.
2. Bugiardini R, Cenko E. A Short History of Vasospastic Angina. *J Am Coll Cardiol.* 2017 7;70(19):2359-2362.
3. Oliva PB, Potts DE, Pluss RG. Coronary arterial spasm in Prinzmetal angina. Documentation by coronary arteriography. *New Engl J Med.* 1973; 288:745-751.
4. Nakamura M, Takeshita A, Nose Y. Clinical characteristics associated with myocardial infarction, arrhythmias, and sudden death in patients with vasospastic angina. *Circulation.* 1987; 75:1110-1116
5. Ibanez B, James S, Agewall S et al. 2017 ESC Guidelines for the management of acute myocardial infarction in patients presenting with ST-segment elevation: The Task Force for the management of acute myocardial infarction in patients presenting with ST-segment elevation of the European Society of Cardiology (ESC). *Eur Heart J.* 2018; 39:119-177.
6. Bertrand ME, LaBlanche JM, Tilmant PY et al. Frequency of provoked coronary arterial spasm in 1089 consecutive patients undergoing coronary arteriography. *Circulation.* 1982; 65:1299-1306.
7. Patel MR, Peterson ED, Dai D, Brennan JM, Redberg RF, Anderson HV, Brindis RG, Douglas PS. Low diagnostic yield of elective coronary angiography. *N Engl J Med.* 2010;362(10):886-95.
8. Ong P, Athanasiadis A, Borgulya G, Mahrholdt H, Kaski JC, Sechtem U. High prevalence of a pathological response to acetylcholine testing in patients with stable angina pectoris and unobstructed coronary arteries. The ACOVA Study (Abnormal COronary VAsomotion in patients with stable angina and unobstructed coronary arteries). *J Am Coll Cardiol.* 2012;59(7):655-62.
9. Tsao CW, Aday AW, Almarzooq ZI, Alonso A, Beaton AZ, Bittencourt MS, Boehme AK, Buxton AE, Carson AP, Commodore-Mensah Y, Elkind MSV, Evenson KR, Eze-Nliam C, Ferguson JF, Generoso G, Ho JE, Kalani R, Khan SS, Kissela BM, Knutson KL, Levine DA, Lewis TT, Liu J, Loop MS, Ma J, Mussolino ME, Navaneethan SD, Perak AM, Poudel R, Rezk-Hanna M, Roth GA, Schroeder EB, Shah SH, Thacker EL, VanWagner LB, Virani SS, Voecks JH, Wang NY, Yaffe K, Martin SS. Heart Disease and Stroke Statistics-2022 Update: A Report From the American Heart Association. *Circulation.* 2022;145(8): e153-e639.
10. Ong P, Athanasiadis A, Hill S, Vogelsberg H, Voehringer M, Sechtem U. Coronary artery spasm as a frequent cause of acute coronary syndrome: The CASPAR (Coronary Artery Spasm in Patients with Acute Coronary Syndrome) Study. *J Am Coll Cardiol.* 2008;52(7):523-7.
11. Picard F, Sayah N, Spagnoli V et al. Vasospastic angina: A literature review of current evidence. *Arch Cardiovasc Dis.* 2019; 112:44-55.
12. Shimokawa H, Sunamura S, Satoh K. RhoA/Rho-kinase in the cardiovascular system. *Circulation research.* 2016;118(2):352-366.
- 12a. Wang DY, Okoye GD, Neilan TG, Johnson DB, Moslehi JJ. Cardiovascular Toxicities Associated with Cancer Immunotherapies. *Curr Cardiol Rep.* 2017;19(3):21.
13. Kandabashi T, Shimokawa H, Miyata K, Kunihiro I, Kawano Y, Fukata Y, Takeshita An. Inhibition of myosin phosphatase by upregulated Rho-kinase plays a key role for coronary artery spasm in a porcine model with interleukin 1 $\beta$ . *Circulation.* 2000;101(11):1319-1323.

14. Miyata K, Shimokawa H, Yamawaki T, Kunihiro I, Zhou X, Higo T, Takeshita A. Endothelial vasodilator function is preserved at the spastic/inflammatory coronary lesions in pigs. *Circulation*. 1999;100(13):1432-1437.
- 14a. Shimokawa H. Conférence Williams Harvey 2014 : Importance des anomalies de vasomotion coronarienne, du banc au chevet. *European Heart Journal*. 2014;35 :3180–3193
15. Hung MJ, Cherng WJ, Cheng CW Li, LF. Comparaison des taux sériques de marqueurs inflammatoires chez les patients présentant un vasospasme coronarien sans maladie coronarienne fixe significative par rapport aux patients présentant une angine de poitrine stable et des syndromes coronariens aigus avec une maladie coronarienne fixe significative. *Le journal américain de cardiologie*. 2006;97(10):1429-1434.
16. Miyamoto S, Kawano H, Sakamoto T, Soejima H, Kajiwara I, Hokamaki J, Ogawa H. Increased plasma levels of thioredoxin in patients with coronary spastic angina. *Antioxidants and Redox Signaling*. 2004;6(1):75-80.
17. Miwa K, Igawa A, Nakagawa K, Hirai T, Inoue H. Consumption of vitamin E in coronary circulation in patients with variant angina. *Cardiovascular research*. 1999;41(1):291-298.
18. Yasue H, TOuYAMA MASATO, Shimamoto M, Kato H, Tanaka S, Akiyama F. Role of autonomic nervous system in the pathogenesis of Prinzmetal's variant form of angina. *Circulation*. 1974;50(3):534-539.
19. Miwa K, Igawa A, Miyagi Y, Nakagawa K, Inoue H. Alterations of autonomic nervous activity preceding nocturnal variant angina: sympathetic augmentation with parasympathetic impairment. *American heart journal*. 1998;135(5):762-771.
20. JCS Joint Working Group. Guidelines for diagnosis and treatment of patients with vasospastic angina (Coronary Spastic Angina) (JCS 2013). *Circ J*. 2014;78 (11):2779-801.
- 20a. Images.available: <https://aneskey.com/disorders-affecting-12-lead-ecgs/#H2-DA3-C14>
21. Kaikita K, Ishii M, Sato K, Nakayama M, Arima Y, Tanaka T, Sugamura K, Sakamoto K, Izumiya Y, Yamamoto E, Tsujita K, Yamamuro M, Kojima S, Soejima H, Hokimoto S, Matsui K, Ogawa H. Determinants of Myocardial Lactate Production During Acetylcholine Provocation Test in Patients with Coronary Spasm. *J Am Heart Assoc*. 2015;4(12): e002387.
- 21a. Sun H, Mohri M, Shimokawa H, Usui M, Urakami L, Takeshita A. Coronary microvascular spasm causes myocardial ischemia in patients with vasospastic angina. *J Am Coll Cardiol*. 2002;39 (5):847-51.
22. Ong P, Athanasiadis A, Hill S, Vogelsberg H, Voehringer M, Sechtem U. Coronary artery spasm as a frequent cause of acute coronary syndrome: The CASPAR (Coronary Artery Spasm in Patients with Acute Coronary Syndrome) Study. *J Am Coll Cardiol*. 2008;52(7):523-7.
23. Bayes de Luna A, Carreras F, Cladellas M, Oca F, Sagues F, Garcia Moll M. Holter ECG study of the electrocardiographic phenomena in Prinzmetal angina attacks with emphasis on the study of ventricular arrhythmias. *J Electrocardiol*. 1985;18(3): 267-75.
24. Halna du Fretay X, Mohammed Saeed D, Benamer H. Mort subite et angor spastique: quelle stratégie diagnostique et thérapeutique? [Diagnosis and treatment of spastic angina revealed by cardiac arrest]. *Ann Cardiol Angeiol (Paris)*. 2014; 63(6):465-70.
25. Tateishi K, Saito Y, Kitahara H, Takaoka H, Kondo Y, Nakayama T, Fujimoto Y, Kobayashi Y. Vasospastic angina and overlapping cardiac disorders in patients resuscitated from cardiac arrest. *Heart Vessels*. 2021;36(3):321-329.
26. Takaoka K, Yoshimura M, Ogawa H, Kugiyama K, Nakayama M, Shimasaki Y, ... et Yasue H. Comparaison des facteurs de risque de spasme coronarien avec ceux de sténose organique dans une population japonaise: rôle du tabagisme. *Revue internationale de cardiologie* . 2000;72(2):121-126.
27. Miller D, Waters DD, Warnica W, Szlachcic J, Kreeft J, Thérout P. Is variant angina the coronary manifestation of a generalized vasospastic disorder? *New England Journal of Medicine*. 1981;304 (13):763-766.



28. Nakamura Y, Shinozaki N, Hirasawa M, Kato R, Shiraishi KI, Kida H, Ishikawa T. Prevalence of migraine and Raynaud's phenomenon in Japanese patients with vasospastic angina. *Japanese circulation journal*. 2000;64(4):239-242.
29. Yeung AC, Vekshtein VI, Krantz DS, Vita JA, Ryan Jr TJ, Ganz P, Selwyn AP. The effect of atherosclerosis on the vasomotor response of coronary arteries to mental stress. *New England Journal of Medicine*. 1991;325(22):1551-1556.
30. Satake K, Lee JD, Shimizu H, Ueda T, et Nakamura T. Relation entre la gravité de la carence en magnésium et la fréquence des crises angineuses chez les hommes souffrant d'angine variante. *Journal de l'American College of Cardiology*. 1996; 28(4):897-902.
31. Oda H, Suzuki M, Oniki T, Kishi Y, Numano F. Alcohol and coronary spasm. *Angiology*. 1994;45(3):187-197.
32. Kalsner STANLEY. Sensibilisation à la cocaïne des contractions des artères coronaires : mécanisme des spasmes induits par le médicament. *Journal de pharmacologie et de thérapeutique expérimentale*. 1993;264(3):1132-1140.
33. Lanza GA, Sestito A, Sgueglia GA, Infusino F, Manolfi M, Crea F, Maseri A. Current clinical features, diagnostic assessment and prognostic determinants of patients with variant angina. *Int J Cardiol*. 2007;118(1):41-7.
34. Beltrame JF, Crea F, Kaski JC, Ogawa H, Ong P, Sechtem U, et. Groupe d'étude international sur les troubles coronariens vasomotionnels (COVADIS). Standardisation internationale des critères diagnostiques de l'angine vasospastique. *Journal européen du cœur*. 2017;38(33): 2565-2568.
35. Montalescot G, Sechtem U, Achenbach S, Andreotti F, Arden C, Budaj A, Yildirir A. ESC guidelines on the management of stable coronary artery disease. *European heart journal*. 2013;34: 2949-3003.
36. Tanaka A, Shimada K, Tearney GJ, Kitabata H, Taguchi H, Fukuda S, Akasaka T. Conformational change in coronary artery structure assessed by optical coherence tomography in patients with vasospastic angina. *Journal of the American College of Cardiology* .2011;58 (15):1608-1613.
37. Higuma T, Oikawa K, Kato T, Mori Y, Kudo T, Yamamoto T, Hoshi Y, Kameda K, Suto N, Fujita N, Inokubo Y, Konta A, Osanai T, Okumura K. Comparison of the effects of long-acting nifedipine CR and diltiazem R in patients with vasospastic angina: Aomori coronary spastic angina study. *J Cardiol*. 2010;56(3):354-60.
38. Chahine RA, Feldman RL, Giles TD, Nicod P, Raizner AE, Weiss RJ, Vanov SK. Randomized placebo-controlled trial of amlodipine in vasospastic angina. Amlodipine Study 160 Group. *J Am Coll Cardiol*. 1993;21(6):1365-70.
39. Schroeder JS, Bolen JL, Quint RA, Clark DA, Hayden WG, Higgins CB, Wexler L. Provocation of coronary spasm with ergonovine maleate. New test with results in 57 patients undergoing coronary arteriography. *Am J Cardiol*. 1977;40(4) :487-91.
40. Schroeder JS. Combination therapy with isosorbide dinitrate: current status and the future. *American Heart Journal*. 1985;110 (1):284-291.
41. Yasue H, Mizuno Y, Harada E, Itoh T, Nakagawa H, Nakayama M, SCAST (Statin and Coronary Artery Spasm Trial) Investigators. Effects of a 3-hydroxy-3-methylglutaryl coenzyme A reductase inhibitor, fluvastatin, on coronary spasm after withdrawal of calcium-channel blockers. *Journal of the American College of Cardiology*. 2008;51(18):1742-1748.
42. Ishii M, Kaikita K, Sato K, Yamanaga K, Miyazaki T, Akasaka T, et Ogawa H. Impact du traitement par statines sur les résultats cliniques chez les patients souffrant de spasmes coronariens. *Journal de l'American Heart Association*. 2016;5 (5): e003426.
43. Tzivoni D, Keren A, Benhorin J, Gottlieb S, Atlas D, et Stern S. Thérapie à la prazosine pour l'angor variante réfractaire. *American Heart Journal*. 1983; 105(2): 262-266.
44. Masumoto A, Mohri M, Shimokawa H, Urakami L, Usui M, Takeshita A. Suppression of coronary artery spasm by the Rho-kinase inhibitor fasudil in patients with vasospastic angina. *Circulation*. 2002; 105(13):1545-7.
45. Otsuka T, Ibuki C, Suzuki T, Ishii K, Yoshida H, Kodani E, Kusama Y, Atarashi H, Kishida H, Takano T, Mizuno K.

- Administration of the Rho-kinase inhibitor, fasudil, following nitroglycerin additionally dilates the site of coronary spasm in patients with vasospastic angina. *Coron Artery Dis.* 2008;19(2):105-10.
46. Arakawa K, Himeno H, Gondo T, Kirigaya J, Otomo F, Matsushita K, Nakahashi H, Shimizu S, Nitta M, Yano H, Endo M, Kimura K, Umemura S. Refractory vasospasms of the coronary arteries due to multiple factors: an autopsy case. *Intern Med.* 2014;53(9):963-7.
  47. Shimmyo T, Omori T, Hirano A, Masuda M. Secondary systemic artery to pulmonary artery and pulmonary vein fistulas following the video-assisted thoracic surgery for pneumothorax: a case report. *Surg Case Rep.* 2018;4(1):1.
  48. Kikuchi Y, Takahashi J, Hao K, Sato K, Sugisawa J, Tsuchiya S, Suda A, Shindo T, Ikeda S, Shiroto T, Matsumoto Y, Miyata S, Sakata Y, Shimokawa H. Usefulness of intracoronary administration of fasudil, a selective Rho-kinase inhibitor, for PCI-related refractory myocardial ischemia. *Int J Cardiol.* 2019; 297:8-13.
  49. Kishida H, Murao S. Effect of a new coronary vasodilator, nicorandil, on variant angina pectoris. *Clinical Pharmacology & Therapeutics.* 1987;42(2):166-174.
  50. Hung MY, Mao CT, Hung MJ, Wang JK, Lee HC, Yeh CT, Hu P, Chen TH, Chang NC. Coronary Artery Spasm as Related to Anxiety and Depression: A Nationwide Population-Based Study. *Psychosom Med.* 2019;81(3):237-245.
  51. Miwa K, Kambara H, Kawai C. Effect of aspirin in large doses on attacks of variant angina. *American heart journal.* 1983;105(2):351-355.
  52. Kim MC, Ahn Y, Park KH, Sim DS, Yoon NS, Yoon HJ, ... et Kang JC. Résultats cliniques de l'administration d'aspirine à faible dose chez les patients atteints d'angine de poitrine variante. *Revue internationale de cardiologie.* 2013;167(5):2333-2334.
  53. Lin Y, Chen Y, Yuan J, Qin H, Dong S, Chen Q. Impact of aspirin use on clinical outcomes in patients with vasospastic angina: A systematic review and meta-analysis. *BMJ Open.* 2021;11(7): e048719.
  54. Khatri S, Webb JG, Carere RG, Dodek A. Stenting for coronary artery spasm. *Catheter Cardiovasc Interv.* 2002;56(1):16-20.
  55. Ogino Y, Ishikawa T, Minamimoto Y, Kiyokuni M, Kimura Y, Akiyama E, Okada K, Konishi M, Hosoda J, Matsuzawa Y, Maejima N, Iwahashi N, Matsumoto K, Hibi K, Kosuge M, Ebina T, Tamura K, Kimura K. Characteristics and Prognosis of Patients with Vasospastic Angina Diagnosed by a Provocation Test with Secondary Prevention Implantable Cardioverter Defibrillator. *Int Heart J.* 2021; 62(2):224-229.
  56. van der Lingen ACJ, Woudstra J, Becker MAJ, Mol MAE, van Rossum AC, Rijnierse MT, Allaart CP. Recurrent ventricular arrhythmias and mortality in cardiac arrest survivors with a reversible cause with and without an implantable cardioverter defibrillator: A systematic review. *Resuscitation.* 2022; 173:76-90.
  57. Mise à jour ciblée des lignes directrices JCS/CVIT/JCC 2023 sur le diagnostic et le traitement de l'angine vasospastique (angine coronarienne spastique) et du dysfonctionnement microvasculaire coronarien. 87;2023(6).
  58. Nakamura M, Takeshita A, Nose Y. Clinical characteristics associated with myocardial infarction, arrhythmias, and sudden death in patients with vasospastic angina. *Circulation.* 1987;75(6):1110-6.
  59. Miwa K, Igawa A, Miyagi Y, Nakagawa K, Inoue H. Alterations of autonomic nervous activity preceding nocturnal variant angina: sympathetic augmentation with parasympathetic impairment. *Am Heart J.* 1998;135(5 Pt 1):762-71.
  60. Lin Y, Liu H, Yu D, Wu M, Liu Q, Liang X, Pang X, Chen K, Luo L, Dong S. Sympathectomy versus conventional treatment for refractory coronary artery spasm. *Coron Artery Dis.* 2019;30(6):418-424.
  61. Sueda S, Kohno H, Miyoshi T, Sasaki Y, Sakaue T, Habara H. Spasm provocation tests performed under medical therapy: a new approach for treating patients with refractory coronary spastic angina on emergency admission. *Intern Med.* 2014;53(16):1739-47.
  62. Sueda S, Sakaue T, Okura T. Spasm Provocation Tests under Medication May Help Decide on Medical or Mechanical Therapy in Patients with Aborted Sudden

- Cardiac Death due to Coronary Spasm. *Intern Med.* 2020;59(11):1351-1359.  
DOI:10.2169/internalmedicine.4158-19  
Epub 2020 Mar 5. PMID: 32132336;  
PMCID: PMC7332636.
63. Yasue H, Takizawa A, Nagao M, Nishida S, Horie M, Kubota J, Omote S, Takaoka K, Okumura K. Long-term prognosis for patients with variant angina and influential factors. *Circulation.* 1988;78(1):1-9.
64. Cho SW, Park TK, Gwag HB, Lim AY, Oh MS, Lee DH, Seong CS, Yang JH, Song YB, Hahn JY, Choi JH, Lee SH, Gwon HC, Choi SH. Clinical Outcomes of Vasospastic Angina Patients Presenting with Acute Coronary Syndrome. *J Am Heart Assoc.* 2016;5(11): e004336.

---

© Copyright (2024): Author(s). The licensee is the journal publisher. This is an Open Access article distributed under the terms of the Creative Commons Attribution License (<http://creativecommons.org/licenses/by/4.0>), which permits unrestricted use, distribution, and reproduction in any medium, provided the original work is properly cited.

*Peer-review history:*  
*The peer review history for this paper can be accessed here:*  
<https://www.sdiarticle5.com/review-history/115383>