

## The management of the acute setting of pelvic fracture urethral injury (realignment vs. suprapubic cystostomy alone)

Jonathan N. Warner & Richard A. Santucci

To cite this article: Jonathan N. Warner & Richard A. Santucci (2015) The management of the acute setting of pelvic fracture urethral injury (realignment vs. suprapubic cystostomy alone), Arab Journal of Urology, 13:1, 7-12, DOI: [10.1016/j.aju.2014.08.003](https://doi.org/10.1016/j.aju.2014.08.003)

To link to this article: <https://doi.org/10.1016/j.aju.2014.08.003>



© 2014 Arab Association of Urology



Published online: 05 Apr 2019.



Submit your article to this journal [↗](#)



Article views: 345




View related articles [↗](#)



View Crossmark data [↗](#)



Citing articles: 1 View citing articles [↗](#)



## INITIAL MANAGEMENT OF PFUI REVIEW

# The management of the acute setting of pelvic fracture urethral injury (realignment vs. suprapubic cystostomy alone)



Jonathan N. Warner \*, Richard A. Santucci

Detroit Medical Center, Detroit, MI, USA

Received 9 June 2014, Received in revised form 25 July 2014, Accepted 11 August 2014

Available online 17 September 2014

### KEYWORDS

Pelvic fracture;  
Urethral injury;  
Urethral realignment

### ABBREVIATIONS

PFUI, pelvic fracture urethral injury;  
STDU, suprapubic tube with delayed urethroplasty;  
ED, erectile dysfunction;  
EPR, early non-endoscopic realignment;

**Abstract Background:** In patients with pelvic fracture urethral injury there are two options for management: First, to realign as an early primary realignment over a catheter; and second, to place a suprapubic tube with delayed urethroplasty of the inevitable stricture.

**Methods:** We reviewed previous reports from 1990 to the present, comparing early endoscopic realignment, early open realignment and suprapubic tube placement, to determine the rates of incontinence, erectile dysfunction and stricture formation.

**Results:** Twenty-nine articles were identified. The rates of erectile dysfunction, incontinence, and stricture formation, respectively, were: for early endoscopic realignment, 20.5%, 5.8% and 43.8%; for open realignment over a catheter, 16.7%, 4.7% and 48.9%; and for a suprapubic tube and delayed urethroplasty 13.7%, 5.0%, and 89.0%. A one-way anova showed no difference in the mean rate of erectile dysfunction ( $P = 0.53$ ) or incontinence ( $P = 0.73$ ), and only stricture formation was significantly different ( $P < 0.1$ ).

\* Corresponding author. Address: Detroit Medical Center, 4901 John R. Suite 1021, Detroit, MI 48201, USA.

E-mail address: [Jonathan.n.warner@gmail.com](mailto:Jonathan.n.warner@gmail.com) (J.N. Warner).

Peer review under responsibility of Arab Association of Urology.



EER, early endoscopic realignment

**Conclusion:** The rates of incontinence and erectile dysfunction are similar between the groups. Only the rate of stricture formation was higher in the suprapubic tube and delayed urethroplasty group.

© 2014 Production and hosting by Elsevier B.V. on behalf of Arab Association of Urology.

## Introduction

In patients with pelvic fracture urethral injury (PFUI), there are two options for management. The first is early primary realignment over a catheter, and the second is to place a suprapubic tube with delayed urethroplasty (STDU) of the inevitable stricture. Here we evaluate the historical development of the treatment of PFUI and review contemporary reports for the risks and benefits of each therapy, using a one-way anova to compare the mean rates of complications.

### Historical overview

Young [1] in 1929 was the first to report the immediate open surgical repair of a PFUI via a perineal approach. Later, it was determined that the lithotomy position associated with the perineal approach was unfavourable with concomitant pelvic fractures; the perineal approach was abandoned for a retropubic approach [2,3]. Whilst the retropubic approach might be safer for a patient with recent fractures, the repair necessitates exploration and dissection of an already traumatised region [4]. Importantly, further reports showed a greater risk of erectile dysfunction (ED) associated with the retropubic approach than with a STDU (0% vs. 33%), probably due to damage to the surrounding neurovascular bundle [5]. There was also concern that dissecting the retropubic space could convert a partial urethral tear into a complete urethral tear [6]. With this being the case, the immediate open retropubic surgical repair of an acute PFUI injury fell out of favour.

Meanwhile, urologists were also working on realignment techniques, to bring the urethra together over a catheter, without retropubic dissection. The first realignment was reported in 1934 [7]. Traction was then added to the catheter placed through the urethra, via weights, to aid in the re-approximation of the urethral edges [8]. Several further studies showed that there was still fibrous tissue bridging the gap, and not mucosa, even with the aid of weights [2,9]. In addition, the use of weights was abandoned as it was shown to cause worse incontinence because of damage to the bladder neck, and distal urethral necrosis [10].

In 1953, Johanson [11] was the first to question whether or not the STDU was superior to the realignment strategy. Whilst the stricture is inevitable, a STDU guarantees that the degree of ED is due to the initial

injury and not the manipulation for early non-endoscopic realignment (EPR) [12]. Suprapubic cystotomy became the preferred treatment for the next 30 years [4]. In the early 1990s novel techniques for minimally invasive, radiological and endoscopic techniques for realignment were introduced which challenged the standard of suprapubic cystotomy alone [13–16]. Since then, there have been many reports arguing for both methods of the management.

### Complications

The goal of management is to realign the urethra whilst minimising the risks of ED, incontinence and subsequent urethral stricture [4]; Table 1 [13–41] and Fig. 1 summarise the findings of the above complications in early endoscopic realignment (EER), early open primary realignment, and STDU in studies from 1990 to the present. Importantly, in these series, many of the patients did not undergo primary realignment because of haemodynamic instability of the patient, or failure of primary realignment, which might be associated with a worse initial injury.

### ED

The main concern of EPR is further damage to the neurovascular bundle. Whilst the open retropubic approach probably affects the neurovascular bundle [5], increasing the risk of ED [4,42], there is growing evidence that this is no longer the case with primary EER techniques currently used [4,32,35]. Dhabuwala et al. [43] were the first to suggest that the injury, not the treatment, induced the ED. Kotkin and Koch [35] went on to report their experience with EPR vs. simple catheter placement (with partial disruption), and found no difference to suggest that EPR made the ED worse. MRI [44] and MRI with duplex ultrasonography [45] studies show that patients with ED have more significant damage than those with no ED, all in a cohort of patients who had been treated only with STDU. Table 1 summarises the finding that rates of ED are equal between EER ( $P = 0.53$ ), EPR and STDU, at 20.5%, 16.7% and 13.7%, respectively.

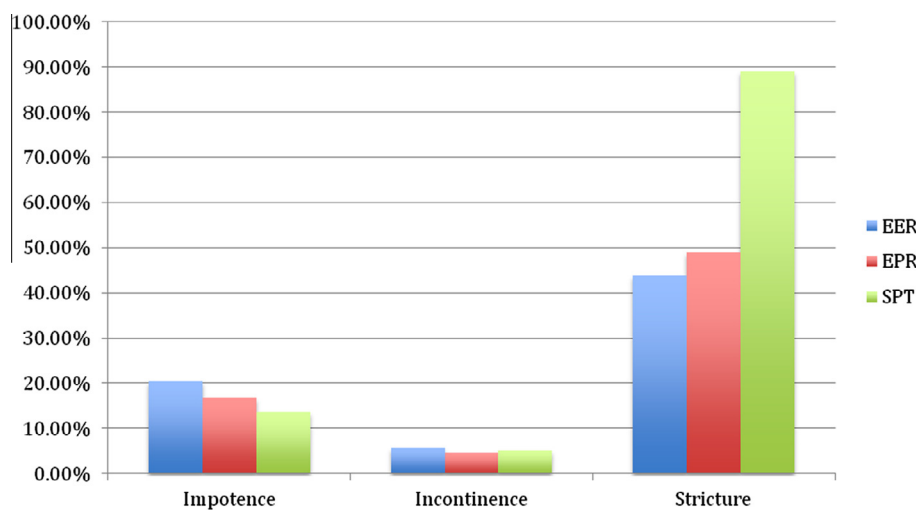
### Incontinence

Incontinence after a PFUI is rare, and when present it is believed that the initial injury is responsible for the

**Table 1** Contemporary studies evaluating EER, EPR and STDU for rates of ED, incontinence, and stricture formation.

Year	Refs	No. of patients	EER, % or <i>n</i> * with				EPR, % or <i>n</i> * with				STDU, % or <i>n</i> * with			
			No.	ED	IC	S	No.	ED	IC	S	No.	ED	IC	S
1991	[13]	5	5	2	0	4	–	–	–	–	–	–	–	–
1991	[14]	5	5	4	2	4	–	–	–	–	–	–	–	–
1993	[17]	10	10	5	1	6	–	–	–	–	–	–	–	–
1997	[15]	3	3	0	0	1	–	–	–	–	–	–	–	–
1998	[18]	6	6	1	0	4	–	–	–	–	–	–	–	–
1999	[19]	8	8	3	1	7	–	–	–	–	–	–	–	–
2001	[20]	10	6	0	1	3	–	–	–	–	–	–	–	–
2001	[21]	29	27	14.8	0	44.4	–	–	–	–	2	0	0	2
2002	[22]	95	65	3.1	0	18.5	–	–	–	–	30	3.3	0	40
2003	[23]	36	36	19.4	0	41.7	–	–	–	–	–	–	–	–
2005	[24]	96	57	33.3	17.5	49.1	–	–	–	–	36	33.3	25	100
2007	[25]	10	8	50	0	50	–	–	–	–	2	0	0	2
2008	[26]	21	18	0	0	22.2	–	–	–	–	3	0	0	2
2010	[27]	10	9	0	0	4	–	–	–	–	1	0	0	2
2010	[28]	11	11	6	0	5	–	–	–	–	–	–	–	–
2012	[29]	19	19	0	0	74	–	–	–	–	–	–	–	–
2013	[30]	18	15	47	20	53	–	–	–	–	–	–	–	–
1990	[31]	81	–	–	–	–	17	0	0	53	64	0	0	95
1992	[32]	16	–	–	–	–	13	42	0	54	3	3	0	3
1992	[33]	33	–	–	–	–	20	20	5	15	13	46	0	85
1996	[34]	96	–	–	–	–	23	28	4	52	73	0.2	2.7	97.3
1996	[35]	30	–	–	–	–	26	13	12	39	–	–	–	–
1997	[36]	4	–	–	–	–	4	2	2	2	–	–	–	–
1997	[37]	29	–	–	–	–	10	0	0	10	19	0	16	100
1997	[16]	10	–	–	–	–	10	1	0	5	–	–	–	–
1997	[38]	53	–	–	–	–	53	20.8	3.8	66.0	–	–	–	–
1999	[39]	38	–	–	–	–	20	20	10	45	18	17	6	83
2005	[40]	20	–	–	–	–	12	0	0	6	8	0	0	6
2005	[41]	25	–	–	–	–	25	16	0	24	–	–	–	–
TOTAL		827	308	20.5	5.8	43.8	233	16.7	4.7	48.9	272	13.7	5.0	89.0

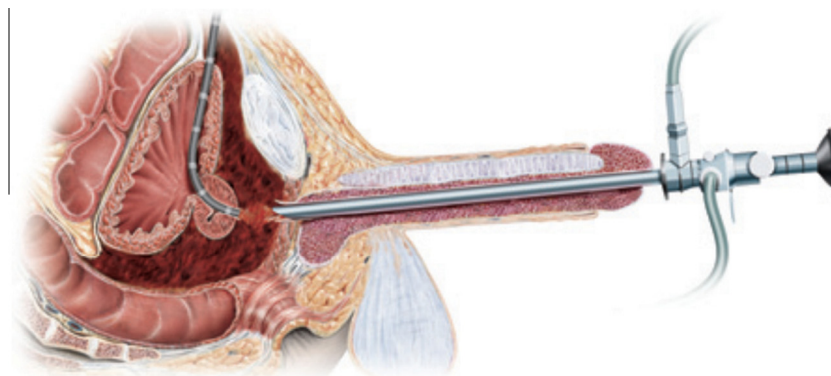
IC, incontinence; S, stricture.  
 \* Percentages are given for totals of > 12, otherwise absolute numbers are given.



**Figure 1** A bar chart summarising the data in Table 1.

degree of incontinence [4]. Several review articles did not support open suture realignment due to the increased risk of incontinence [4,42]. However, this detrimental effect was seen for primary suture realignment, with a 21% rate of incontinence after open suture realignment,

compared with 4% for STDU and 5% for EPR [4]. The results in this review were based on small series, and a variation of open techniques. Table 1 shows that the rate of incontinence is similar between EER, EPR and STDU, at 5.8%, 4.7% and 5.0%, respectively



**Figure 2** Endoscopic realignment with retrograde rigid urethroscopy and flexible antegrade urethroscopy. With permission from [50].

( $P = 0.73$ ). This is probably partly due to the minimal manipulation with current open and endoscopic realignment techniques.

### *Stricture*

Johanson [11] was the first to accept that an early suprapubic tube leads to inevitable stricture formation. This has remained true through the modern era. The potential advantages of STDU were really to avoid the risk of incontinence and ED with EPR techniques. As shown above, the chance of this is equal between EPR and EER. However, the stricture rate remains very high for STDU compared with that of EER and EPR, at 89.0%, 43.8% and 48.9%, respectively ( $P < 0.01$ ).

Other potential benefits of EPR vs. STDU include a more rapid return to spontaneous voiding [26]. In addition, Kulkarni et al. [46] reported on their experience, in the developing vs. developed world, of the acute management of PFUI. They reported higher rates of suprapubic tube placement in patients in India than in Italy (80% vs. 50%, respectively) and subsequently higher rates of complex strictures in patients in India than in Italy (85% vs. 32%, respectively), and finally the management of the stricture was easier in the Italian population, with 28% treated successfully with endoscopic treatment, compared to 1% in the Indian group [46]. The authors support early urological evaluation and EPR as likely contributors to the decreased rates of complex strictures.

Several authors have also shown that the strictures after EPR can often be treated successfully with dilatation and direct visual internal urethrotomy alone vs. open repair [21,26,32,36]. Koraitim [47] recently showed that those with primary realignment were found to have fewer abdomino-perineal repairs required than those with only a suprapubic tube (24% vs. 42%), and also had shorter defects.

### *Other complications*

Direct complications from realignment have been reported in very few patients. Pelvic abscess occurred

in one of 43 (3%) patients in one study [48], and there are two reports of perineal abscess in one of six [41] and one of four patients [33]. A urethral fistula was detected in one of 14 patients in another study [14]. Septicaemia was a complication in 15% of patients with delayed realignment, with a mean time of placement of 10 days [27].

### *Technique*

#### *Primary endoscopic realignment*

Once the PFUI is diagnosed most authors still attempt a single, gentle catheter placement at the bedside or in the operating room, by a urologist [24,38,39]. If this fails, then there are various endoscopic techniques available. Many authors favour retrograde flexible cystoscopy [20,24,26] after failing to place a catheter. Next, either rigid or flexible cystoscopy can be done simultaneously through a cystostomy and through the urethra [15,20,24] whilst the two operators move towards each other until one cystoscope passes the defect so that a wire can be placed to allow the placement of a retrograde council-tip catheter (Fig. 2) [50].

The success rates of endoscopic realignment are excellent, at 72–100% [26,29,30,32]. More experience improves success, and one group initially reported an 80% success [49] then later a 93% success rate [27] with more experience.

Other techniques include magnetic catheters [16], interlocking sounds [39], passing a wire [14] or feeding tube [32,40], or an antegrade catheter placed through a suprapubic tract [38] across the defect. Radiographic techniques have also been described [36].

#### *Timing of catheter placement*

Most authors recommend attempting to place the catheter as soon as it is feasible. Some authors suggest that if the initial attempt is unsuccessful, then simply leave a suprapubic tube and try again after 2–3 days [24]. Delayed placement has been successful as late as 10–19 days after injury [27,40].

### When to remove the catheter

Authors do not agree on the duration of catheterisation after early primary realignment, and values range from 3 to 8 weeks [39,40,48]. A reasonable approach might be to take a peri-catheter retrograde urethrogram or immediate retrograde urethrogram at the time of catheter removal, after at least 3 weeks for partial disruption, and 6 weeks for complete disruption [29]. With extravasation, the catheter is left in place or replaced and tested again every week until there is no extravasation.

### STDU

The suprapubic tube can initially be placed via a cystostomy during an open laparotomy, or a trocar into a distended bladder, or a needle passed into the bladder, then a wire passed through the needle, and serial dilatations over the wire until a suprapubic catheter can be passed. Most authors endorse a 3–6-month period of healing before an attempt at delayed urethroplasty [51]. In experienced hands, the long-term success rates are 90–98% [52–57].

### Conclusion

Whilst the rates of ED and incontinence are similar between EPR, EER and STDU, the increased rate of strictures, and more complex strictures, with STDU lead us to suggest EPR or EER as an initial approach for the immediate treatment of a PFUI. Given the ease and success of EER we prefer this to other techniques of realignment. However, as seen in Table 1 and Fig. 1, the success of EPR is equally successful in experienced hands. Lastly, not all patients can successfully undergo early realignment. STDU might be needed in the unstable patient, in complex injuries, and when attempts at early realignment fail. Fortunately, the ultimate anastomotic urethroplasty can be performed with a high chance of success in centres of excellence.

### Conflict of interest

Dr. Warner and Dr. Santucci have no conflicts of interest to report.

### Source of funding

None.

### References

- [1] Young HH. Treatment of complete rupture of the posterior urethra, recent or ancient, by anastomosis. *J Urol* 1929;**21**:41.
- [2] Clark SS, Prudencio RF. Lower urinary tract injuries associated with pelvic fractures. Diagnosis and management. *Surg Clin North Am* 1972;**52**:183–201.
- [3] Pierce Jr JM. Management of dismemberment of the prostatic-membranous urethra and ensuing stricture disease. *J Urol* 1972;**107**:259–64.
- [4] Koraitim MM. Pelvic fracture urethral injuries: the unresolved controversy. *J Urol* 1999;**161**:1433–41.
- [5] Coffield KS, Weems WL. Experience with management of posterior urethral injury associated with pelvic fracture. *J Urol* 1977;**117**:722–4.
- [6] Weems WL. Management of genitourinary injuries in patients with pelvic fractures. *Ann Surg* 1979;**189**:717–23.
- [7] Ormond JK, Cothran RM. A Simple method of treating complete severance of the urethra complicating fractures of the pelvis. *JAMA* 1934;**102**:2180–1.
- [8] DeWeerd JH. Immediate realignment of posterior urethral injury. *Urol Clin North Am* 1977;**4**:75–80.
- [9] Ragde H, McInnes GF. Transpubic repair of the severed prostatomembranous urethra. *J Urol* 1969;**101**:335–7.
- [10] Al-Ali IH, Husain I. Disrupting injuries of the membranous urethra – the case for early surgery and catheter splinting. *Br J Urol* 1983;**55**:716–20.
- [11] Johanson B. The reconstruction in stenosis of the male urethra. *Z Fur Urologie* 1953;**46**:361–75.
- [12] Turner-Warwick R. Prevention of complications resulting from pelvic fracture urethral injuries – and from their surgical management. *Urol Clin North Am* 1989;**16**:335–58.
- [13] Guille F, Cipolla B, Leveque JM, Guirassy S, Olivo JF, Lobel B. Early endoscopic realignment of complete traumatic rupture of the posterior urethra. *Br J Urol* 1991;**68**:178–80.
- [14] Cohen JK, Berg G, Carl GH, Diamond DD. Primary endoscopic realignment following posterior urethral disruption. *J Urol* 1991;**146**:1548–50.
- [15] Gheiler EL, Frontera JR. Immediate primary realignment of prostatomembranous urethral disruptions using endourologic techniques. *Urology* 1997;**49**:596–9.
- [16] Porter JR, Takayama TK, Defalco AJ. Traumatic posterior urethral injury and early realignment using magnetic urethral catheters. *J Urol* 1997;**158**:425–30.
- [17] Quint HJ, Stanisis TH. Above and below delayed endoscopic treatment of traumatic posterior urethral disruptions. *J Urol* 1993;**149**:484–7.
- [18] Rehman J, Samadi D, Ricciardi Jr R, Kreutzer E. Early endoscopic realignment as primary therapy for complete posterior urethral disruptions. *J Endourol/Endourol Soc* 1998;**12**:283–9.
- [19] Jepson BR, Boullier JA, Moore RG, Parra RO. Traumatic posterior urethral injury and early primary endoscopic realignment: evaluation of long-term follow-up. *Urology* 1999;**53**:1205–10.
- [20] Kielb SJ, Voeltz ZL, Wolf JS. Evaluation and management of traumatic posterior urethral disruption with flexible cystourethroscopy. *J Trauma* 2001;**50**:36–40.
- [21] Moudouni SM, Patard JJ, Manunta A, Guiraud P, Lobel B, Guille F. Early endoscopic realignment of post-traumatic posterior urethral disruption. *Urology* 2001;**57**:628–32.
- [22] Ku J, Kim ME, Jeon YS, Lee NK, Park YH. Management of bulbous urethral disruption by blunt external trauma: the sooner, the better? *Urology* 2002;**60**:579–83.
- [23] Tazi H, Ouali M, Lrhorfi MH, Moudouni S, Tazi K, Lakrissa A. Endoscopic realignment for post-traumatic rupture of posterior urethra. *Progres En Urologie: J L'Assoc Francaise D'urologie de Societe Francaise D'urologie* 2003;**13**:1345–50.
- [24] Mouraviev VB, Coburn M, Santucci RA. The treatment of posterior urethral disruption associated with pelvic fractures: comparative experience of early realignment versus delayed urethroplasty. *J Urol* 2005;**173**:873–6.
- [25] Healy CE, Leonard DS, Cahill R, Mulvin D, Quinlan D. Primary endourologic realignment of complete posterior urethral disruption. *Irish Med J* 2007;**100**:488–9.

- [26] Hadjizacharia P, Inaba K, Teixeira PG, Kokorowski P, Demetriades D, Best C. Evaluation of immediate endoscopic realignment as a treatment modality for traumatic urethral injuries. *J Trauma* 2008;**64**:1443–9.
- [27] Olapade-Olaopa EO, Atalabi OM, Adekanye AO, Adebayo SA, Onawola KA. Early endoscopic realignment of traumatic anterior and posterior urethral disruptions under caudal anaesthesia – a 5-year review. *Int J Clin Prac* 2010;**64**:6–12.
- [28] Sofer M, Mabweesh NJ, Ben-Chaim J, Aviram G, Bar-Yosef Y, Matzkin H, et al. Long-term results of early endoscopic realignment of complete posterior urethral disruption. *J Endourol/Endourol Soc* 2010;**24**:1117–21.
- [29] Leddy LS, Vanni AJ, Wessells H, Voelzke BB. Outcomes of endoscopic realignment of pelvic fracture associated urethral injuries at a level I trauma center. *J Urol* 2012;**188**:174–8.
- [30] Kim FJ, Pompeo A, Sehr D, Molina WR, Mariano da Costa C, Juliano C, et al. Early effectiveness of endoscopic posterior urethra primary alignment. *J Trauma Acute Care Surg* 2013;**75**:189–94.
- [31] Husmann DA, Wilson WT, Boone TB, Allen TD. Prostatomembranous urethral disruptions. management by suprapubic cystostomy and delayed urethroplasty. *J Urol* 1990;**144**:76–8.
- [32] Herschorn S, Thijssen A, Radomski SB. The value of immediate or early catheterization of the traumatized posterior urethra. *J Urol* 1992;**148**:1428–31.
- [33] Follis HW, Koch MO, McDougal WS. Immediate management of prostatomembranous urethral disruptions. *J Urol* 1992;**147**:1259–62.
- [34] Koraitim MM. Pelvic fracture urethral injuries. evaluation of various methods of management. *J Urol* 1996;**156**:1288–91.
- [35] Kotkin L, Koch MO. Impotence and incontinence after immediate realignment of posterior urethral trauma: result of injury or management? *J Urol* 1996;**155**:1600–3.
- [36] Londergan TA, Gundersen LH, van Every MJ. Early fluoroscopic realignment for traumatic urethral injuries. *Urology* 1997;**49**:101–3.
- [37] Podesta ML, Medel R, Castera R, Ruarte A. Immediate management of posterior urethral disruptions due to pelvic fracture: therapeutic alternatives. *J Urol* 1997;**157**:1444–8.
- [38] Elliott DS, Barrett DM. Long-term followup and evaluation of primary realignment of posterior urethral disruptions. *J Urol* 1997;**157**:814–6.
- [39] Asci R, Sarikaya S, Buyukalpelli R, Saylik A, Yilmaz AF, Yildiz S. Voiding and sexual dysfunctions after pelvic fracture urethral injuries treated with either initial cystostomy and delayed urethroplasty or immediate primary urethral realignment. *Scand J Urol Nephrol* 1999;**33**:228–33.
- [40] Balkan E, Kilic N, Dogruyol H. The effectiveness of early primary realignment in children with posterior urethral injury. *Int J Urol* 2005;**12**:62–6.
- [41] Salehipour M, Khezri A, Askari R, Masoudi P. Primary realignment of posterior urethral rupture. *Urol J* 2005;**2**:211–5.
- [42] Webster GD, Mathes GL, Selli C. Prostatomembranous urethral injuries. A review of the literature and a rational approach to their management. *J Urol* 1983;**130**:898–902.
- [43] Dhabuwala CB, Hamid S, Katsikas DM, Pierce Jr JM. Impotence following delayed repair of prostatomembranous urethral disruption. *J Urol* 1990;**144**:677–8.
- [44] Narumi Y, Hricak H, Armenakas NA, Dixon CM, McAninch JW. MR imaging of traumatic posterior urethral injury. *Radiology* 1993;**188**:439–43.
- [45] Armenakas NA, McAninch JW, Lue TF, Dixon CM, Hricak H. Posttraumatic impotence. Magnetic resonance imaging and duplex ultrasound in diagnosis and management. *J Urol* 1993;**149**:1272–5.
- [46] Kulkarni SB, Barbagli G, Kulkarni JS, Romano G, Lazzeri M. Posterior urethral stricture after pelvic fracture urethral distraction defects in developing and developed countries, and choice of surgical technique. *J Urol* 2010;**183**:1049–54.
- [47] Koraitim MM. Effect of early realignment on length and delayed repair of postpelvic fracture urethral injury. *Urology* 2012;**79**:912–5.
- [48] Patterson DE, Barrett DM, Myers RP, DeWeerd JH, Hall BB, Benson Jr RC. Primary realignment of posterior urethral injuries. *J Urol* 1983;**129**:513–6.
- [49] Olapade-Olaopa EO, Adebayo SA, Atalabi OM, Popoola AA, Ogunmodede IA, Enabulele UF. Rigid retrograde endoscopy under regional anaesthesia. A novel technique for the early realignment of traumatic posterior urethral disruption. *Afr J Med Med Sci* 2002;**31**:277–80.
- [50] Hohenfellner M, Santucci RA, editors. *Emergencies in Urology*. Springer Verlag; 2007.
- [51] Chapple C, Barbagli G, Jordan G, Mundy AR, Rodrigues-Netto V, Pansadoro V, et al. Consensus statement on urethral trauma. *BJU Int* 2004;**93**:1195–202.
- [52] Hosseini SJ, Rezaei A, Mohammadhosseini M, Rezaei I, Javanmard B. Supracrural rerouting as a technique for resolution of posterior urethral disruption defects. *Urol J* 2009;**6**:204–7.
- [53] Morey AF, McAninch JW. Reconstruction of posterior urethral disruption injuries: outcome analysis in 82 patients. *J Urol* 1997;**157**:506–10.
- [54] Cooperberg MR, McAninch JW, Alsikafi NF, Elliott SP. Urethral reconstruction for traumatic posterior urethral disruption. outcomes of a 25-year experience. *J Urol* 2007;**178**:2006–10.
- [55] Kizer WS, Armenakas NA, Brandes SB, Cavalcanti AG, Santucci AF, Morey AF. Simplified reconstruction of posterior urethral disruption defects: limited role of supracrural rerouting. *J Urol* 2007;**177**:1378–81.
- [56] Koraitim MM. Transpubic urethroplasty revisited: total, superior, or inferior pubectomy? *Urology* 2010;**75**:691–4.
- [57] Lumen N, Hoebcke P, Troyer BD, Ysebaert B, Oosterlinck W. Perineal anastomotic urethroplasty for posttraumatic urethral stricture with or without previous urethral manipulations. a review of 61 cases with long-term followup. *J Urol* 2009;**181**:1196–200.