



Enterolithiasis in a 15 Year Old Dongola Breed Stallion

**D. O. Omoniwa¹, B. A. Alaba², R. O. Okeke³, W. A. Adanu⁴, J. J. Kalang¹,
O. O. Oladipo⁵ and R. A. M. Adedokun²**

¹*Department of Veterinary Medicine, Surgery and Radiology, Faculty of Veterinary Medicine, University of Jos, Nigeria.*

²*Department of Veterinary Medicine, University of Ibadan, Ibadan, Nigeria.*

³*Department of Animal Science, Ahmadu Bello University, Nigeria.*

⁴*Department of Public Health and Preventive Medicine, Faculty of Veterinary Medicine, University of Jos, Nigeria.*

⁵*Biochemistry Division, National Veterinary Research Institute, Vom, Plateau State, Nigeria.*

Authors' contributions

This work was carried out in collaboration among all authors. All authors read and approved the final manuscript.

Article Information

DOI: 10.9734/JEAI/2021/v43i530683

Editor(s):

- (1) Prof. Rusu Teodor, University of Agricultural Sciences and Veterinary Medicine Cluj-Napoca, Romania.
(2) Dr. Lixiang Cao, Sun Yat-sen University, China.

Reviewers:

- (1) Amir Hossan Shaikat, Chattogram Veterinary and Animal Sciences University, Bangladesh.
(2) Dhruv Desai, Navsari Agricultural University, India.

Complete Peer review History: <http://www.sdiarticle4.com/review-history/70913>

Case Study

Received 25 April 2021

Accepted 05 July 2021

Published 05 July 2021

ABSTRACT

Equine enteroliths are mineral accumulations of magnesium-ammonium-phosphate (struvite) around a foreign object that form round, triangular, or flat stones inside the bowel usually over the course of multiple years. They form in the large colon of horses where they can remain for some time until they move and cause an obstruction in the large or small colon, resulting in colic. A 15year old Dongola stallion was presented with a bout of colic, history revealed that the horse repeatedly had been having recurrent bouts of colic. The animal was not responding to treatment rather it was getting worse. The horse died before surgical intervention could be carried out. At post mortem twenty enteroliths were discovered in the colon.

Keywords: Equine; enterolith; colic.

1. INTRODUCTION

Enterolithiasis is a term applied to calculi that form within the intestinal lumen, it is common in horses but rare in humans. The first reported case of enteroliths was by Chomelin in 1710 [1,2]. Enteroliths are also known as intestinal stones. These stones build up in thin layers around a bit of foreign matter (small piece of wood, wire, nail, or other material) that the horse has ingested [3].

Enteroliths are composed of struvite (magnesium ammonium phosphate hexahydrate) that forms in the ampulla coli of the right dorsal colon and subsequently cause partial or total obstruction of the right dorsal, transverse or descending colon [4]. The specific pathogenesis of enterolith formation is unclear but hypotheses as to the contributing factors to their formation exist and they include: excessive consumption of dietary magnesium (Mg), phosphorus (P), nitrogen (N), presence of a nidus, alkaline colonic content, breed, hypomotility of the right dorsal colon and cationic content of the water supply [5]. The enteroliths grow outward from a central core, or nidus. The nidus is usually a rock fragment, but can be other material, that acts as a nucleation center for crystal growth. As the enterolith grows outward, the crystals form concentric bands similar to those observed in geological mineral concretions [6]. The rate of formation seems to be variable and may be affected by pH, mineral availability, and colonic motility. Due to certain breed predilections and a familial trend for developing enterolithiasis, a genetic component affecting colonic motility, colonic pH, colonic mineral content, or digestive enzymes has been hypothesized (Yarbrough et al., 1994). There have been earlier reports of enterolithiasis in horses with analysis of the mineral contents of the enteroliths with reported higher levels of calcium, phosphorus, magnesium [7]. Hassel et al., [8] also had analyzed enteroliths previously and found calcium, phosphorus and magnesium to be much higher in enteroliths than in the ingesta of apparently normal horses.

Enterolithiasis is characterized by mild to moderate to severe intermittent bouts of colic with progressive anorexia and depression [3]. A definitive diagnosis of enterolithiasis can be made via abdominal radiography, explorative celiotomy, rectal palpation or necropsy [4]. The

intent of this report was to determine the mineral contents of the enteroliths.

2. CASE HISTORY

On the 16/10/2016 a client invited clinicians at the Veterinary Clinic of the Force Animal Branch, Nigeria Police Force, Ibadan Oyo State on an ambulatory visit to examine 15 year-old Dongola breed stallion. The chief complains were abdominal pain, recumbence, anorexia and cessation of defecation. The horse was immediately hoisted to its feet. History revealed that the horse had been basically tied to a stake for the past 2 years as it was no longer ridden, and had been fed on a diet of hay, wheat bran and brewer's yeast. On physical examination the vital parameters were temperature: 38.6°C, pulse: 96beats/min, respiratory rate: 38cycles/min. The mucous membranes were congested and other observations were weakness, emaciation, stretching of the limbs, spraying of urine on its thighs as it did not protrude its penis and sweating. History revealed that this horse had been having intermittent bouts of colic but the previous bouts of colic were mild. A rectal palpation was done to search for any obstructions but none was found and the rectum was found empty. The vital parameters of the horse were not improving and therefore, decision for surgery was made. While preparations for surgery were on going the horse died shortly. The post mortem was carried out and the following were found; emaciation, prominent ribs and spinous process, little subcutaneous fat, petechial hemorrhage of the trachea, yellow chicken fat around the heart, blood clots in both right and left ventricles of the heart, petechial hemorrhage in the abomasum, presence of twenty enteroliths of varying shapes in the colon and a distended bladder and a rupture of the right dorsal colon. The enteroliths removed were hard and of varying sizes, including, spherical, cuboidal, tetrahedral, and hexagonal shapes. The enteroliths had a total weight of 483g and an average weight of 24.15 ±4.03g, and average measurement of 3.24±0.96cm x 2.61±0.54cm x 2.46±0.67cm. The enterolith was subjected to elemental analysis using x-ray fluorescence spectrophotometer Philip PW 1210 Model TEFA ORTEC automatic X-ray F (Philips Analytical, Almelo, Netherlands). The specimens were exposed to the entire spectrum of photons consisting of primary radiations emitted from a standard X-ray tube. These irradiated specimen

causing the elements in it to emit secondary fluorescence with their characteristics X-ray line spectra. The energies and intensities of the emitted lines were determined by the detection system. This is made up of two units; the primary channel simultaneous wavelength dispersive spectrometer and the personal computer for control and data processing. The rapid detection system employs pre-positioned (analyzing) crystal around the specimen. These cause the dispersion of the wavelength of the secondary radiation. The intensities of the individual wavelength are measured in a mass gas flow detector. This system allows simultaneous measurements of up to ten elements at peak and background positions. The output signals from the detector were fed into the analyzer, where

the photon counts were stored in the computer memories. The count rate was calibrated for each element by comparing it to the count rate from a standard of accurately pre-determined composition. The spectral line energies of wavelengths of the emitted lines were used in the quantitative analysis of the element in the specimen. The intensities of the emitted line were related to their concentration for quantitative analysis. The following results were obtained.

The enteroliths were further analysed for radionuclides using a Gamma spectrometry (HPGe Detector) at the environmental laboratory of the National Institute of Radiation Protection and Research, the result were as.

Table 1. Elemental concentrations

Element	Bi	Cu	Cr	Ni	Zn	Co	Cs	Pb	As	Cd	Ra	Ac
Conc (ppm)	10.61	22.30	22.40	21.52	10.42	12.18	10.00	4.45	2.25	0.21	0.03	0.01

Table 2. Concentration of oxides

Oxide	SiO ₂	Al ₂ O ₃	Fe ₂ O ₃	TiO ₂	CaO	P ₂ O ₅	K ₂ O	MnO	MgO	Na ₂ O	LOI
Conc %	54.20	4.30	5.76	1.13	24.30	0.54	4.30	0.07	3.00	2.30	0.04

Table 3. Proximate analysis of the enteroliths was carried out with the following results per 100g

Sample	Moisture	Crude Protein	Crude Fibre	Lipid	Ash	NFE	Calcium	Phosphorus
Enterolith	7.89	27.09	4.60	0.10	53.15	61.35	4.38	1.76

Table 4.

Radionuclide	K-40	Ra-226	Pb-212	Bi-212	Ac-228	Tl-208	Pb-214	Pa-234	Bi-214	Cs-137
Radioactivity (Bq/kg)	667.20 ±36.61	234.69 ±20.57	161.51± 10.65	162.61 ±18.08	152.89 ±13.32	141.2 5±11.36	113.97 ±6.21	106.99 ±53.61	86.43± 13.65	0.48± 0.17




Fig. 1. The dead horse

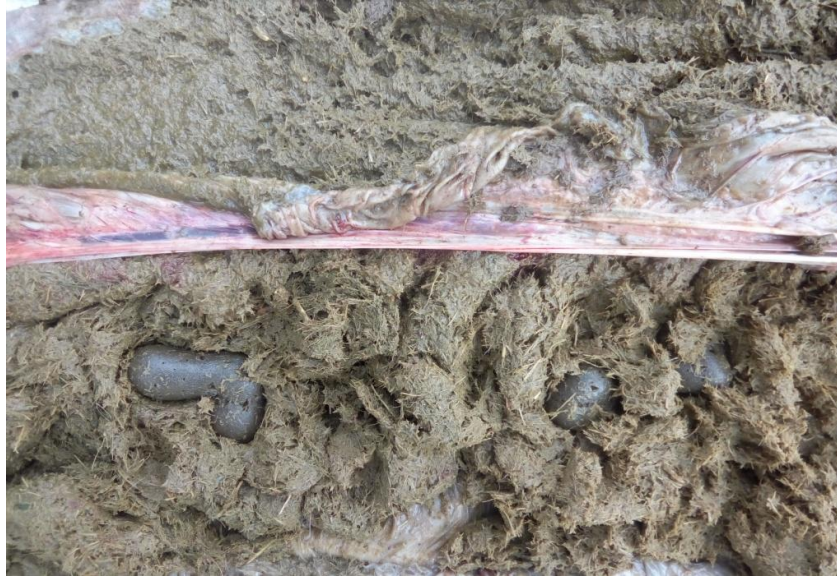

Fig. 2. Enteroliths in situ



Fig. 3. The enteroliths removed at post mortem, total weight of 483g, average weight of 24.15g, and average measurement of 3.24cm x 2.61cm x 2.46cm

3. DISCUSSION

Enteroliths are a prominent cause of equine colic and have been demonstrated as a cause of small and large colonic obstruction [9]. A presumptive diagnosis of enterolithiasis is based on signalment and a thorough history in regions in which this condition occurs frequently. A

definitive diagnosis of enterolithiasis can be made using abdominal radiography, performing exploratory celiotomy or necropsy, or occasionally on rectal palpation. Rectal palpation findings are generally inconclusive as the enterolith is rarely palpable [4]. Enteroliths occur in older horses with the average age to be 9.75 ± 4.09 years [10], this agrees with our finding

in this case where the horse was aged 15years. Multiple enteroliths are a common finding in equines [9], other researchers have reported horses with between 2 and 40 enteroliths in the large intestine (Yarbrough et al., 1994).Solitary enteroliths are usually round, whereas multiple enteroliths have flat sides [11] similar to our findings.Wheat bran has been reported to influence the formation of enteroliths by alkalinizing the intestinal ingesta, which favours the concretion of enteroliths [12], hence diet in the horse was a risk factor. Mineral content of enteroliths are varied depending on the components, silica has been identified as a common component of the nidus formation. Additionally, variable quantities of potassium, calcium, sodium, and sulfur may also be present in stones. Calcium happens to be quite abundant in colonic fluids, but magnesium may be the more critical mineral required for enterolith formation in horses [13].

4. CONCLUSION

Equine enterolithiasis is an under reported cause of colic and depending on the size of the enterolith, the symptoms displayed by the animal will vary from mild in cases of small sized enteroliths to severe in cases of a single large obstructing enteroliths or multiple smaller sized enteroliths. In this case age and overgrazing of the horse around its place of tethering contributed to the enterolithiasis as supported by the high silica content of the enteroliths. The client was advised to stable his horses and when their tethering points should be regularly rotated to prevent overgrazing and ingestion of sand.

ETHICAL APPROVAL

Animal Ethic committee approval has been taken to carry out this study.

COMPETING INTERESTS

Authors have declared that no competing interests exist.

REFERENCES

1. Gurvits GE, Lan G. Enterolithiasis. World Journal of Gastroenterology. 2014 ;20(47):17819–17829. Available:https://doi.org/10.3748/wjg.v20.i4.7.17819
2. Shrestha AL, Shrestha P. Recurrent enterolithiasis small bowel obstruction: A

- case seldom described. Case Reports in Gastrointestinal Medicine. 2017;1–4. Available:https://doi.org/10.1155/2017/4684182
3. Bhatt P, Tufani NA, Kumar T. Energy dispersive spectrophotometry based quantitative elemental estimation of equine enterolith. Indian Journal of Animal Research. 2017;51(1):193–196. Available:https://doi.org/10.18805/ijar.v0i0.F.6995
4. Hassel DM. Enterolithiasis. Clinical Techniques in Equine Practice. 2002 ;1(3):143–147. Available:https://doi.org/10.1053/ctep.2002.35576
5. Shetty K, Sridhar A. An unusual presentation of enterolithiasis. Journal of Gastrointestinal and Liver Diseases. 2011 ;20(4):348.
6. Rouff AA, Lager GA, Arrue D, Jaynes J. Trace elements in struvite equine enteroliths: Concentration, speciation and influence of diet. Journal of Trace Elements in Medicine and Biology. 2018 ;45:23–30. Available:https://doi.org/10.1016/j.jtemb.2017.09.019
7. Blue MG. Enteroliths in horses—a study of 30 cases. Equine Veterinary Journal. 1979 ;11(2):76–84
8. Hassel DM, Rakeshaw PC, Gardner IA, Spier SJ, Snyder JR. Dietary risk factors and colonic pH and mineral concentrations in horses with enterolithiasis. Journal of Veterinary Internal Medicine. 2004 ;18:346–349
9. Colgan SA, Wright JD, Gaven P. Multiple colonic enteroliths in an arabian gelding with chronic intermittent colic. Australian Veterinary Journal. 1997;75(2):100–101. Available:https://doi.org/10.1111/j.1751-0813.1997.tb14166.x
10. Lee KH, Lee H, Choi E, Baik K, Hwang J, So B. Case report : Colonic enterolith in an 11-year-old Pony. Journal of the Preventive Veterinary Medicine. 2015 ;39(1):27–28. Available:https://doi.org/10.13041/jpvm.2015.39.1.27
11. Bray RE. Enteroliths: Feeding and management recommendations. Journal of Equine Veterinary Science. 1995 ;15(11):474–478.

- Available:[https://doi.org/10.1016/S0737-0806\(06\)81820-4](https://doi.org/10.1016/S0737-0806(06)81820-4)
12. Cohen ND, Vontur CA, Rakestraw PC. Risk factors for enterolithiasis among horses in Texas. *Journal of the American Veterinary Medical Association*. 2000 ;216(11):1787–1794.
- Available:<https://doi.org/10.2460/javma.2000.216.1787>
13. Taylor KS, Faure G. Geochemical study of an equine enterolith, medina county, Ohio. *The Ohio Journal of Science*. 1983 ;83(1):54–59.
- Available:<http://hdl.handle.net/1811/22910>

© 2021 Omoniwa et al.; This is an Open Access article distributed under the terms of the Creative Commons Attribution License (<http://creativecommons.org/licenses/by/4.0>), which permits unrestricted use, distribution, and reproduction in any medium, provided the original work is properly cited.

Peer-review history:
The peer review history for this paper can be accessed here:
<http://www.sdiarticle4.com/review-history/70913>