



Transient Biventricular Dysfunction Following Pericardiocentesis for Cardiac Tamponade

M. Akrim^{a*}, B. Dihy^a, M. Camara^a, M. El Jamili^a, S. El Karimi^a, D. Benzarouel^a
and M. El Hattaoui^a

^a Cardiology Department, Mohammed VI University Hospital, Marrakech Morocco.

Authors' contributions

This work was carried out in collaboration among all authors. All authors read and approved the final manuscript.

Article Information

DOI: 10.9734/IJMPCR/2022/v15i330156

Open Peer Review History:

This journal follows the Advanced Open Peer Review policy. Identity of the Reviewers, Editor(s) and additional Reviewers, peer review comments, different versions of the manuscript, comments of the editors, etc are available here: <https://www.sdiarticle5.com/review-history/85913>

Case Study

Received 02 February 2022

Accepted 11 April 2022

Published 15 April 2022

ABSTRACT

Pericardial decompression syndrome (PDS) is an unusual, potentially fatal complication that occurs after pericardial drainage for cardiac tamponade. either by needle pericardiocentesis or surgical pericardiostomy. It manifests with paradoxical hemodynamic deterioration and/or pulmonary edema, commonly associated with ventricular dysfunction. PDS usually begins after initial clinical amelioration after pericardiocentesis. It is largely under-reported and may be neglected in clinical practice. While the precise mechanisms behind PDS are not well understood, it seems to be strongly related to patients with preexisting ventricular dysfunction. Doctors who perform pericardial drainage should be mindful of the associated high-risk factors for the intervention, taking into consideration the uncommon possibility of PDS formation.

Keywords: *Pericardial decompression syndrome; cardiac tamponade; post-pericardial drainage low cardiac output syndrome; paradoxical hemodynamic instability.*

1. INTRODUCTION

Cardiac tamponade is a medical emergency that restricts the filling of the heart chambers and

alters normal hemodynamic conditions, resulting in cardiogenic shock and hypotension. It happens after a quick or overflow of fluid into the pericardium cavity [1].

*Corresponding author: E-mail: akrim.med@gmail.com;

Pericardial decompression syndrome also known as post-pericardial drainage low cardiac output syndrome is defined as a paradoxical worsening of hemodynamics and development of pulmonary edema after uneventful pericardial drainage in patients with cardiac tamponade [2].

Pericardial drainage, by either pericardiocentesis or pericardiotomy, is vital in making patients hemodynamically stable, but has been associated with numerous complications, including one very rare, underappreciated, and life-threatening complication known as pericardial decompression syndrome (PDS) [3].

PDS usually occurs after clinical improvement following pericardiocentesis. It is largely unrecognized and may go unnoticed in daily practice.

2. CASE REPORT

We report the case of a 38-year-old woman with no history of significant cardiovascular disease. She had a previous history of metastatic breast cancer and was treated with mastectomy for triple-negative SBR II invasive ductal carcinoma. Six months later she presented to the emergency department with dyspnea that had been progressively worsening over the previous two weeks and discomfort in the inferior chest.

Her physical checkup showed jugular venous distension, hypotension (blood pressure 80/50

mmHg), tachycardia (heart rate 172 beats/min), and dull heart sounds.

Her electrocardiogram revealed sinus tachycardia with diffuse low-complexity electrical alternation and QRS voltage, and flat T waves (Fig. 1). Her chest x-ray demonstrated an expanded cardiac silhouette with a right pleural effusion. Transthoracic echocardiography showed a widespread pericardial effusion (53 mm in the posterior wall, 31 mm in the anterior wall) with a fluttering heart. Global and regional contractility was maintained and left ventricular ejection fraction (LVEF) was preserved (FigS 2-3-4).

An emergency pericardiocentesis was done and 1500 ml of serosanguinous fluid was pulled out.

The pericardial drainage catheter was left in place for 1 day. The pericardial fluid was exudative. Cytological examination of the pericardial fluid detected malignant cells. The post pericardiocentesis TTE demonstrated no remaining pericardial fluid effusion with left ventricular systolic dysfunction. Her postpericardiocentesis EKG demonstrated normal sinus rhythm with no electrical alternations. Eight hours after the procedure, the patient became suddenly breathless with tachycardia, with no chest pain. TTE revealed a small pericardial effusion with no hemodynamic compromise, although we noticed that both ventricles had systolic dysfunction with an LVEF of 30%.

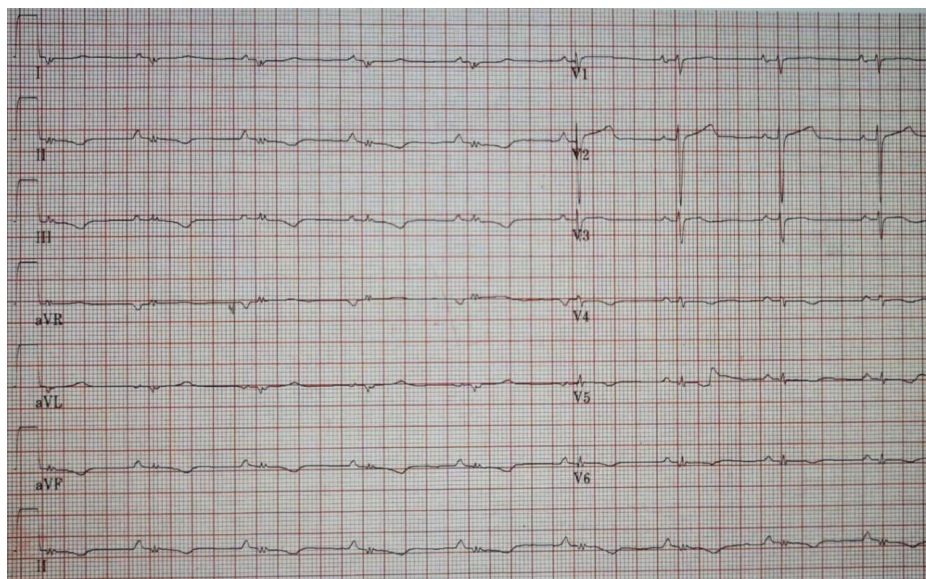


Fig. 1. Electrocardiogram showing low complex QRS voltage, and flat T waves

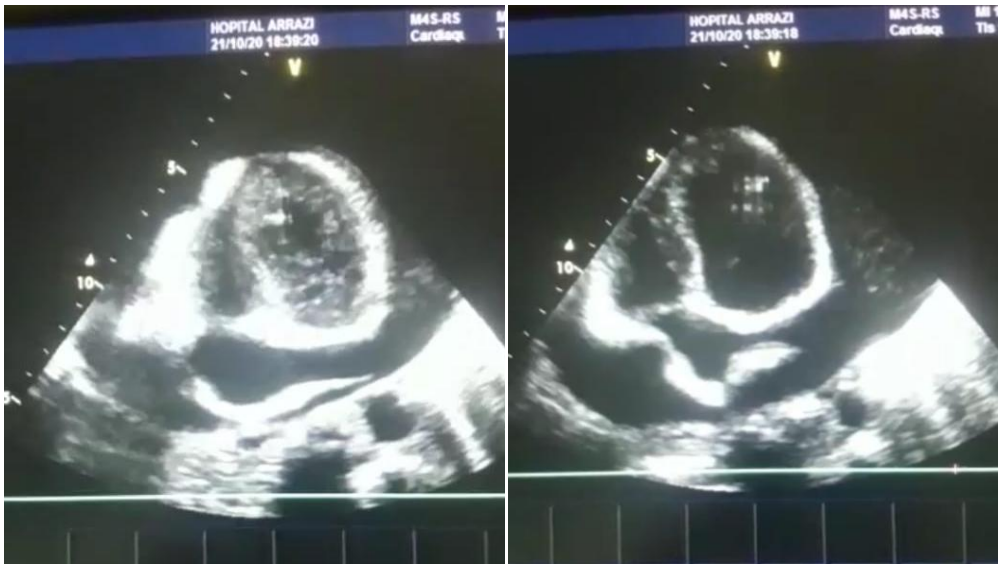


Fig. 2

Fig. 3

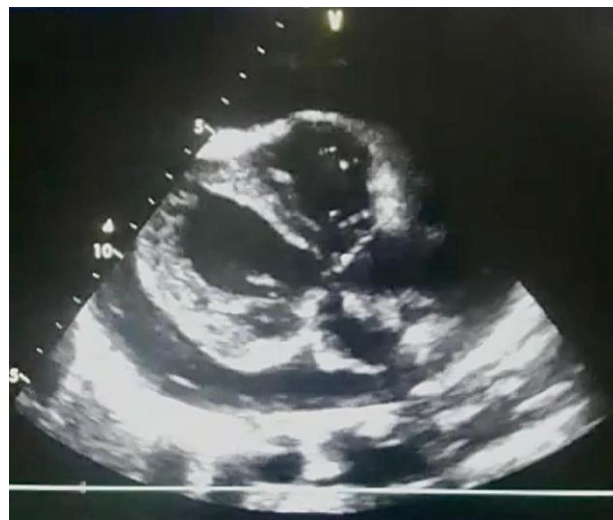

Fig. 4.

FigS. 2-3-4 : transthoracic echocardiography reveals a wide circumferential pericardial fluid effusion with evidence of right chamber compression in end-diastole

There was no physical evidence of myocardial perforation. The EKG manifested sinus tachycardia with diffuse low QRS voltage, negative T waves in the anterior leads. Troponin levels were normal. A repetitive renal workup did not show any renal failure and liver tests did show improvement in cytolysis. Instant i.v. therapy with dobutamine and furosemide 40mg daily was started with consistent clinical amelioration. Eleven days following admission, the patient was recuperating well in the cardiology department and was expressing a subjectively perceived good health. A

subsequent echocardiogram showed spectacular enhancement of contractility in both ventricles. The ventricles had both regained normal size and LVEF was 55%. Pain medication was given and the Oncology team was prepared to begin the breast cancer chemotherapy.

3. DISCUSSION

The presence of pericardial tamponade, drainage, whether performed transcutaneously or surgically, allows in the vast majority of cases an improvement in hemodynamics. Apart from the

Wolfe and Edelman noted that the abolition of the sympathetic stimulus after pericardiocentesis may result in the uncovering of a previously unrevealed background left ventricular dysfunction due to an inflated catecholaminogenic state. In addition, Martins and colleagues showed that while the administration of exogenous catecholamines raised coronary blood flow in the cardiac tamponade patients, there was no significant increase in the filling pressures and only a minor increase in the cardiac index [7].

They considered that because activation of the sympathetic nervous system was already occurring, high levels of endogenous catecholamines had no additional prospective benefit. Removal of the stimulus that leads to an enhanced sympathetic state may well give rise to the revelation of left ventricular dysfunction that was previously equilibrated by high levels of endogenous catecholamines [8].

Therefore, the sympathetic overdrive mechanism may play an integral part in the etiology of PDS, because abnormalities in left ventricular systolic function may occur after the described pericardiocentesis procedure [9].

As postpericardiocentesis ventricular dysfunction is not a common finding in the clinic, we believe that transient myocardial dysfunction after pericardial drainage is likely to happen more when a high volume of pericardial fluid is eliminated in a brief period of time, thereby suppressing rapid regulation of coronary resistance and the autonomic nervous system.

In the lack of specific treatment, the management is based mainly on an early diagnosis and the initiation of hemodynamic supportive therapy. The administration of vasopressors or inotropic therapy is usually required, and the most serious of these cases may need external circulatory support [7].

4. CONCLUSION

PDS is a phenomenon uncommon (incidence <5%) and can be observed after drainage of a pericardial effusion, regardless of the technique used.

To date, there are no clear evidence-based guidelines or recommendations for specifically preventing PDS. A reasonable approach, however, would be not to remove large amounts of pericardial fluid at one time if there is large

pericardial effusion. The approach that is most manageable would be to remove the correct amount of pericardial fluid to resolve the physiology of the cardiac tamponade (which can be obtained easily by haemodynamic or echo-Doppler monitoring) and then to place extended pericardial drainage to obtain gradual, slow removal of the extra pericardial fluid.

The Cardiologist should be conscious of this condition and be ready to deal with it in a timely manner as this diagnosis leads to a high degree of mortality, particularly after prompt surgical decompression [10].

ETHICAL APPROVAL

As per international standard or university standard written ethical approval has been collected and preserved by the author(s).

CONSENT

As per international standard or university standard, patients' written consent has been collected and preserved by the author(s).

COMPETING INTERESTS

Authors have declared that no competing interests exist.

REFERENCES

- 1 Flores VM, Pascual Figal DA, Martínez CC, Valdés-Chávarri M. Transient Left Ventricular Dysfunction Following Pericardiocentesis. An Unusual Complication to Bear in Mind. *Revista Española de Cardiología (English Edition)*. 2009;62(9):1071–1072.
- 2 Imazio M. Pericardial decompression syndrome: A rare but potentially fatal complication of pericardial drainage to be recognized and prevented. *European Heart Journal: Acute Cardiovascular Care*. 2014;4(2):121–123.
- 3 Expert Analysis. Pericardial Decompression Syndrome - American College of Cardiology April; 2020.
- 4 Vandyke WH, Cure J, Chakko CS, Gheorghide, M. Pulmonary Edema after Pericardiocentesis for Cardiac Tamponade. *New England Journal of Medicine*. 1983;309(10):595–596.
- 5 Nicolas Ropraza, médecin diplômé; Thierry Bonjourb, médecin diplômé; Dr méd.

- Aurélien Roumyc; Dr Ana Barrigon Benitezd; Dr méd. Marco Ruscae. Un drainage péricardique qui tourne mal, le syndrome de décompression myocardique. *SWISS Medical Forum – Forum Médical Suisse*. 2020;20(45–46):658–660.
- 6 Liger C, Leta R, Bayes-Genis A. Transient biventricular dysfunction following pericardiocentesis. *European Journal of Heart Failure*. 2005;8(1):102–104.
- 7 Pradhan R, Okabe T, Yoshida K, Angouras DC, DeCaro MV, Marhefka GD. Patient characteristics and predictors of mortality associated with pericardial decompression syndrome: a comprehensive analysis of published cases. *European Heart Journal: Acute Cardiovascular Care*. 2014;4(2):113.
- 8 Yougeesh Prabhakar, Amandeep Goyal, Nauman Khalid, Nitish Sharma, Raj Nayyar, David H Spodick, Lovely Chhabra. *World J Cardiol*. 2019;11(12):282–291. Published online 2019 Dec 26.
- 9 Chung J, Ocken L, Wolo E, Herman CR, Goldhammer JE. Acute Right Ventricular Failure after Surgical Drainage of Pericardial Tamponade: A Case Report of Pericardial Decompression Syndrome and Review of the Literature. *Journal of Cardiothoracic and Vascular Anesthesia*; 2018.
- 10 Chakri Yarlagadda, MD, FACC, FSCAI, FASNC, CCDS Director of Cardiac Rehabilitation, St Elizabeth Youngstown Hospital; Radiation Safety Officer, Mercy Health Cardiology ,Pericardial Effusion and Cardiac Tamponade Requiring Pericardial Window in an Otherwise Healthy 30-year-old Patient With COVID-19.

© 2022 Akrim et al.; This is an Open Access article distributed under the terms of the Creative Commons Attribution License (<http://creativecommons.org/licenses/by/4.0>), which permits unrestricted use, distribution, and reproduction in any medium, provided the original work is properly cited.

Peer-review history:

The peer review history for this paper can be accessed here:
<https://www.sdiarticle5.com/review-history/85913>