



Evaluation of Results of Internal Fixation of Base Fifth Metatarsal Fractures

**Hesham Gamal Motawea ^{a*}, Ali Mahmoud Emran ^b, Ahmed Elsayed Eltantawy ^b
and Moheb Eldeen Ahmed Fadel ^b**

^a Faculty of Medicine, Mansoura University, Mansoura, Egypt.

^b Orthopaedic Surgery Department, Faculty of Medicine, Tanta University, Tanta, Egypt.

Authors' contributions

This work was carried out in collaboration among all authors. All authors read and approved the final manuscript.

Article Information

DOI: 10.9734/JAMMR/2022/v34i1831432

Open Peer Review History:

This journal follows the Advanced Open Peer Review policy. Identity of the Reviewers, Editor(s) and additional Reviewers, peer review comments, different versions of the manuscript, comments of the editors, etc are available here: <https://www.sdiarticle5.com/review-history/87098>

Original Research Article

Received 06 March 2022

Accepted 13 May 2022

Published 02 June 2022

ABSTRACT

Background: The fifth metatarsal base fracture is a quite frequent fracture, occurring at a rate of 6 per 100,000 yearly. Fractures of the metaphyseal-diaphyseal junction (Jones fractures) have a higher rate of non-union and occasionally do require surgery. This research aimed to assess the findings of surgical treatment of a recent fracture base of 5th metatarsal in adults' zone II, III by percutaneous intramedullary cannulated cancellous screws (4 mm and 6.5mm).

Methods: This prospective case series research was involved 21 adult patients with recent trauma and closed base of 5th metatarsal fractures. All participants were subjected to laboratory study, methods of radiological evaluation [Antero-posterior aspect of the foot, oblique aspect of the foot].

Results: AOFAS score was significantly different among age groups at 2 months and insignificantly different at 6 months. AOFAS score was insignificantly different between both sexes.

Conclusions: Percutaneous intramedullary cannulated cancellous screws fixation of base 5th metatarsal fractures with a cannulated cancellous screw 4mm,6.5mm has a high union rate (100%) with early mobilization and return to work and daily activity without need to do below knee cast or slab, so it decreases post cast stiffness rate. It also increases rate of union and healing by doing compression of the fracture site using the cannulated cancellous screw and keeping hematoma without evacuation. Using of larger screws in diameter like 6.5 mm to be fit in the medulla, is more beneficial than 4 mm screws.

*Corresponding author

Keywords: Internal fixation; base fifth metatarsal; fractures.

1. INTRODUCTION

Fifth metatarsal base fractures are quite frequent, occurring at a rate of 6 per 100,000 yearly [1]. Rammelt et al. [2] indicated that it is the most prevalent mid-foot fracture. Close to 70% of metatarsal fractures occur in the 5th metatarsal and 80% of 5th metatarsal fractures occur in the proximal aspect of the bone [1, 3]. These fractures are more likely in males in their 3rd decade and females in their 7th decade, having a higher prevalence among women who have a low bone mineral density [4]. Jones fractures, which occur at the metaphyseal-diaphyseal junction, have a greater rate of non-union and can require surgery [5, 6].

Jones described a fracture originates laterally in the distal region of the tuberosity of the 5th metatarsal and expanding obliquely and proximally into the medial cortex at the junction of the metaphysis and diaphysis [7, 8].

Blood supply has a critical role in these fractures repair. Perfusion is providing from metaphyseal arteries at the base of the 5th metatarsal. A nutritional artery originates at the proximal diaphysis and travels proximally to the metaphyseal–diaphyseal junction via the so-called "watershed area [9, 10].

These fractures have been observed to possess greater rates of non-union until handled non-operatively than when handled surgically. The evidence suggests that these fractures should be treated surgically as soon as possible in high-performance athletes [11].

Different operative methods were outlined in the research involving differential pitch screw, intramedullary screw, percutaneous bi-cortical screw and tension band wiring. The most frequently described procedure is fixation with an intramedullary compression screw, either with or without bone grafts [3].

However, surgical correction is not without obstacles and could involve injury to the sural nerve and peroneus brevis tendon. Recent research indicates that intramedullary fixation significantly minimises the risk of non-union and enables faster union rates and back to daily activities [6]. The purpose of this research was to determine the outcomes of surgical treatment of a recent fracture base of 5th metatarsal in adults'

zone II, III by percutaneous intramedullary cannulated cancellous screws (4 mm and 6.5mm).

2. PATIENTS AND METHODS

This prospective case series research was included 21 adult participants in the study period (one year from February 2020 to February 2021) in the department of orthopedic Surgery in Tanta University and Mansoura general hospital. aged from 17-60 years old, both sexes, with recent trauma and closed base of 5th metatarsal fractures (Jones fractures zone II, III).

Exclusion criteria were immune compromised patients (Diabetic patient for example), hepatic comorbidity, pathological fractures, unfit for surgery, open fractures and smokers.

All cases were subjected to: personal data, complaints, history taking, examination [general and local assessment], laboratory study, methods of radiological assessment [Antero-posterior and oblique view of the foot]

Pre-operative planning: Instrument use selection between cannulated screw 4 and 6.5 mm by X-ray scan to measure distance from the base to the shaft of curvature, the metatarsal length and canal diameter.

The bone's length was determined. In the AP and Oblique views, the source of the shaft's curvature was established. The spacing between each pair of parallel lines was the same as the metatarsal canal's maximum diameter.

Surgical technique: The patient was positioned supine after application of the tourniquet. Disinfection and draping measurements were done. A 1 cm lateral incision was made above the 5th metatarsal tuberosity. A smooth guide wire will be inserted into the metatarsal styloid and advanced along the 5th metatarsal medulla barrel. On fluoroscopy, the wire will be confirmed to be in the metatarsal in both the AP and lateral views. Retraction of the tendon of peroneus brevis superiorly and a sharp cannulated 2.7 drill for 4mm screw and 3.2 for 6.5mm screw was used to make a drill hole in the tip of the tuberosity and complete through the medulla of shaft along the guide wire. Insertion of a cannulated cancellous screw on a washer. Lastly

closure of sub-cutaneous and skin layers then dressing plaster and bandage.

Post-operative management: Post-operative care and follow-up examination were performed as follow: Distal circulation and neurological status were monitored, Anti-edematous measurements and Analgesics, Leg elevation and early toe exercise were advised. Post-operative radiographs were done and discharge of the patient with ambulation on crutches and non-weight bearing for 2 weeks.

Methods of assessment of the outcomes: All the patients at the end of the six months, were assessed both clinically and radiologically.

Clinically the patient was examined for his pain state, functional abilities, and foot alignment according to:

Clinical evaluation: Modified AOFAS mid foot scale [12]: This score assigns a 45 for function, and 15 for alignment. A score of (90: 100) was graded as an excellent finding (75: 89) as good (50: 74) as fair and less than 49 points was graded as a failure. Scoring items was translated orally by researcher and according to patient answer evaluation items was fulfilled by researcher.

Radiological evaluation: plain x-ray was ordered for all patients post-operatively and at the fourth, the sixth week & then at 6 months to compare union of the bone.

2.1 Statistical Analysis

The data were entered into the computer and analysed using the IBM SPSS software version 20.0. (IBM Corporation, Armonk, New York). Qualitative data were described using numbers

and percentages. The Kolmogorov-Smirnov test was used to determine the normality of the distribution. Quantitative data were described using the range (minimum and maximum values), mean, and standard deviation. The student t-test is used to compare two groups of normally distributed quantitative data. The F-test (ANOVA) is used to compare more than two groups for normally distributed quantitative variables. Linear Correlation coefficient (r): It was used for detection of correlation between two quantitative variables in one group. A two tailed P value < 0.05 was significant.

3. RESULTS

Time to complete union was significantly change among age groups P=0.015). Relation between sex and complete union (healing time) was insignificantly different. Error! Not a valid bookmark self-reference.

In this study 4 & 6.5 cannulated cancellous screws were used, 6.5 mm screws were used for 15 patients and 4mm screws were used for 6 patients, the study the mean union time using 6.5mm screw was 5.93 weeks with ± standard deviation of ± 0.26 while the mean union time using 4mm screw was 8.33 weeks with ± standard deviation of ± 3.83 as shown in Table 2.

Table 3 shows the change in the AOFAS score of the patients over the four time points. AOFAS score was significantly different among age groups at 2 months and insignificantly different at 6 months. AOFAS score was insignificantly different between both sexes. Table 3.

Fig. 1 shows relation between complete union (healing time) with AOFAS 2 months post-operative.

Table 1. Time to complete union in different age groups and relation between sex and complete union (healing time) (n= 21)

Age groups		Complete union (healing time) (Weeks)	P value
		Group A	
18-30 Years		6.001±0.255	0.015*
31-45 Years		6.333±0.756	
46-60 Years		7.000±1.000	
Sex	Male (n = 15)	6.73 ± 2.58	0.910
	Female (n = 6)	6.33 ± 1.03	

Data are presented as mean ± SD, *: significant P value

Table 2. Distribution of the studied cases according to size of screw and Relation between size of screw and complete union (n = 21)

		Size of screw	
4 mm		6(28.6%)	
6.5 mm		15(71.4%)	
Complete union (healing time) (weeks)			P value
Size of screw	4 (n= 6)	8.33 ± 3.83	0.014*
	6.5 (n= 15)	5.93 ± 0.26	

Data are presented as mean ± SD or frequency (%), *: significant P value

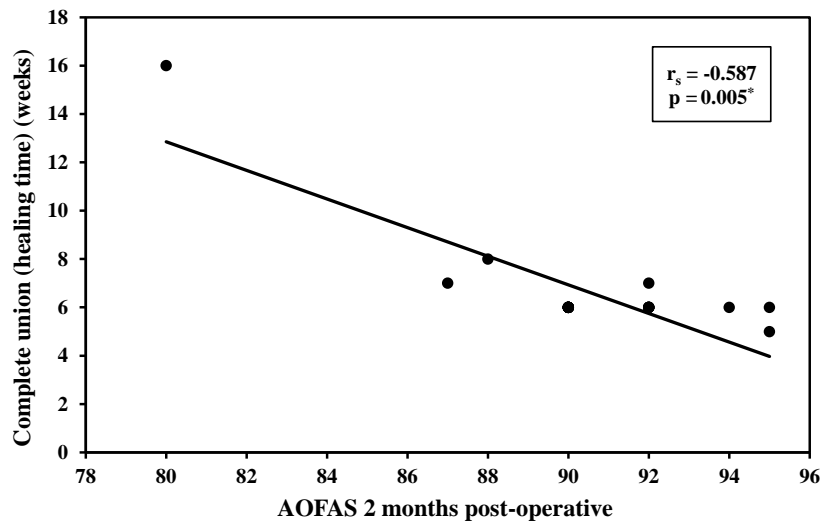


Fig. 1. Relation between complete union (healing time) with AOFAS 2 months post-operative

3. DISCUSSION

The care of a fracture at the base of the 5th metatarsal is a difficult task for an orthopaedic surgeon due to the fracture's unusual vasculature. It was demonstrated that A watershed zone at the base of the 5th metatarsal can considerably limit the rate of union, especially when non-operative therapies are used. Wang et al. [13], reported that the utilize of invasive procedures has mainly been favoured due to their capability to give a strong fixation to the fractured surfaces while keeping the retrograde blood flow to the vascular deficient areas.

Mahajan et al. [14], reported that it is essential to recognize the anatomy of the 5th metatarsal bone to manage of zone I and II fractures. The tuberosity located on the proximal portion and provided the attachment point for the peroneus brevis tendon's wide insertion. The distal part of the diaphysis is curved.

The management of fracture of 5th metatarsal varies between conservative and operative

management. Operative management distributed between intramedullary fixation and plate fixation.

Shahid et al, Gray et al and Wiener et al. [15], manage Conservative treatment may include an elastic dressing and a rigid shoe, a short leg walking cast, a posterior splint, or a hard plastic cast shoe with weight bearing as tolerated.

Clapper et al. [5], also showed 100% union rate in 7 cases that were handled surgically for Jones fractures with a mean time of healing of 12.1 weeks. The group treated non-operatively healed significantly more slowly.

Sokkar and Abdelkafy [16], found a substantial decrease in the time required to back to sport in the operative group (7.1 weeks) in comparison to the non-operative group (8.7 weeks). The authors suggested that the surgical fixation's capacity to withstand torsional strain at the fracture site while enabling equalised load dispersion may be the primary cause of early weight bearing and back to sport.

Table 3. Follow-up measures of patients' fixation and relation between the age, sex and functional end results (n=21)

Variables		Follow-up			Test of Sig.	P value
		2 months	4 months	6 months		
Post-operative AOFAS score	Functional	Age (years)				
		18 – 30(n = 12)	31 – 45(n = 7)	46 – 60(n = 2)		
AOFAS	2 months	91.25 ± 1.96	91.29 ± 1.89	83.50 ± 4.95	F=11.131*	0.001*
	6 months	100.0 ± 0.0	100.0 ± 0.0	100.0 ± 0.0	F=0.0	1.000
		Sex			Test of Sig.	P value
		Female (n = 6)		Male (n = 15)		
AOFAS		90.07 ± 3.22		91.67 ± 2.88	t= 1.058	0.303

*: significant P value

A study by Neil published in 2018 [17], compared different methods of proximal 5th metatarsal jones fracture fixation and discovered that Being used to cadaver foot specimens with simulated human fractures subjected to cantilever bending in a load frame, planter-lateral plating resulted in a greater number of cycles to failure and peak failure loads before failure, as well as a smaller gap width, than intramedullary screw fixing.

Mahajan et al. [14], found that Currently, Intramedullary fixation is the most frequently used technique for these fractures, as it travels through the proximal cortex and rests in the medullary canal.

The recently reported biomechanical studies by Husain et al. [18], bicortical screw fixation was explored as alternative way of treatment for these fractures. These studies shown positive outcomes in the treatment of zone I and zone II fractures with bicortical screw fixation. Bicortical fixation could provide firmness at the fracture place, promoting primary bone repair, while also restraining ligamentous and muscle insertion tension.

Regarding the type of fracture, the fractures type in our study were mainly type III in 11 patients (52.4%) while type II was in 10 patients (47.6%) who suffered from twisting trauma to the foot without associated injuries or neurovascular problems. Distribution of patient with Leumann, A et al from the 22 patients was Avulsion Jones fractures: 7, proximal diaphyseal stress fractures: 2 fractures: 13. While it was of the 26 fractures, 17 were traditional zone II Jones fractures, and the remaining 9 were zone III proximal diaphyseal fractures in the study of Murawski, C. D.

Cannulated cancellous screws size 4, 6.5 mm partially serrated were used in our study. Cannulated cancellous screws size 6.5mm were used for 14 patients, while 7 patients used 4 mm size. A clinical and biomechanical research performed in 2004, by Reese et al. [19], explained, When cyclic fatigue testing was performed, screws with a diameter of 6.5mm or greater outperformed those with a diameter of less than 4.0mm; titanium was less fatigue resistant than stainless steel, and cannulated screws outperformed solid screws of equal geometry.

From a biomechanical stand point Pietropali et al. [20], indicated that surgeon's preference for solid

versus cannulated screws is based on biomechanical stiffness in 4.5mm cadavers. To boost the pull-out strength, several studies propose utilising a longer or larger diameter screw for intramedullary fixation.

Regarding results, our research revealed 100% clinical union with low morbidity rate and a mean of healing time 8 weeks. Leumann, A et al. [21] followed up their patients 42 months in mean and range from 12to 68 months). At follow-up, 11 patients had great clinical outcomes, three had good outcomes, none had fair outcomes, and none had bad outcomes. In the similar condition, all individuals would consent the same surgery. Mindrebo, N et al found the average time required to resume activity was 5.5 weeks and ranged from 3 to 10weeks. Back to complete practise took an average of 7.5 weeks and ranged from 6 to 12 weeks. The mean time required to reintroduce oneself to competition was 8.5 weeks ranged from 7 to 12 weeks. At six weeks, radiographic proof of union was observed (range, 5 to 7).

Regarding complications, there was no injury of sural nerve as it was done percutaneous. Only one patient showed loosening of the screw during follow up, which was managed by immobilization using lower knee cast and non-weight bearing for 6 weeks. No re-fractures and zero incidence of screw breakage were observed. Wright et al. [22], described 6 refractures occurred after intramedullary repair of proximal 5th metatarsal fractures in athletes, despite radiographic and clinical union prior to back to complete activity. They advocated utilising a screw with a larger diameter for use in athletes and extending safety with bracing, shoe modification, or an orthosis. They also recommended doing alternative imaging to determine complete healing.

Mologne et al. [23], in a comparative study of screw fixation vs. casting in the therapy of acute jones fractures, eighteen cases received cast care and nineteen had screw fixation. The study enrolled 35 males and two females. The mean age of the participants was 25.6 years and ranged from 18 to 58 years. The average duration of follow-up was 25.3 months (15–42 months). They discovered that 8 of the 18 (44%) of patients in the cast group were regarded treatment failures: 5 were non-union, 1 was interrupted union, and 2 were refractory. One of the surgery group's 19 patients was judged a therapy failure. The median times to union and

return to sports for the surgery group was 7.5 and 8.0 weeks, respectively. The median times for the cast group were 14.5 and 15.0 weeks, respectively.

The strength of points in our study were that fixation of base fifth metatarsal fractures by intramedullary cannulated cancellous screws increase union rate by making a compression on fracture site, keeping fracture hematoma as it done percutaneous, and early ambulation two weeks post-operative, patient can return to normal walking in 8 weeks.

While weakness of points of our study was only one case of delayed union but we treated it by supplements and then the patient showed an acceptable union degree after. Also, weakness was shortening of follow up time of patients, so we couldn't see if there were other complications appeared or no.

4. CONCLUSIONS

Percutaneous intramedullary cannulated cancellous screws fixation of base fifth metatarsal fractures with a cannulated cancellous screw 4mm,6.5mm has a high union rate (100%) with early mobilization and return to work and daily activity without need to do below knee cast or slab, so it decreases post cast stiffness rate. It also increases rate of union and healing by doing compression of the fracture site using the cannulated cancellous screw and keeping hematoma without evacuation. Using of larger screws in diameter like 6.5 mm to be fit in the medulla, is more beneficial than 4 mm screws.

DISCLAIMER

The products used for this research are commonly and predominantly use products in our area of research and country. There is absolutely no conflict of interest between the authors and producers of the products because we do not intend to use these products as an avenue for any litigation but for the advancement of knowledge. Also, the research was not funded by the producing company rather it was funded by personal efforts of the authors.

CONSENT AND ETHICAL APPROVAL

Each participant signed an informed consent form. The study was done after approval from the

Ethical Committee Tanta University Hospitals (approval code: 33577/12/19).

COMPETING INTERESTS

Authors have declared that no competing interests exist.

REFERENCES

1. Petrisor BA, Ekrol I, Court-Brown C. The epidemiology of metatarsal fractures. *Foot Ankle Int.* 2006;27:172-4.
2. Rammelt S, Heineck J, Zwipp H. Metatarsal fractures. *Injury.* 2004;35 Suppl 2:Sb77-86.
3. Zwitser EW, Breederveld RS. Fractures of the fifth metatarsal; diagnosis and treatment. *Injury.* 2010;41:555-62.
4. Kane JM, Sandrowski K, Saffel H, Albanese A, Raikin SM, Pedowitz DI. The Epidemiology of Fifth Metatarsal Fracture. *Foot Ankle Spec.* 2015;8:354-9.
5. Clapper MF, O'Brien TJ, Lyons PM. Fractures of the fifth metatarsal. Analysis of a fracture registry. *Clin Orthop Relat Res.* 1995;238-41.
6. Josefsson PO, Karlsson M, Redlund-Johnell I, Wendeberg B. Jones fracture. Surgical versus nonsurgical treatment. *Clin Orthop Relat Res.* 1994;252-5.
7. Torg JS. Fractures of the base of the fifth metatarsal distal to the tuberosity. *Orthopedics.* 1990;13:731-7.
8. DeLee JC, Evans JP, Julian J. Stress fracture of the fifth metatarsal. *Am J Sports Med.* 1983;11:349-53.
9. Smith JW, Arnoczky SP, Hersh A. The intraosseous blood supply of the fifth metatarsal: implications for proximal fracture healing. *Foot Ankle.* 1992;13:143-52.
10. Donley BG, McCollum MJ, Murphy GA, Richardson EG. Risk of sural nerve injury with intramedullary screw fixation of fifth metatarsal fractures: a cadaver study. *Foot Ankle Int.* 1999;20:182-4.
11. Kelly IP, Glisson RR, Fink C, Easley ME, Nunley JA. Intramedullary screw fixation of Jones fractures. *Foot Ankle Int.* 2001;22: 585-9.
12. SooHoo NF, Vyas R, Samimi D. Responsiveness of the foot function index, AOFAS clinical rating systems, and SF-36 after foot and ankle surgery. *Foot Ankle Int.* 2006;27:930-4.
13. Wang Y, Gan X, Li K, Ma T, Zhang Y. Comparison of operative and non-operative

- management of fifth metatarsal base fracture: A meta-analysis. PLoS One. 2020;15:e0237151.
14. Mahajan V, Chung HW, Suh JS. Fractures of the proximal fifth metatarsal: percutaneous bicortical fixation. Clin Orthop Surg. 2011;3:140-6.
 15. Wiener BD, Linder JF, Giattini JF. Treatment of fractures of the fifth metatarsal: a prospective study. Foot Ankle Int. 1997;18:267-9.
 16. Sokkar SM, Abdelkafy A. Operative versus nonoperative treatment of type 1 fifth metatarsal fracture in nonprofessional athletes. Egypt orthop J. 2016;51:319-22.
 17. Duplantier NL, Mitchell RJ, Zambrano S, Stone AC, Delgado DA, Lambert BS, et al. A Biomechanical Comparison of Fifth Metatarsal Jones Fracture Fixation Methods. Am J Sports Med. 2018;46:1220-7.
 18. Husain ZS, DeFronzo DJ. A comparison of bicortical and intramedullary screw fixations of Jones' fractures. J Foot Ankle Surg. 2002;41:146-53.
 19. Reese K, Litsky A, Kaeding C, Pedroza A, Shah N. Cannulated screw fixation of Jones fractures: a clinical and biomechanical study. Am J Sports Med. 2004;32:1736-42.
 20. Pietropaoli MP, Wnorowski DC, Werner FW, Fortino MD. Intramedullary screw fixation of Jones fractures: a biomechanical study. Foot Ankle Int. 1999;20:560-3.
 21. Leumann A, Pagenstert G, Fuhr P, Hintermann B, Valderrabano V. Intramedullary screw fixation in proximal fifth-metatarsal fractures in sports: clinical and biomechanical analysis. Arch Orthop Trauma Surg. 2008;128:1425-30.
 22. Wright RW, Fischer DA, Shively RA, Heidt RS, Jr., Nuber GW. Refracture of proximal fifth metatarsal (Jones) fracture after intramedullary screw fixation in athletes. Am J Sports Med. 2000;28:732-6.
 23. Mologne TS, Lundeen JM, Clapper MF, O'Brien TJ. Early screw fixation versus casting in the treatment of acute Jones fractures. Am J Sports Med. 2005;33:970-5.

© 2022 Motawea et al.; This is an Open Access article distributed under the terms of the Creative Commons Attribution License (<http://creativecommons.org/licenses/by/4.0>), which permits unrestricted use, distribution, and reproduction in any medium, provided the original work is properly cited.

Peer-review history:

*The peer review history for this paper can be accessed here:
<https://www.sdiarticle5.com/review-history/87098>*