



Soft Tissue Plasmacytoma: Surgery, Radiotherapy or Immunochemotherapy?

**Moukrim Ilham ^{a*}, Marsafi Oussama ^b, Bazi Hamza ^c,
Abaouz Nadia Guensi Amal ^d,
Azim Meryame, Mazti Asmae ^e, Madani Abdallah ^f
and Lamchahab Mouna ^f**

^a Department of Pediatric Hematology Oncology, Hospital 20 August 1953 Casablanca, Morocco.

^b Department of Radiology, Hospital 20 August 1953 Casablanca, Morocco.

^c Department of Traumatology, CHU Ibn Rochd, Casablanca, Morocco.

^d Department of Nuclear medicine CHU Ibn Rochd Casablanca, Morocco.

^e Department of Anatomopathology, CHU Ibn Rochd, Casablanca, Morocco.

^f Department of Pediatric Hematology Oncology, Hospital 20 August 1953, Casablanca, Morocco.

Authors' contributions

This work was carried out in collaboration among all authors. All authors read and approved the final manuscript.

Article Information

Open Peer Review History:

This journal follows the Advanced Open Peer Review policy. Identity of the Reviewers, Editor(s) and additional Reviewers, peer review comments, different versions of the manuscript, comments of the editors, etc are available here: <https://www.sdiarticle5.com/review-history/112207>

Case study

Received: 15/11/2023

Accepted: 18/01/2024

Published: 19/01/2024

ABSTRACT

Soft tissue plasmacytoma is a rare tumour. It belongs to the extramedullary plasmacytomas. Diagnosis is based on biopsy, and treatment is mainly based on radiotherapy. Immunochemotherapy followed by autotransplantation, surgery are also a therapeutic arm. We present a case of plasmacytoma of fracture site of femur in a young male.

Keywords: *Soft tissue; plasmacytoma; biopsy; autotransplantation.*

*Corresponding author: E-mail: ilhamoukrim94@gmail.com;

Asian Hematol. Res. J., vol. 7, no. 1, pp. 14-19, 2024

1. INTRODUCTION

Soft-tissue plasmacytoma is a rare monoclonal proliferation of plasma cells in soft tissues or organs [1]. The relationship between multiple myeloma, solitary bone plasmacytoma and soft-tissue plasmacytoma is not well understood. For some authors, these 3 entities represent different aspects of the same disease [2]. The incidence of soft-tissue plasmacytoma at diagnosis varies from 1.7% to 4.5% [3]; with the skin being the most frequent site, followed by the liver, pleura and central nervous(CNS) [system 4]. We report an observation of soft-tissue plasmacytoma and attempt to identify the main features of this entity through a review of the literature.

2. CASE PRESENTATION

39-year-old patient with a history of a left femur fracture operated on 2013, treated with a screw-plate and orthopaedic cement. Presented a painful swelling of the left thigh, more marked at

the fracture site. Clinical examination revealed : PS (statural performance) of 1, with a hard, firm, painful swelling 16cm long on the left thigh.

MRI of the left thigh revealed a tumoral mass in the middle third of the left thigh measuring 11*8cm by 18cm (Fig. 1).

Soft tissue biopsy was consistent with a plasmacytoma with Kappa monotypy; CD138+, MUM1 +, CD45-, ERG-, CD20-, CD3-, CD99- (Fig. 2).

The pet scan showed a hypermetabolic tissue process in the lower half of the left thigh with an SUV max of 9.05, and no suspicious hypermetabolism over the rest of the volume explored (Fig. 3).

Bone radiology was normal, with normocytic normochromic anaemia at 8g/dl, normal renal function tests and serum calcium levels. Serum protein electrophoresis showed a narrow

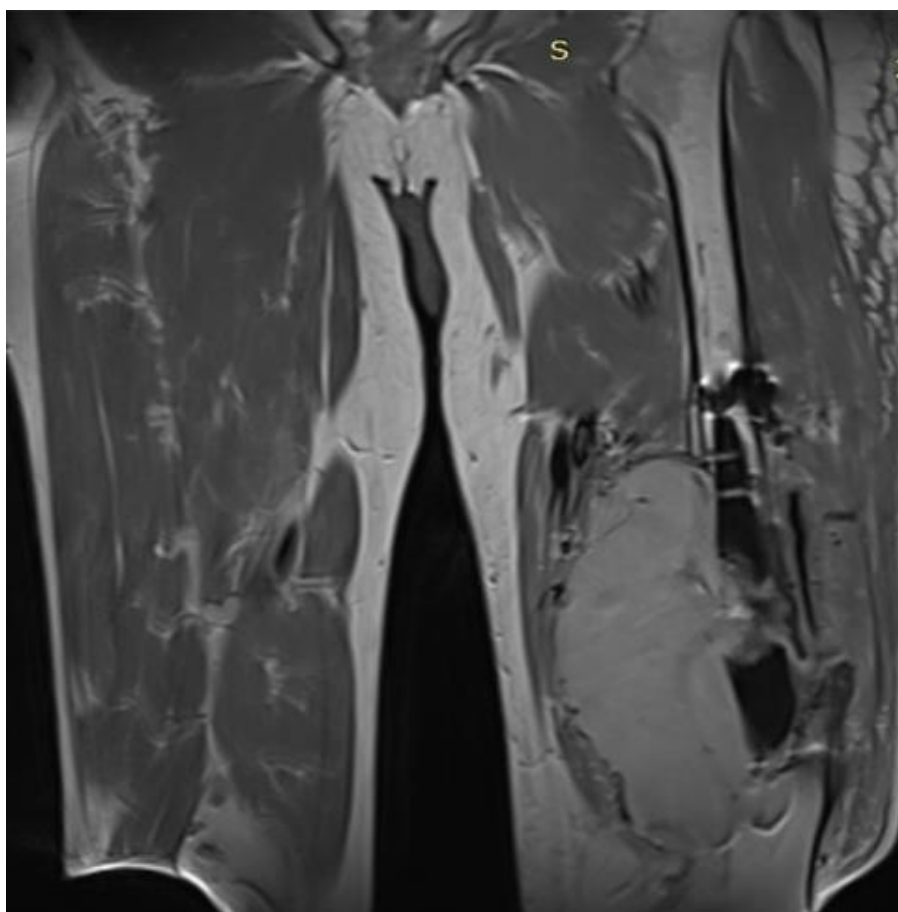


Fig. 1. T2 sagittal section of a tumor mass in the middle third of the left thigh

monoclonal band migrating into the gamma zone at 30g/l, with Kappa IgG immunoglobulin. Light chain assay showed a Kappa chain at 117mg/l, and a Lambda chain at 34.7mg/l; with a K/L ratio of 3.38. Myelogram, osteomedullary biopsy and 24-hour proteinuria were normal. Multidisciplinary

management of our patient involved traumatologists, hematologists, radiologists, nuclear medicine physicians and radiation therapists. The decision of the RCP was to receive radiotherapy sessions only on the tumor mass.

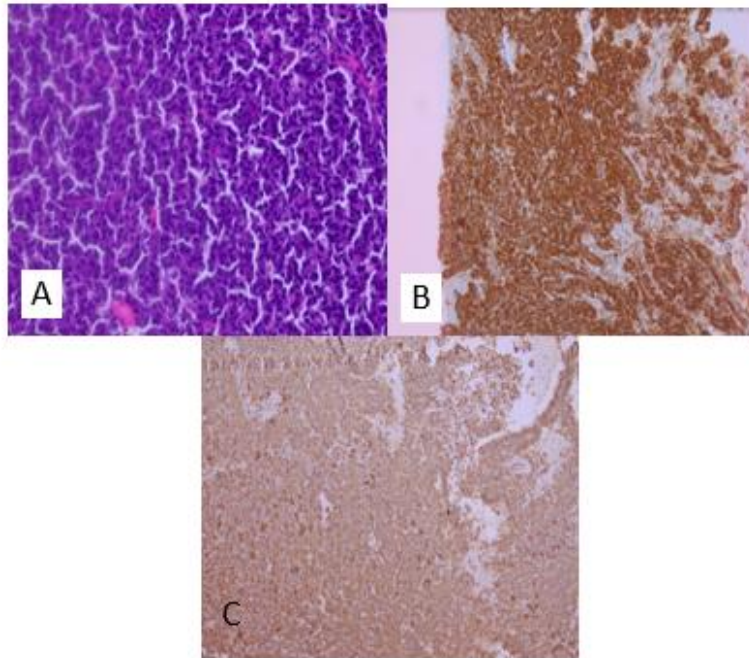
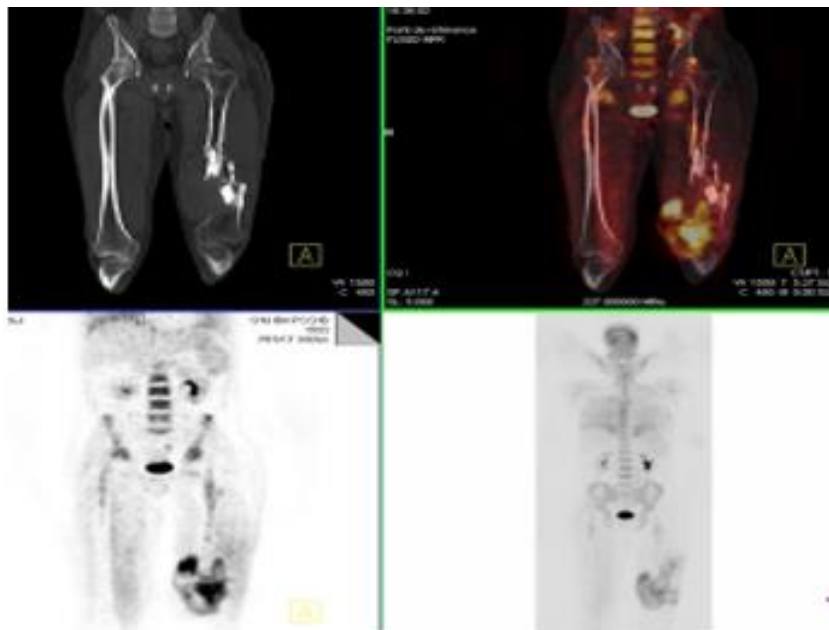


Fig. 2A. Histological appearance of plasmacytoma (HES: 10x40): well-differentiated, monomorphic, plasma cell-like cells. B: Immunohistochemical appearance (IHC: 10x4): strong, intense, diffuse membrane expression of CD138. C: Immunohistochemical appearance (IHC: 10x4): Plasma cells also express monotypic IgG Kappa



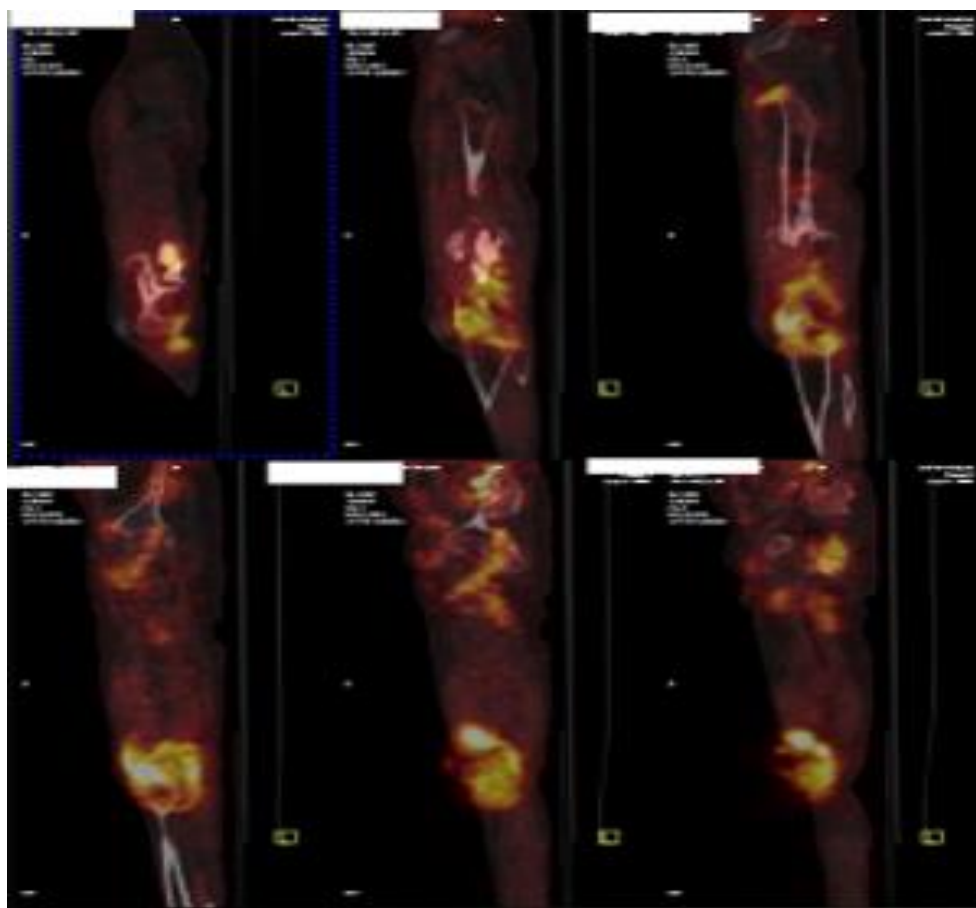


Fig. 3. Positron emission tomography: tissue process of the lower half of the left thigh

3. DISCUSSION

Multiple myeloma is the most common type of malignant plasma cell proliferation. Myeloma cells can form tumors, called plasmacytomas. Plasmacytomas can sometimes arise after surgery, from laparotomy scars or catheter insertions [5], as in our case.

It is possible that the inflammatory process of a wound may facilitate the migration of myeloma cells into the skin, creating a reservoir for proliferation [6].

The appearance of a soft-tissue plasmacytoma along a surgical scar 10 years prior to diagnosis was reported in a patient with multiple myeloma [7].

Positive diagnosis is essentially based on immunohistochemical studies.

MRI is useful in assessing the nature of the plasmacytoma (bony or extraosseous) and its extent.

Positron emission tomography is the most useful whole-body technique when soft tissue involvement is suspected [8], with a sensitivity of 96% and specificity of 87%. Surgical resection of plasmacytoma is generally not necessary, as these malignant tumours are radiosensitive. For the most part, surgical excision is reserved for cases where there is a loss of anatomical structural integrity or spinal cord compression [9]. If surgery is performed, it is usually carried out before radiotherapy and as a complement to definitive radiotherapy.

Treatment of plasmacytoma is therefore essentially based on radiotherapy. A response rate of 80-90% can be achieved with radiotherapy alone [10].

Immunochemotherapy has also been proposed to improve disease control and prevent progression to multiple myeloma following radiotherapy, although data are largely insufficient [11].

However, VMP or VRD regimens combined with Daratumumab appear to be the treatment of choice for patients who are not eligible for autotransplantation [12]. Intensive treatment with VTD or VRD/cisplatin, doxorubicin, cyclophosphamide and etoposide (PACE) is offered to patients eligible for autotransplantation.

The International Myeloma Group (IMWG) uniform response criteria require disappearance of soft-tissue masses for complete remission (CR) and $\geq 50\%$ reduction for partial response (PR) [13].

The presence of soft-tissue plasmacytoma is associated with significantly shorter progression-free survival and overall survival, although the incidence is only 6% and 10% respectively [14].

4. CONCLUSION

Soft-tissue plasmacytoma is a rare tumor; its management is multidisciplinary. Radiotherapy remains the mainstay of treatment. The risk of local and distant relapse, and of transformation into multiple myeloma, warrants regular monitoring.

CONSENT

As per international standards or university standards, patient(s) written consent has been collected and preserved by the author(s).

ETHICAL APPROVAL

As per international standards or university standards written ethical approval has been collected and preserved by the author(s).

COMPETING INTERESTS

Authors have declared that no competing interests exist.

REFERENCES

1. Weinstock M, Aljawai Y, Morgan EA, Laubach J, Gannon M, Roccaro AM, et al. Incidence and clinical features of extramedullary multiple myeloma in patients who underwent stem cell transplantation. *Br J Haematol.* 2015;169:85

2. Wiltshaw E. The natural history of extramedullary plasmacytoma and its relation to solitary myeloma of bone and myelomatosis. *Medicine.* 1976;55(3):217–238
3. Blade J, Fernandez de Larrea C, et al. Soft-tissue plasmacytomas in multiple myeloma: *J Clin Oncol.* 2011;29:3805–1
4. Buthani M, Foureau DM, Atrash S, Voorhees PM, Usmani SZ. Extramedullary multiple myeloma. *Leukemia.* 2020;34:1–20.
5. Reseblum MD, Bredeson CN, Chang CC, Rizzo JD. Subcutaneous plasmacytomas with tropism to sites of previous trauma in a multiple myeloma patient treated with an autologous bone marrow transplant. *Am J Hematol.* 2003;72:2
6. Fernandez de Larrea C, Rosinol L, et al. Extensive soft-tissue involvement by plasmablastic myeloma arising from displaced humeral fractures.
7. Rosinol L, et al. Extramedullary myeloma spread triggered by surgical procedures: an emerging entity? *Acta Haematol.* 2014;132:36–8
8. Zamagni E, Cavo M. The role of imaging techniques in the management of multiple myeloma. *Br J Haematol.* 2012;159:499–513
9. Caers J, Paiva B, Zamagni E, Leleu X, Bladé J, et al. Diagnosis, treatment, and response assessment in solitary plasmacytoma: updated recommendations from a European Expert Panel. *J HematolOncol.* 2018;11(1):10
10. Mendenhall WM, Mendenhall CM, Mendenhall NP. Solitary plasmacytoma of bone and soft tissues. *Am J Otolaryngol.* 2003;24:395–9
11. Holland J, Trenkner DA, Wasserman TH, Fineberg B. Plasmacytoma. Treatment results and conversion to myeloma. *Cancer.* 1992;69:1513–7
12. Durie BG, Hoering A, Abidi MH, Rajkumar SV, Epstein J, Kahanic SP, et al. Bortezomib with lenalidomide and dexamethasone versus lenalidomide and dexamethasone alone in patients with newly diagnosed myeloma without intent for immediate autologous stem-cell transplant (SWOG S0777): A randomised, open-label, phase 3 trial. *Lancet.* 2017;389:519–27
13. Durie BG, Harousseau JL, et al. International uniform response criteria for multiple myeloma. *Leukemia.* 2006;20:1467–7

14. Pasmantier MW, Azar HA. Extraskkeletal review of 57 autopsied cases. *Cancer.* spread in multiple plasma cellmyeloma: A 1969;23:167–74.

© 2024 Ilham et al.; This is an Open Access article distributed under the terms of the Creative Commons Attribution License (<http://creativecommons.org/licenses/by/4.0>), which permits unrestricted use, distribution, and reproduction in any medium, provided the original work is properly cited.

Peer-review history:

*The peer review history for this paper can be accessed here:
<https://www.sdiarticle5.com/review-history/112207>*