

# Rhupus: About Two Clinical Cases in Niger and Literature Review

Andia Abdoukader<sup>1</sup>, Brah Souleymane<sup>1</sup>, Daou Mamane<sup>2</sup>, Tahirou Harouna<sup>1</sup>, Migita Moctar<sup>1</sup>, Adehossi Eric<sup>1,2</sup>

<sup>1</sup>Department of Internal Medicine and Geriatric, Reference General Hospital, Niamey, Niger

<sup>2</sup>Department of Internal Medicine, Hôpital National de Niamey, Niamey, Niger

Email: [abdoukader79@yahoo.fr](mailto:abdoukader79@yahoo.fr), [daoumo@yahoo.fr](mailto:daoumo@yahoo.fr), [brahsouleymane@yahoo.fr](mailto:brahsouleymane@yahoo.fr), [tahirouissakal@gmail.com](mailto:tahirouissakal@gmail.com),

[migitabamoctar12@gmail.com](mailto:migitabamoctar12@gmail.com), [eadehossi@yahoo.fr](mailto:eadehossi@yahoo.fr)

**How to cite this paper:** Abdoukader, A., Souleymane, B., Mamane, D., Harouna, T., Moctar, M. and Eric, A. (2022) Rhupus: About Two Clinical Cases in Niger and Literature Review. *Open Journal of Internal Medicine*, 12, 46-51.

<https://doi.org/10.4236/ojim.2022.121006>

**Received:** July 1, 2021

**Accepted:** March 12, 2022

**Published:** March 15, 2022

Copyright © 2022 by author(s) and Scientific Research Publishing Inc. This work is licensed under the Creative Commons Attribution International License (CC BY 4.0).

<http://creativecommons.org/licenses/by/4.0/>



Open Access

## Abstract

**Background:** Rhupus is the rare association of two autoimmune diseases, systemic lupus erythematosus (SLE) and rheumatoid arthritis (RA) diagnosed according to validated ACR criteria. We present the first series of rhupus in Niger. **Observation 1:** This is a patient suffering from chronic polyarthritis in whom the diagnosis of active seropositive, erosive and deforming RA had been made according to the 1987 ACR criteria and SLE on the presence of 4 criteria according to the 1997 ARA criteria and putting under conventional synthetic DMARDs. The outcome was favorable with a remission achieved after 8 weeks with a *disease activity score* (DAS) 28 at 2.2. **Observation 2:** 58-year-old patient with known diabetes type 2 in whom the diagnosis of rhupus was made according to the ACR/EULAR 2010 criteria for RA with a DAS28 of 3.6 and the 2019 LES criteria at 18 points with a SLEDAI score of 6. The evolution was marked by the occurrence of a myocardial infarction with a favorable outcome under medical management. **Conclusion:** Rhupus is a rare entity that can be complicated by cardiovascular events with the presence of an independent cardiovascular risk factor.

## Keywords

Rhupus, ACR/EULAR Criteria, Niger

## 1. Introduction

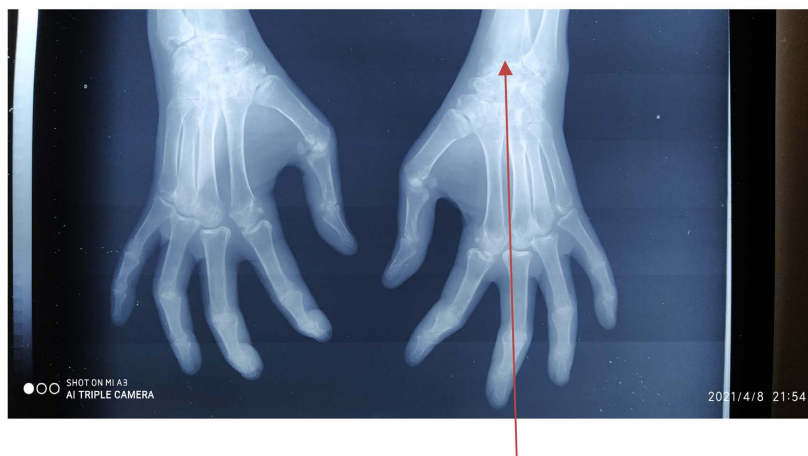
The concept of “rhupus” was proposed by Schur in 1971 [1]. It is characterized in clinical practice by the presence of both the clinical classification criteria for rheumatoid arthritis (RA) which is an autoimmune disease of unknown cause, Systemic predominantly synovial, evolving by relapses and remissions with an

erosive and destructive tendency towards the elements constituting the joint and Systemic Lupus Erythematosus (SLE) which is a systemic autoimmune disease evolving by relapse interspersed with a period of remission. Although there is no consensus on widely accepted diagnostic criteria that most studies are based on the description of the characteristics and pathogenesis of the disease [2] [3] [4]. The prevalence is estimated at 0.09% [5]. In China, a retrospective study reported 56 cases of Rhupus over 13 years in Beijing then 10 cases over 4 years in Guangzhou [2] [6]. In Africa, several series of clinical cases had been reported in Senegal, Guinea, Mali, Cameroon and Tunisia [7]-[12]. In Niger, these are the first cases of rhupus reported, including a visceral complication.

**Observation 1:** This is a 49-year-old patient suffering from chronic joint pain and swelling often debilitating on self-medication without improvement. She was admitted to the Internal Medicine Department of the General Reference Hospital in March 2021. On clinical examination we find: A general condition preserved with a malar erythema in the face, a notion of photosensitivity of recent appearance and two (2) rheumatoid nodules on the anterior face of the distal third of the left leg. Polyarthritis of the small metacarpophalangeal (MP) and proximal interphalangeal (PPI) joints and large joints (wrists, ankles and knees) bilateral, symmetrical with stiffness and morning rusting of about 1 hour associated with deformity in a cubital gust with the left hand and a Z thumb with the right hand. The DAS28 activity score = 4.5 and SLEDAI = 8.

The biology found: an inflammatory syndrome with a sedimentation rate (VS) accelerated to 120 mm at the 1st hour and a positive C-reactive protein (CRP) at 96 mg/l. The proteinuria was 0.26 g/day. Anti-nuclear antibodies (ANA) were positive at 1/640, speckled type, anti-native DNA antibodies were positive at 10.0 IU, anti-citrullinated cyclic peptide antibodies (anti CCP) = 33.5 U/ml. Renal and hepatic function were normal.

The standard X-ray of the hands-facing revealed diffuse pinching of the joint space, geodes and left carpal radio-ulna erosions (**Figure 1**).



**Figure 1.** Hands-facing revealed diffuse pinching of the joint space, geodes and left carpal radio-ulna erosions.

The diagnosis of RA was made according to the ACR 1987 criteria: rheumatoid nodule; Ac anti CCP, bilateral symmetrical polyarthritis, articular erosion and morning stiffness; for SLE, the presence of 3 parameters: cutaneous-mucous, rheumatological and immunological totaling 18 points of the criteria of EULAR/ACR 2019 of SLE.

The treatment was based on methotrexate with a maximum dose of 22.5 mg reached after 4 weeks, hydroxychloroquine at a dose of 400 mg/day, Prednisolone at a dose of 10 mg and adjuvant measures with good clinical improvement after 8 weeks.

**Observation 2:** 58-year-old patient with type 2 diabetic, admitted to the internal medicine department of the Niamey National Hospital for chronic polyarthritis of the small metacarpophalangeal (MP) and proximal interphalangeal (PPI) and large joints (wrists) bilateral and symmetrical associated with recent mouth ulcers. There is no deformation or erosion of the joints. There is a notion of morning stiffness and softening of more than 30 minutes without weight loss or clinical dry syndrom.

The physical examination found a patient with a general condition preserved, a retro sternal thoracic pain radiating towards the shoulder and the left arm of sudden installation.

The biology found Leukopenia in the blood count, a speed of Sedimentation (VS) accelerated to 88 mm at the first hour and a positive C-reactive protein (CRP) at 76 mg/l. The proteinuria was 0.55 g per day. Renal and hepatic function were normal. Immunologically, anti-nuclear antibodies (ANA) were positive at 1/120 of the speckled type, anti DNA antibodies negative, anti-citrullinated cyclic peptide antibodies at 40 U/ml. The X-ray of the hands and feet was normal.

The diagnosis of rhupus was made on the ACR EULAR 2010 criteria (7/10) for RA and the presence of 4 parameters: Hematological; cutaneous-mucous membranes; joint damage and glomerulopathy totaling 19 points of the ACR/EULAR 2019 criteria of the LES. The treatment was based on methotrexate, hydroxychloroquine and prednisolone for 6 months. The evolution was marked by the occurrence of a myocardial infarction due to chest pain, ST elevation on ECG, high Troponin Ic and normal heart echography. The coronary angiography is not done. The treatment received was Bolus solumedrol, Anti aggregating plakelet, statins and beta blockers with improvement of its clinical state.

## 2. Discussion

Rhupus is characterized by the presence at the same time by the presence in the same patient of symmetrical, deforming and erosive polyarthritis, accompanying symptoms and clinical signs of SLE with presence highly specific autoantibodies of the latter (native anti-DNA or anti-Sm) and making a real overlap syndrome [13]. There is a female predominance (96.4%) and a mean age of 57 years corroborating our two clinical cases [14] [15]. The classic joint symptoms of RA are

predominant and precede those of SLE over time, like in the case of our two patients [11]. The cutaneous manifestations found were erythematous plaques and butterfly wing erythema [9]. In our second clinical case 2, the occurrence of mouth ulcers is one of the diagnostic criteria according to the ACR 1987 classification of the LES; biologically, leukopenia and/or anemia with a biological inflammatory syndrome are described [9]. In immunology, native anti-DNA antibodies and highly specific anti-Sm antibodies for lupus were found in 52.7%

**Table 1.** Summary of African rhus series.

|               | Niger<br>(2 cases) | Senegal<br>(4 cases)        | Guinea<br>(2 cases) | Cameroun<br>(1 case) | Tunisia<br>(2 cases) |
|---------------|--------------------|-----------------------------|---------------------|----------------------|----------------------|
| Age<br>(year) |                    | 33                          |                     |                      |                      |
|               | 49                 | 36                          | 48                  |                      | 45                   |
|               | 58                 | 28                          | 26                  | 37                   | 34                   |
|               |                    | 35                          |                     |                      |                      |
| Sex           |                    | F                           |                     |                      |                      |
|               | F                  | F                           | M                   | F                    | F                    |
|               | F                  | M                           | F                   |                      | F                    |
|               |                    | M                           |                     |                      |                      |
| CRP           |                    | 32                          |                     |                      |                      |
|               | 96                 | 3.1                         | 11.3                | Hight                | 13                   |
|               | 76                 | 96                          | 22.6                |                      |                      |
|               |                    | Non done                    |                     |                      |                      |
| VS            |                    | 50                          |                     |                      |                      |
|               | 120                | 30                          | 52                  | Hight                | 30                   |
|               | 88                 | 34                          | 16                  |                      | 110                  |
|               |                    | Non fait                    |                     |                      |                      |
| RX            | Erosion            | Pinching,<br>geode, erosion | Erosion             | Not<br>erosion       | Carpises             |
| Ac anti CCP   |                    | 69 UI/ml                    |                     |                      |                      |
|               | 33.5 U/ml          | 148 UI/ml                   | 300 U/ml            | Positif              | 122                  |
|               | 40 U/ml            | Négative                    | 62 UI/ml            |                      | 100                  |
|               |                    | 200 UI/ml                   |                     |                      |                      |
| AAN           | 1/600              | Not done                    | 1/320,              |                      | 1/600                |
|               | Mouchetéé          | Not done                    | mouchetéé           | Positif              | Homogéne             |
|               | 1/120              | Not done                    | 1/80,               |                      | 1/1280               |
|               | mouchetéé          | 1/640,                      | mouchetéé           |                      | Homogéne             |
|               |                    | mouchetéé                   |                     |                      |                      |
| DNA           |                    | Not done                    |                     |                      |                      |
|               | Positif            | Not done                    | 209 U/ml            | -                    | Positif              |
|               | Negatif            | Negative                    | 300 U/ml            |                      |                      |
|               |                    | Not done                    |                     |                      |                      |
| Das 28-Sledai | 4.5 - 8            |                             | 3.1 - 6             | 3.34 - 6             | -                    |
|               | 3.6 - 6            | -                           | 3.6 - 5             |                      |                      |

Das = disease activity score, Sledai = systematic lupus disease index.

and 14.5% of patients, respectively [16]. Rheumatoid factors and anti-CCP antibodies were positive in 58.2% and 58.2% of patients, respectively [9]. These results corroborate our two clinical cases apart from anti-Sm. Bone radiography may be normal or show variable abnormalities such as bone demineralization (60%), carpalis (25%), bone erosion (10.9%) and joint pinching (9.1%) [9]. In observation 1, we note on the X-ray of the hands a diffuse pinching of the joint space and left carpal radio erosion (**Figure 1**).

The treatment received was Prednisolone, Methotrexate and hydroxychloroquine with adjuvant therapy. The evolution was marked by the occurrence of a myocardial infarction in our second patient, probably due to the presence of independent cardiovascular risk factors associating the type 2 diabetic or the presence of an anticoagulant circulating in the context of lupus. In the literature, severe complications can occur in 10% of cases dominated by renal impairment, ischemic heart disease, blindness, fracture osteoporosis, infections, pulmonary fibrosis and seritis [9] [10]. **Table 1** resumes African rhupus series.

### 3. Conclusion

Rhupus is rare but real clinical entity with a true overlapping syndrome of signs of RA and SLE. Complications are possible, especially with the presence of other independent cardiovascular risks.

### Conflicts of Interest

The authors declare no conflicts of interest regarding the publication of this paper.

### References

- [1] Schur, P.H. (1971) Systemic Lupus Erythematosus. In: Beeson, P.B. and McDermott, W., Eds., *Cecil-Loeb Textbook of Medicine*, 13th Edition, W.B. Saunders, Philadelphia, 821.
- [2] Li, J., Wu, H., Huang, X., Xu, D., Zheng, W., Zhao, Y., *et al.* (2014) Clinical Analysis of 56 Patients with Rhupus Syndrome: Manifestations and Comparisons with Systemic Lupus Erythematosus: A Retrospective Case-Control Study. *Medicine*, **93**, e49. <https://doi.org/10.1097/MD.0000000000000049>
- [3] Tani, C., D’Aniello, D., Delle Sedie, A., Carli, L., Cagnoni, M., Possemato, N., *et al.* (2013) Rhupus Syndrome: Assessment of Its Prevalence and Its Clinical and Instrumental Characteristics in a Prospective Cohort of 103 SLE Patients. *Autoimmunity Reviews*, **12**, 537-541. <https://doi.org/10.1016/j.autrev.2012.09.004>
- [4] Lozada-Navarro, A.C., Castillo-Martínez, D., Moreno-Ramírez, M., Acosta-Peña, G., Páez, A., Massó, F., *et al.* (2018) An Imbalance in the T-Helper Phenotypes Displayed by Senescent CD4<sup>+</sup>CD28<sup>null</sup> T Cells Is Associated with Erosive Arthritis (Rhupus Syndrome) in Systemic Lupus Erythematosus. *Lupus*, **27**, 2155-2160. <https://doi.org/10.1177/0961203318793715>
- [5] Panush, R.S., Edwards, N.L., Longley, S. and Webster, E. (1988) “Rhupus” Syndrome. *Archives of Internal Medicine*, **148**, 1633-1636. <https://doi.org/10.1001/archinte.1988.00380070117028>

- [6] Chen, Z.-X., Yang, P.-D., Liu, M.-Y., Song, P.-F. and Xu, Q. (2020) Need for Greater Attention to Joint Damage in Rhupus Patients: Results from an Ultrasound Study. *Medical Science Monitor*, **26**, Article ID: e927104. <https://doi.org/10.12659/MSM.927104>
- [7] Ndao, A.C., Diallo, R., Diagne, N., Kane, B.S., Djiba, B., Dieng, M., *et al.* (2017) Rhupus: Illustration about Four Senegalese Cases. *International Journal of Science and Research*, **6**, 656-659.
- [8] Kaba, C., Salissou, G.M., Moustapha, N. and Rama, D. (2019) Rhupus: Étude de Deux Observations à Conakry, Guinée. *European Scientific Journal*, **15**, 181-187. <https://doi.org/10.19044/esj.2019.v15n12p181>
- [9] Tchoukui, T. and Doris, G. (2019) Rhupus: Fréquence et aspects: Cliniques et immunologiques dans le Service de Rhumatologie (CHU-pt G). Thèse Médecine Ghislain Doris TCHOUKOUA, University of Science Technical and Technologies De Bamako, Bamako.
- [10] Francky, T., Michael, E., Cathy, M.P., Jean Rene, N. and Madeleine, S.N. (2017) Rhupus Syndrome Associated with Multiple Complications: A Case Report from Yaoundé, Cameroon. *1st Congress of the Cameroon College of Rheumatology*.
- [11] Dhahri, R., Rekik, S., Aouadi, A., Sehli, H., Meddeb, N. and Cheour, E. (2013) Aspects cliniques biologiques et évolutifs du rhupus syndrome: Une étude de 9 cas. *Revue du Rhumatisme*, **80S**, Article No. A238.
- [12] Hachicha, I., Fourati, H., Akrouf, R. and Baklouti, S. (2012) Syndrome de Rhupus: A propos de deux observations. *Pan African Medical Journal*, **12**, Article No. 50.
- [13] Amezcua-Guerra, L.M., Springall, R., Marquez-Velasco, R., Gomez-Garcia, L., Vargas, A. and Bojalil, R. (2006) Presence of Antibodies against Cyclic Citrullinated Peptides in Patients with "Rhupus": A Cross-Sectional Study. *Arthritis Research & Therapy*, **8**, Article No. R144. <https://doi.org/10.1186/ar2036>
- [14] Malaise, O., Halleux, S., vonFrenckell, C., Lutteri, L., Chapelle, J.-P. and Malaise, M.G.L.E. (2012) RHUPUS: A la frontière entre polyarthrite rhumatoïde et lupus érythémateux disséminé. *Revue médicale de Liège*, **67**, 475-484.
- [15] Fernandez, A., Quintana, G., Rondon, F., Restrepo, J., Sanchez, A., Iglisias, A., *et al.* (2006) Lupus Arthropathy: A Case Series of Patients with Rhupus. *Clinical Rheumatology*, **25**, 164-167. <https://doi.org/10.1007/s10067-005-1149-y>
- [16] Amezcua-Guerra, L., Marquez-Velasco, R. and Bojalil, R. (2008) Erosive Arthritis in Systemic Lupus Erythematosus Is Associated with High Serum C-Reactive Protein and Anti-Cyclic Citrullinated Peptide Antibodies. *Inflammation Research*, **57**, 555-557. <https://doi.org/10.1007/s00011-008-8110-x>