



## **Diagnosis of Bilateral Type-A Radix Para-Molaris on Mandibular First Molars: A Case Report**

**Sathish Abraham<sup>1\*</sup>, Neha Jaju<sup>1</sup>, Priya Yawalikar<sup>1</sup> and Rajan J. Mangrolia<sup>1</sup>**

<sup>1</sup>*SMBT Dental College & Hospital, Conservative Dentistry & Endodontics, Amrutnagar,  
Tal- Sangamner, Dist- Ahmadnagar, Maharashtra, India.*

### **Authors' contributions**

*This work was carried out in collaboration among all authors. All authors read and approved the final manuscript.*

### **Article Information**

DOI: 10.9734/JAMPS/2015/14756

#### Editor(s):

(1) Franciszek Burdan, Experimental Teratology Unit, Human Anatomy Department, Medical University of Lublin, Poland.

#### Reviewers:

(1) Abdelmoumen Ehsen, Restorative Dentistry and Endodontics, Dental University of Monastir, Tunisia.

(2) Dimitrios Dionysopoulos, Department of Operative Dentistry, Aristotle University of Thessaloniki, Greece.

(3) Anonymous, Süleyman Demirel University, Turkey.

(4) Zhihui Zhang, Department of Oral Medicine, Peking University School and Hospital of Stomatology, Beijing, China and Stomatology Department, Peking University Third Hospital, Beijing, China.

Complete Peer review History: <http://www.sciencedomain.org/review-history.php?iid=790&id=36&aid=7096>

**Case Study**

**Received 19<sup>th</sup> October 2014**

**Accepted 12<sup>th</sup> November 2014**

**Published 6<sup>th</sup> December 2014**

### **ABSTRACT**

Successful endodontic treatment of a molar tooth having an additional root whether it is radix para/ento molaris; begins with proper diagnosis. Hence careful examination and assessment of intra oral peri-apical radiographs should be done prior to attempting access opening. These iopa's provide sufficient details regarding presence of additional roots. Mesial or distal cone shift technique could be used to assess according to operator's choice to confirm presence of additional roots. In addition to the intra oral peri-apical radiographs, CBCT evaluation is recommended for the correct diagnosis, as that will help in rendering quality treatment to the patients. Access opening design will require modification in order to accommodate a straight line entry to the additional root (RP or RE). Cleaning and shaping can follow with standard procedures unless there is presence of additional canals in the same root such as mid mesial canal. In such cases, it may be wise not to enlarge the canal with a 6% taper; as it will compromise lot of intra canal dentin and weaken the root. However, once the tooth is successfully treated endodontically; one can proceed to do crown prosthesis of clinician's choice depending on various factors.

\*Corresponding author: E-mail: [abrahamsathish@yahoo.in](mailto:abrahamsathish@yahoo.in);

**Keywords:** Radix para-molaris; cone beamed CT; congenitally missing second premolars; endodontics.

## 1. CASE REPORT

A 40 year-old male patient reported with a chief complaint of severe pain on the left posterior region of his mouth. Upon check-up and routine documentation, he was diagnosed with irreversible pulpitis in left mandibular first molar. On radiographic (Intraoral Peri-apical; [IOPA]) examination (Fig. 1) the presence of an additional root was confirmed to be radix para-molaris.

He also presented with an over retained right mandibular deciduous second molar. Upon radiographic examination the premolar was found congenitally missing and the right mandibular first molar was having an additional root, confirmed to be radix para-molaris. He also had a history of recent extraction of a decayed tooth on the left side which he described as a very small dark posterior tooth with multiple roots. It was suggestive of a left deciduous molar. This confirmed bilateral congenital absence of mandibular second premolars. An orthopantomograph was advised to confirm clinical findings and to rule out other issues like unusual impactions of the missing teeth (Fig. 2). The left mandibular first molar was carious and was indicated for an endodontic therapy.

## 2. ENDODONTIC MANAGEMENT

Successful endodontic treatment of a molar tooth having an additional root whether it is radix para/ento molaris; begins with proper diagnosis. Hence careful examination and assessment of intra oral peri-apical radiographs should be done prior to attempting access opening. These IOPA's provides sufficient details regarding presence of additional roots. Mesial or distal cone shift technique could be used to assess according to operator's choice to confirm presence of additional roots. Access opening design will require modification in order to accommodate a straight line entry to the additional root (RP or RE). Cleaning and shaping can follow with standard procedures unless there is presence of additional canals in the same root such as mid mesial canal. In such cases, it may be wise not to enlarge the canal with a 6% taper; as it will compromise lot of intra canal dentin and weaken the root. However, once the tooth is successfully treated endodontically; one can

proceed to do crown prosthesis of clinician's choice depending on various factors.

However; the case presented here is a left mandibular first molar diagnosed with irreversible pulpitis. It was indicated for an endodontic treatment followed by crown prosthesis. The area was anesthetized with an inferior alveolar nerve block prior to rubber dam application. An access preparation was made to obtain straight line access to all the canals including the radix para-molaris; with an extension into the mesio-buccal aspect of the tooth. Upon completion of access preparation, pulpal remnants were extirpated and the orifices of all the 5 canals were located. The 5 canals were the mesio-buccal canal, mesio-lingual canal, disto-buccal canal, disto-lingual canal and the type-A radix para-molaris. Cleaning and shaping of these canals were done with hand Protaper instruments up to F2 with 6% taper after confirming the working length of all the canals (Fig. 3). The tooth was obturated with a cold lateral condensation technique in the following visit.

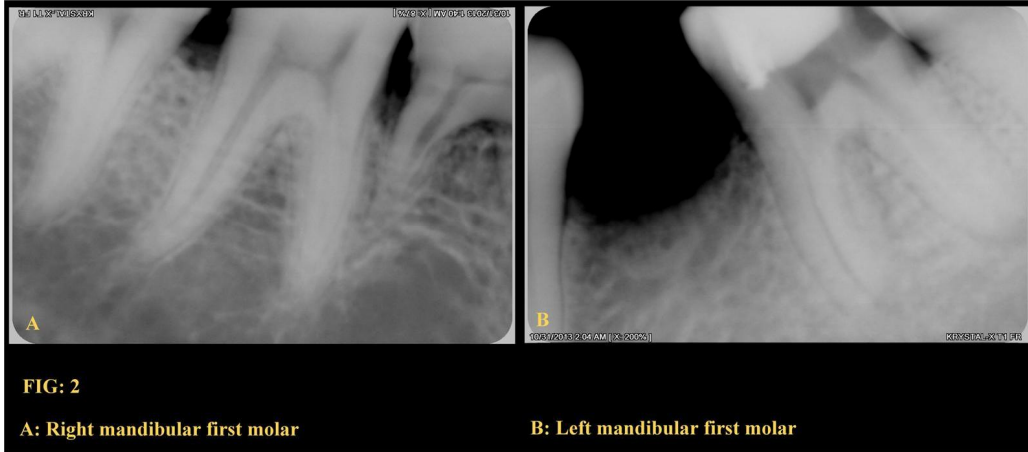
## 3. DISCUSSION

Bilateral radix para-molaris is a very rare occurrence as per reports published so far. It is considered to be 0 – 5% in different populations as per research articles published in unilateral cases [1,2,3]. Studies contradict each other on more percentage of its occurrence on right and left sides of the mandibular arch [4,5]. However, bilateral occurrence of radix para-molaris on mandibular has not been reported.

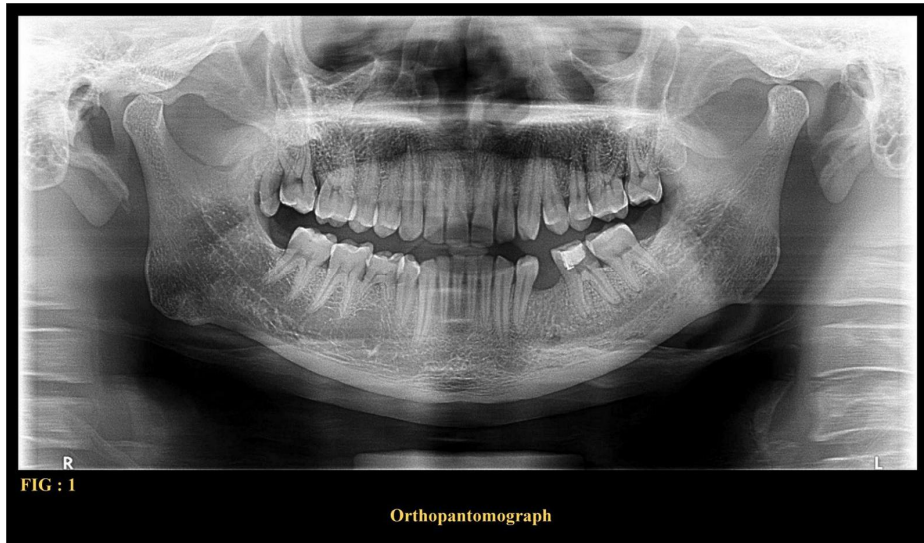
NB Nagaveni and KV Umashankara [6] suggested that a thorough examination of the preoperative radiograph and interpretation of particular marks or characteristics, such as an unclear view or outline of the distal/mesial root contour or the root canal, can suggest the presence of a "hidden" RE/RP (Radix Entomolaris/Radix Paramolais). [6] In their study they found only two unilateral cases of radix paramolaris type –A mesiobuccal root. [6] Carlsen O and Alexandersen V [7] classified the radix paramolaris as Type – A and Type – B. Type-A is an additional mesio-buccal root whose coronal part is attached to the mesial root complex and Type- B is an additional root which is seen in the central point of mesial and distal roots buccally [7]. In their study, they found five

cases of type A and none of type B in the total 203 permanent molars examined. Root and the canal morphology I permanent mandibular

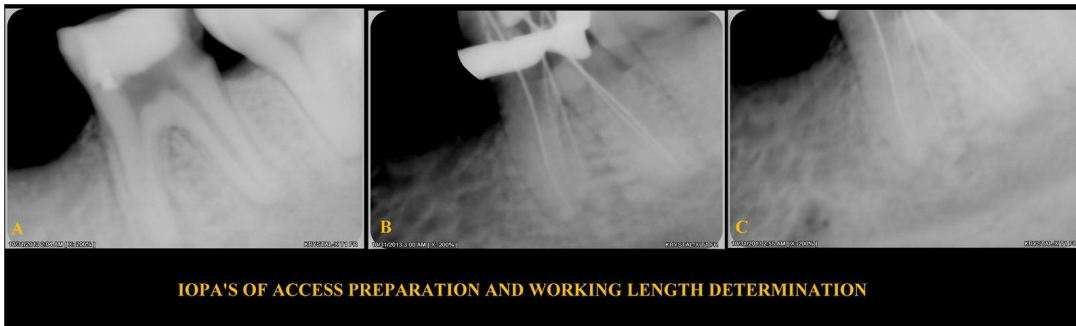
molars may vary drastically as per current annals [8].



**Fig. 1. Intraoral peri-apical radiographs**



**Fig. 2. Orthopantomograph**



**Fig. 3. Iopa's of endodontic management**

However, recent advances in the field of dental radiography like micro-computed tomography (micro CT) and cone-beam computed tomography (CBCT) helps by a great deal in diagnosing such exceptional occurrences thereby helping in quality treatment for the patients. Ingle et al. [9,10] recommended a thorough radiographic study of the involved tooth, using exposure from the standard buccal-to-lingual projection, one taken 20° from the mesial, and the third taken 20° from the distal to obtain basic information regarding the anatomy of the tooth [6]. Loh has claimed that the RE/RP does not normally appear in peri-apical radiographs that are taken in the traditional manner [6]. Adjusting the exposure time and dose of the x-ray and angulating the main beam (to avoid superimposing the larger disto-buccal/mesial root) can to help make RE/RP more evident although accurate interpretation of radiographs depends on the trained eye [6,10]. A 1985 study by Walker and Quackenbush claimed that panoramic radiographs resulted in an accuracy rate of approximately 90%. Bilateral occurrence of radix para-molaris is very rare. Thorough examination of the preoperative radiograph and interpretation of particular marks

or characteristics, such as an unclear view or outline of the distal/mesial root contour or the root canal, can suggest the presence of a "hidden" RE/RP [6,11].

A Cone beamed CT was advised to re-confirm the earlier findings with the IOPA's [12]. CBCT has now emerged as a diagnostic equipment best suited for many specialities in dentistry [12,13]. It gives a perfect three dimensional image of any required area around dentition. It is known to be an endodontist's boon; as it helps in perfect diagnosis, analysis and to provide quality treatment for the needy [12]. It confirmed the bilateral congenital absence of mandibular second premolars and a bilateral radix paramolaris with the mandibular first molars (Fig. 4).

The arial view with dissections at coronal, mid and apical aspects clearly suggests the presence of a Type-A radix paramolaris (Fig. 5).

However; there are no reports on bilateral radix para-molaris on mandibular first molars in global annals so far. Hence, this could be considered as unique.

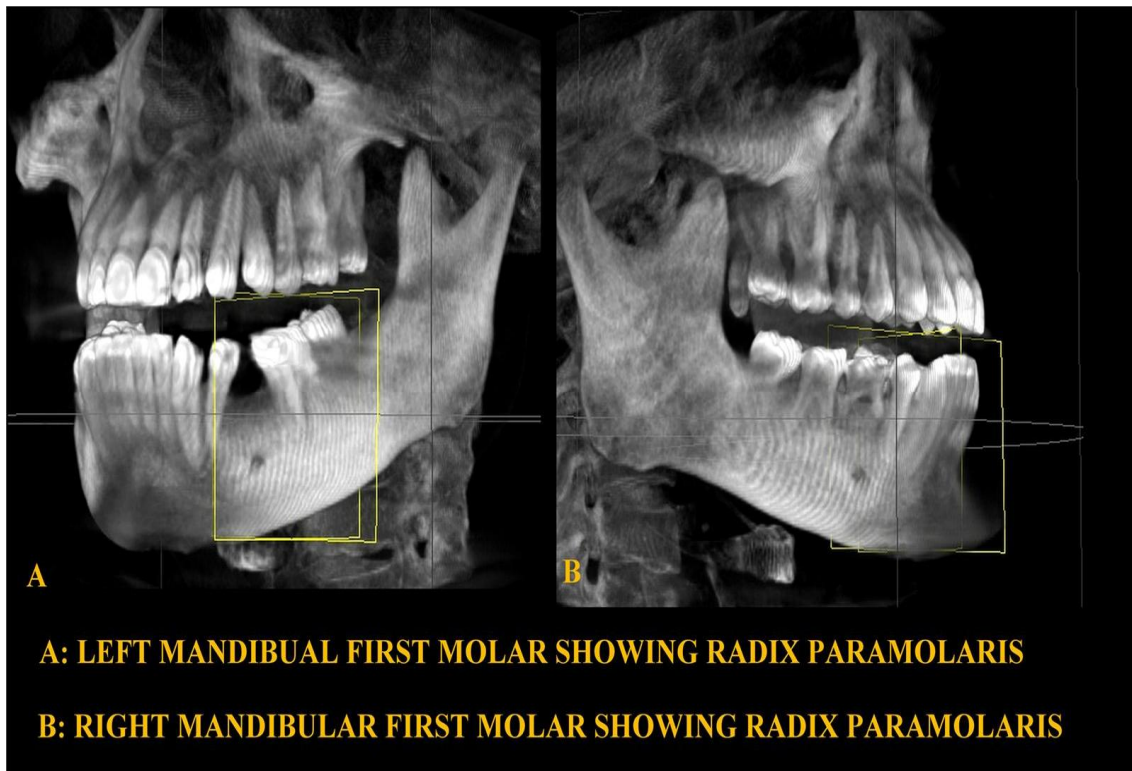


Fig. 4. CBCT evaluation

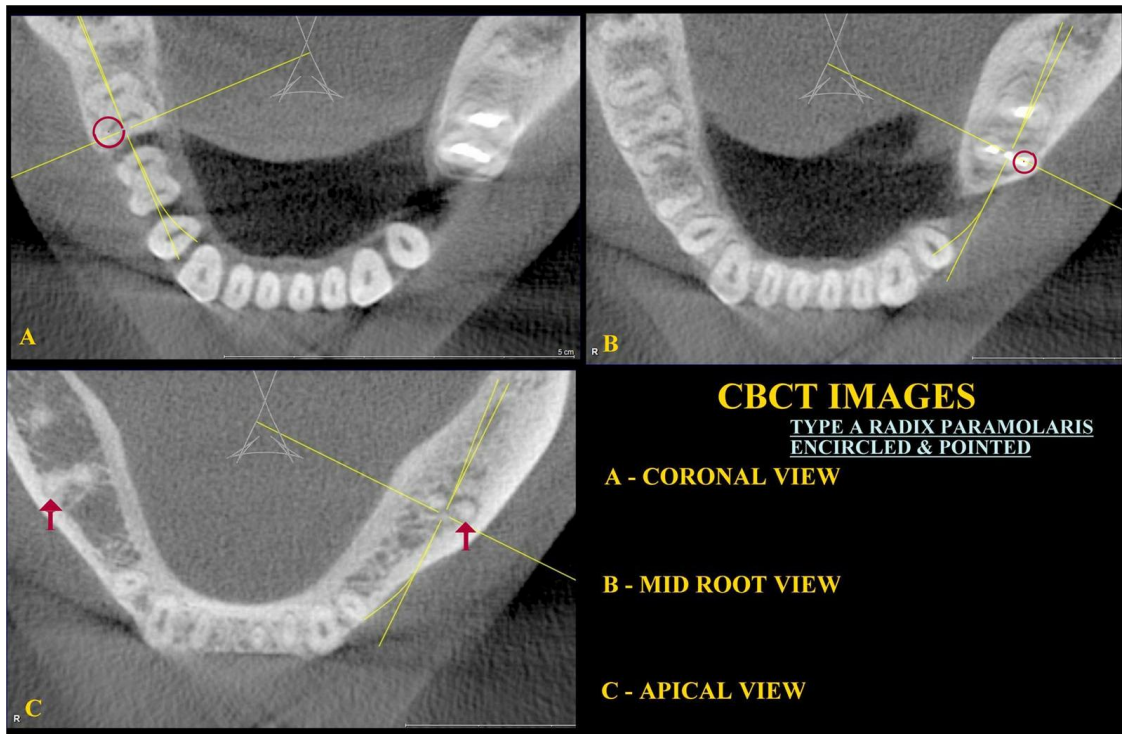


Fig. 5. CBCT; arial view in sections

#### 4. CONCLUSION

One must understand and update the knowledge regarding the advancements in the field of materials and equipment in dentistry. Though it requires some experience and a trained eye to locate the differences in the field of radiology; one must be willing to understand the importance of diagnosing perfectly in order to provide quality treatment for the patient. CBCT helps in seeing the unseen as it gives a three dimensional view. The role of modern technological up-gradation like the CBCT helps in diagnosis, treatment planning and post operative assessment in dentistry. Routine use of such recent technologies can only aid the clinicians in better oral health care for the needy. Occurrences earlier thought as rare or nonexistent are now known as possibilities in percentages. Hence, one must keep good vigilance with the backup of thorough knowledge to diagnose and treat such rare occurrences.

#### CONSENT

All authors declare that 'written informed consent was obtained from the patient for publication of this case report and accompanying images.

#### ETHICAL APPROVAL

All the authors comply with the fact that ethical clearance has been taken for this submission including patient consent.

#### COMPETING INTERESTS

Authors have declared that no competing interests exist.

#### REFERENCES

1. Tratman EK. Three-rooted lower molars in man and their racial distribution. *Br Dent J.* 1938;64:264-74.
2. Yang Y, Zhang LD, Ge JP, Zhu YQ. Prevalence of 3-rooted first permanent molars among a Shanghai Chinese population. *Oral Surg Oral Med Oral Pathol Oral Radiol Endod.* 2010;110:98-100.
3. Ingle JI, Heithersay GS, Hartwell GR. Endodontic diagnostic procedures. In: Ingle JI, Bakland LF, editors. *Endodontics.* 5<sup>th</sup> ed. London: B.C. Decker Inc. 2002;203-58.
4. Loh HS. Incidence and features of three-rooted permanent mandibular molars. *Aust Dent J.* 1990;35:437-7.

5. Garg AK, Tewari RK, Kumar A, Hashmi SH, Agrawal N, Mishra SK. Prevalence of three-rooted mandibular permanent first molars among the Indian population. J Endod. 2010;36:1302-6.
6. NB Nagaveni, KV Umashankara. Radix entomolaris and paramolaris in children: A review of the literature. J Indian Soc Pedod Prev Dent. 2012;30(2): 94-102.
7. Carlsen O, Alexandersen V. Radix paramolaris in permanent mandibular molars: Identification and morphology. Scand J Dent Res. 1991;99:189-95.
8. Peiris R, Takahashi M, Sasaki K, Kanazawa E. Root and canal morphology of permanent mandibular molars in Sri Lankan population. Odontology. 2007;95: 16-23.
9. Mannocci F, Peru M, Sherriff M, Cook R, Pitt Ford TR. The Isthmuses of the mesial root of mandibular molars: A micro-computed tomographic study. Int Endod J. 2005;38:558-63.
10. Tu MG, Huang HL, Hsue SS, Hsu JT, Chen SY, Jou MJ, et al. Detection of permanent three-rooted mandibular first molars by cone-beam computed tomography imaging in Taiwanese individuals. J Endod. 2009;35:503-7.
11. Walker RT, Quackenbush LE. Three-root lower first permanent molar in Hong - Kong Chinese. Br Dent J. 1985;159:298-9.
12. Huang RY, Cheng WC, Chen CJ, Lin CD, Lai TM, Shen EC, et al. Three-dimensional analysis of the root morphology of mandibular first molars with distolingual roots. Int Endod J. 2010;43:478-84.
13. Huang RY, Lin CD, Lee MS, Yeh CL, Shen EC, Chiang CY, et al. Mandibular distolingual root: A consideration in periodontal therapy. J Periodontol. 2007;78:1485-90.

© 2015 Abraham et al.; This is an Open Access article distributed under the terms of the Creative Commons Attribution License (<http://creativecommons.org/licenses/by/4.0>), which permits unrestricted use, distribution, and reproduction in any medium, provided the original work is properly cited.

*Peer-review history:*

*The peer review history for this paper can be accessed here:  
<http://www.sciencedomain.org/review-history.php?iid=790&id=36&aid=7096>*