



Consumption of Cattle Hide Singed with Scrap Tyre is Detrimental to the Liver, Heart and Kidney of Rats

E. C. Woko^{1,2*}, C. O. Ibegbulem² and C. S. Alisi²

¹Bioresources Development Centre Arochukwu, National Biotechnology Development Agency, P.M.B. 5118 Abuja, Nigeria.

²Department of Biochemistry, Federal University of Technology, P.M.B. 1526 Owerri, Nigeria.

Authors' contributions

This work was carried out in collaboration among all authors. All authors read and approved the final manuscript.

Article Information

DOI: 10.9734/EJNFS/2021/v13i630429

Editor(s):

(1) Dr. Hudson Nyambaka, Kenyatta University, Kenya.

Reviewers:

(1) Tania Merinas-Amo, University of Córdoba, Spain.

(2) L. Gowrishankar, Anna University, India.

(3) Christian Encina, National Agrarian University La Molina, Perú.

Complete Peer review History: <https://www.sdiarticle4.com/review-history/74143>

Original Research Article

Received 18 July 2021
Accepted 28 September 2021
Published 06 October 2021

ABSTRACT

The presence of essential amino acids in meat makes it a complete protein, this makes meat a highly sort after source of protein in the human diet. The World's demand for animal-derived protein has been projected to double by 2050. As a result there is a resultant increase in livestock industries to meet this demand. While meat is generally consumed as a source of protein, processed cattle hide popularly known as "Kanda" in southeastern Nigeria is consumed as a substitute for meat though it may not necessarily provide the same level of nutritional value with meat. The method of processing this food delicacy (*Kanda*) by singeing with scrap tyre or firewood has opened the door for heavy metal and or polycyclic aromatic hydrocarbon (PAHs) contamination, thereby putting unsuspecting consumers at health risk. This study therefore investigated the effects of consuming scrap tyre and firewood singed cattle hide on the kidney, liver and heart of male Wistar rats. The study took place for 21 days at the department of Biochemistry, Federal University of Technology Owerri. 35 rats were divided into 7 groups of 5 each, allowed to acclimatize for 7 days and fed with the cattle hide processed with scrap tyre (group 1-3) and cattle hide processed with firewood (group 4-6) while group 7 which served as control was fed with normal standard rat pellet feed. It was observed that consuming these processed hides increased

*Corresponding author: Email: wokoezechidozie@gmail.com;

the marker enzymes for heart, kidney and liver damage like lactate dehydrogenase, alanine and aspartate aminotransferases, creatine kinase and alkaline phosphatase with groups that were fed with the hide singed with scrap tyre showing severe elevations. Consuming the singed *Kanda* also significantly decreased the serum concentrations of K^+ , Na^+ , Cl^- , and significantly increased HCO_3^- and urea concentration. An examination of the organ tissues also revealed serious morphological changes. In conclusion, consuming singed *Kanda* had detrimental effects on the vital organs studied.

Keywords: Singing; firewood; orbital techniques; biochemical parameters.

1. INTRODUCTION

Processed cattle hide generally called "*Kanda*" in South East part of Nigeria is also known as "*Ponmo*" and "*Welle*" in South West part of Nigeria and Southern part of Ghana respectively [1,2]. The native way of de-hairing the hide in the South East part of Nigeria is by singeing with firewood though recently scrap tyre has started to be used. After singeing the hide is deeply scraped to remove ash (black soothe), washed with water and the finished product (*Kanda*) is cooked and served as food delicacy. Owing to the fact that tyres contain many potentially harmful substances: natural and synthetic rubber polymers, oil fillers, sulfur and sulfur compounds, phenolic resin, clay, aromatic, naphthenic and paraffinic oil, fabric, petroleum waxes, pigments such as zinc oxide and titanium dioxide, carbon black, fatty acids, inert materials and fibres made from steel, nylon, polyester or rayon [3-9], singeing *Kanda* with scrap tyres may impose the risk of depositing these elements and compounds into the *kanda*, and expose the unsuspecting consumer to health hazards. In fact, singeing *Kanda* with scrap tyre or firewood introduces the 16 U.S environmental protection

agency (EPA) priority polycyclic aromatic hydrocarbon (PAHs), heavy metals like copper (Cu) and iron (Fe) into the *Kanda* and also affects the proximate composition, derivable metabolic water and energy content of the *Kanda* [10]. The practice also releases heavy smoke and leaves a lot of waste on the soil thereby contaminating the air and the soil nearby (Plate 1 and 2).

It is on this premise that this study investigates the effects of consuming scrap tyre and firewood singed cattle hides on the vital organs (kidney, liver and heart) of Wistar rats.

Kidneys in the body are saddled with coordination of pH, potassium and salt levels, filter excess water, waste products and other impurities out of the blood, thus, they are vital to having a healthy body [11]. The healthy state of the kidneys in the body can be assessed using the concentrations of various electrolyte like bicarbonate (HCO_3^-), chloride (Cl^-), potassium (K^+), and sodium (Na^+). If the kidney(s) is damaged for any reason, its functions are affected, and the same could also be said of the heart and liver.



Plate 1. Soil contamination (pollution) from uncontrolled combustion of scrap tyre for processing of *Kanda* at Ogbor-Hill slaughter market Aba, Nigeria



Plate 2. Air and soil pollution with possible water contamination from uncontrolled combustion of scrap tyre for processing of *Kanda* at Ogbor-Hill slaughter market Aba, Nigeria

When xenobiotics are ingested by the body, it is the liver that detoxifies or metabolizes these substances; therefore the liver plays a profound role as a vital organ of the body. Injury to the liver can affect its functions. Some of the things that can cause these injuries are acute or chronic exposure to toxicants [11]. When these injuries occur, the enzymes that are found mostly in the liver leak out into the plasma and the increased concentrations of these enzymes like alanine (ALT) and aspartate (AST) aminotransferases in the plasma can be used to determine the health status of the liver [12]. ALT and AST are present in both mitochondria and cytosol of the hepatocytes, if there is any damage to the liver they leak inside the circulatory system due to altered permeability of membrane [13]; therefore, increases in plasma activities of ALT, AST, alkaline phosphatase (ALP), lactate dehydrogenase (LDH) and creatine kinase (CK) points to liver and heart diseases.

The heart in its dual role in the body is built like a muscular pump which draws blood from the tissues of the body and pumps it to the lungs; again it draws the blood from the lungs and pumps it to all the body tissues [14]. If the heart is subjected to adverse concentrations of toxicants, its roles in the body could be dangerously hampered as has been opined by some analysis which has linked heart diseases to exposures to heavy metals and metalloids even at low doses — and the greater the exposure, the greater the risk [15]. Enzymes such as lactate dehydrogenase (LDH), creatine kinase

(CK), and none enzyme protein like troponin I could be used to check the health status of the heart [16-18].

2. MATERIALS AND METHODS

2.1 Procurement and Preparation of Samples

Freshly slaughtered cattle hides used for this study were purchased from Ogbor Hill Aba slaughter market, Abia state, Nigeria and processed by the authors. The hide was then divided into two groups; A and B. Sample A was processed by singeing with scrap tyre, the resulting soothe was washed with clean water. Sample B was processed by singeing with firewood and the resulting soothe was washed off with clean water. Both freshly processed hides were then separately chopped into tiny particles and grated respectively using a locally fabricated grater. The grated particles were then dried and re-grated into smaller particles more suitable for rat consumption.

2.2 Study Design

Weaned male Wistar rats numbering 35 in total and ranging from 8-9 weeks old with an average live weight of 159.26 g was purchased and used for this study. They were kept at room temperature, fed with standard growers mash rat pellets and water for 7 days (acclimatization period) prior to commencement of the

experiment. The rats were divided into 7 groups of 5 rats each and fed for 21 study days as follow:

Group 1 rats were fed with 10 grams of cattle hide singed with scrap tyre, plus 90 grams of standard grower mash rat pellet feed and water daily for 21 days. Group 2 rats were fed with 20 grams of cattle hide singed with scrap tyre, plus 80 grams of standard grower mash rat pellet feed and water daily for 21 days. Group 3 rats were fed with 40 grams of cattle hide singed with scrap tyre, plus 60 grams of standard grower mash rat pellet feed and water daily for 21 days. Group 4 rats were fed with 10 grams of cattle hide singed with firewood, plus 90 grams of standard grower mash rat pellet feed and water daily for 21 days. Group 5 rats were fed with 20 grams of cattle hide singed with firewood, plus 80 grams of standard grower mash rat pellet feed and water daily for 21 days. Group 6 rats were fed with 40 grams of cattle hide singed with firewood, plus 60 grams of standard grower mash rat pellet feed and water daily for 21 days. Group 7 (control) rats were fed with 100 grams of standard grower mash rat pellet feed and water daily for 21 days.

2.3 Collection of Blood and Organ Samples

Blood samples were collected by orbital technique for assay of biochemical parameters using plain bottles. The blood samples were allowed to clot before it was centrifuged at 250 rpm for 15 minutes and the serum collected and used for the biochemical analysis. For the organ samples, animals were anaesthetized with dichloromethane and the heart, liver, and kidney were excised and perfused in 10% formal saline for histological studies.

2.4 Determination of Biochemical Parameters

The serum sodium ion (Na^+), potassium ion (K^+), bicarbonate ion (HCO_3^-), chloride ion (Cl^-), urea, bilirubin, aspartate aminotransferase (AST), alanine aminotransferase (ALT), alkaline phosphatase (ALP), Creatine kinase (CK), Lactate dehydrogenase (LDH), and Troponin I (Trop-I) concentrations were measured spectrophotometrically (Pharmacia LKB Ultospec III) using assay kits (Teco Anaheim, CA, USA) while Na^+/K^+ ratio and ALT/AST ratio were simply calculated. The histological analyses of the tissues were done according to the method of Drury [19].

2.5 Statistical Analysis

Results of groups are calculated as means \pm S.D. and subjected to one-way analysis of variance (ANOVA). Least significant difference (LSD) was used for post-hoc analysis at 5% significance using SPSS statistical software package- SPSS version 21 (SPSS Inc. Chicago, IL, USA).

3. RESULTS AND DISCUSSION

3.1 Results

Table 1 shows the result of serum electrolyte concentrations, serum urea concentration and sodium/potassium ratios for the six study groups and the control. Table 2 shows the serum activity of the liver enzymes, while table 3 shows the serum activity of some heart enzymes and also troponin-I. The histopathology examination of the kidney, liver and heart are shown in plates 3 to 8. Plate 3 (kidney), plate 5 (liver) and plate 7 (heart) represent rat groups (1, 2 and 3) fed with the cattle hide processed by singeing with scrap tyre and the control (group 7), while plate 4 (kidney), plate 6 (liver) and plate 8 (heart) represent rat groups (4, 5 and 6) fed with the cattle hide processed by singeing with firewood and the control (group 7).

3.1 Discussion

Because the kidneys do substantial work in maintaining the homeostasis of serum electrolytes, when the kidneys begin to lose its functions, there will be an unavoidable disorder in the concentrations of serum electrolytes and acid-base, thus, the concentrations of these various electrolytes could be used to determine the extent of kidney damages [20].

In all the study groups (1-6) low serum sodium (hyponatraemia), low serum potassium (hypokalemia), and low serum chloride (hypochloremia) concentrations were observed when compared to the control, these significant ($p>0.05$) decreases is evidence of kidney dysfunction in the study groups. As a result of kidney dysfunction sodium is not reabsorbed by the renal tubules and is therefore excreted in the urine frequently resulting in hyponatraemia; there is also a progressive failure to excrete water [21]. Sodium is an essential electrolyte in the human body; it plays basic roles in maintaining the concentration and volume of the extracellular

Table 1. Serum electrolyte/ kidney function test

	Group 1 (10 g SWST)	Group 2 (20 g SWST)	Group 3 (40 g SWST)	Group 4 (10 g SWFW)	Group 5 (20 g SWFW)	Group 6 (40 g SWFW)	Group 7 (Control)
Na⁺ (mEq/L)	82.33±4.15 ^a	85.93±4.12 ^a	45.60±3.53 ^b	82.63±9.97 ^a	66.90±2.95 ^c	89.00±3.83 ^a	109.17±18.49 ^d
K⁺ (mEq/L)	14.47±1.88 ^a	15.30±3.28 ^a	7.13±2.90 ^b	12.93±1.64 ^a	12.03±3.11 ^a	13.03±2.39 ^a	20.10±1.14 ^c
HCO₃⁻ (mmol/l)	12.87±1.34 ^{a,d}	9.97±0.93 ^a	27.67±2.54 ^b	17.60±2.10 ^c	17.20±5.64 ^{c,d}	17.60±1.04 ^c	17.70±2.17 ^c
Cl⁻ (mmol/l)	13.77±1.26 ^{a,b,c}	12.57±0.59 ^{a,c}	10.70±1.25 ^a	15.10±3.73 ^{b,c}	14.70±1.81 ^{b,c}	12.37±2.46 ^{a,c}	17.13±1.72 ^b
Urea (mg/dl)	36.00±1.73 ^{a,e}	45.67±2.52 ^{b,d}	52.00±6.00 ^b	39.00±7.97 ^{a,d}	40.00±4.58 ^{a,d}	29.33±1.53 ^{c,e}	25.67±2.52 ^c
Na⁺/K⁺ (mEq/L)	5.73±0.52 ^a	5.82±1.47 ^a	7.25±3.25 ^a	6.45±1.06 ^a	5.85±1.76 ^a	6.99±1.34 ^a	5.44±0.88 ^a

Values are means ± standard deviation of triplicate determinations. Values on the same row with the same superscript letter are not significantly ($p>0.05$) different. SWST = hide singed with scrap tyre;SWFW = hide singed with firewood.

Table 2. Liver function test result

	Group 1 (10 g SWST)	Group 2 (20 g SWST)	Group 3 (40 g SWST)	Group 4 (10 g SWFW)	Group 5 (20 g SWFW)	Group 6 (40 g SWFW)	Group 7 (Control)
BIL (mg/dl)	0.59±0.03 ^{a,c}	0.53±0.13 ^{a,c,d}	1.03±0.21 ^b	0.66±0.04 ^a	0.48±0.07 ^{a,c,d}	0.45±0.07 ^{c,d}	0.37±0.06 ^d
AST (lu/l)	32.67±4.62 ^{a,c}	38.67±3.06 ^a	73.33±15.04 ^b	44.67±13.32 ^a	40.67±1.15 ^a	45.67±7.09 ^a	20.00±4.58 ^c
ALT (lu/l)	15.33±3.06 ^{a,d}	21.00±4.00 ^{a,c,d}	52.67±14.01 ^b	16.00±2.00 ^{a,d}	34.00±7.81 ^c	28.33±9.45 ^{a,c}	13.67±3.51 ^d
ALP (lu/l)	22.00±5.29 ^a	24.33±1.53 ^a	48.00±29.60 ^b	27.33±3.06 ^a	19.67±1.15 ^a	20.67±4.16 ^a	21.00±2.65 ^a
ALT/AST (lu/l)	0.48±0.15 ^{a,b}	0.55±0.13 ^{a,b,c}	0.72±0.17 ^{a,c}	0.39±0.18 ^b	0.84±0.21 ^c	0.62±0.15 ^{a,b,c}	0.70±0.18 ^{a,c}

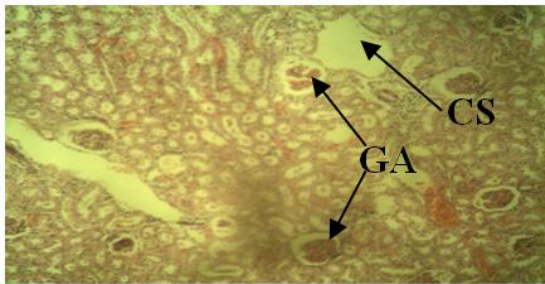
Values are means ± standard deviation of triplicate determinations. Values on the same row with the same superscript letter are not significantly ($p>0.05$) different. SWST = hide singed with scrap tyre;SWFW = hide singed with firewood

Table 3. Heart function test

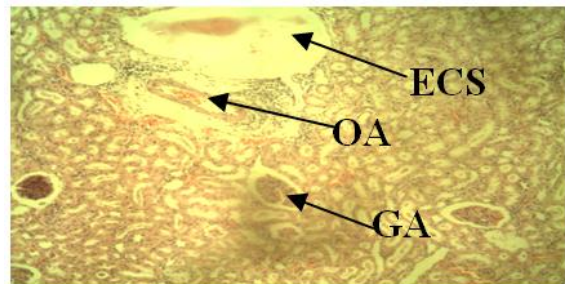
	Group 1 (10 g SWST)	Group 2 (20 g SWST)	Group 3 (40 g SWST)	Group 4 (10 g SWFW)	Group 5 (20 g SWFW)	Group 6 (40 g SWFW)	Group 7 (Control)
CK (u/l)	71.87±2.21 ^a	100.13±12.43 ^a	221.93±83.41 ^b	59.33±3.42 ^a	74.63±21.20 ^a	68.03±5.89 ^a	54.60±5.26 ^a
LDH (u/l)	168.77±3.75 ^{a,c,e}	202.13±35.75 ^{a,b}	212.43±37.70 ^b	150.63±22.26 ^{c,d,e}	119.43±20.45 ^{d,e}	163.17±16.01 ^{a,c,e}	127.43±6.63 ^e
TROP-I (ng/ml)	0.80±0.03 ^{a,b}	0.90±0.08 ^b	1.06±0.12 ^c	0.68±0.04 ^{a,d,e}	0.63±0.12 ^{d,e}	0.73±0.06 ^{a,d}	0.55±0.09 ^e

Values are means ± standard deviation of triplicate determinations. Values on the same row with the same superscript letter are not significantly ($p>0.05$) different. SWST = hide singed with scrap tyre; SWFW = hide singed with firewood

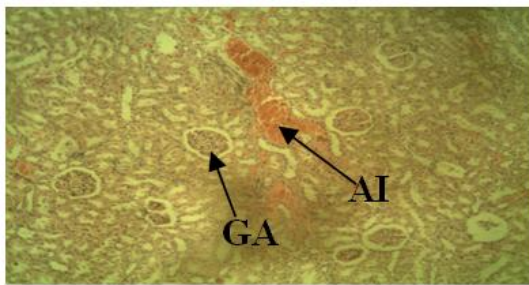
Histology study of rat tissue



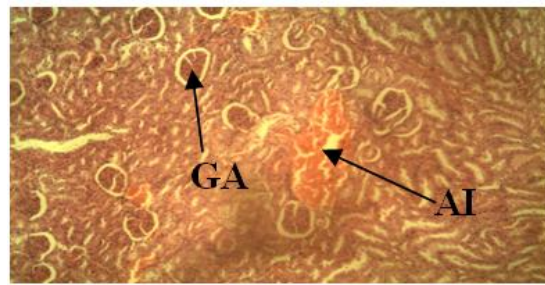
Group 1. Fed with 10 g of Cattle Hide processed with scrap tyre plus 90 g of standard growers marsh rat pellet feed and water



Group 2. Fed with 20 g of Cattle Hide processed with scrap tyre plus 80 g of standard growers marsh rat pellet feed and water



Group 3. Fed with 40 g of Cattle Hide processed with scrap tyre plus 60 g of standard growers marsh rat pellet feed and water



Group 7 (control): Fed with 100% standard growers mash pellets feed and water

Plate 3. Photomicrograph of the kidney tissues of Wistar rats (male) fed with different concentrations (10 g, 20 g, and 40 g) of the Cattle hide processed scrap tyre (group 1-3) respectively. Stain H and E. x100;CS = cystic space; GA = glomerula atrophy; ECS = enlarged cystic space; OA = occluded artery; AI = acute inflammation

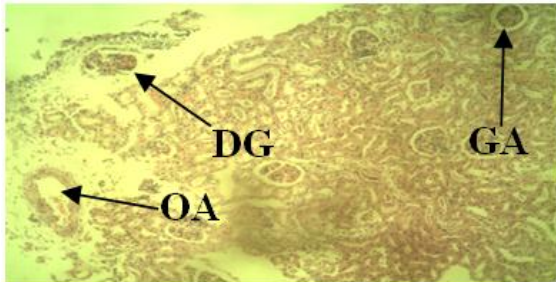
fluid (ECF) and accounts for most of the osmotic activity of the plasma. The serum levels of sodium are maintained by feedback loops involving the kidney, the adrenal glands and the hypothalamus. When the serum sodium is low as observed in the study groups (usually because total body water is high), antidiuretic hormone (ADH) is suppressed and dilute urine is excreted. In addition, the kidney produces rennin which stimulates aldosterone production that decreases the excretion of sodium in the urine, therefore increasing sodium levels in the body. It could be therefore that the rats in the study groups due to kidney failure or damage could not among other things produce rennin which in turn caused sodium to be excreted in the urine without reabsorption, a condition that resulted to the low serum sodium (hyponatraemia) as observed in all the study groups. Group 3 had the most critical condition of hyponatraemia, hypokalemia and hypochloremia, this suggests that

consuming scrap tyre-singed cattle hide at a higher concentration poses greater health risk.

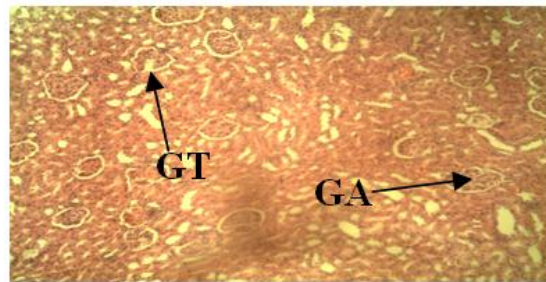
Hypokalemia is a metabolic imbalance characterized by extreme low potassium levels in the blood [22]. Under normal circumstances, the kidneys are responsible for excreting 90% of the potassium that is consumed daily with the remaining 10% excreted in the feces. Abnormalities of serum potassium are common in patients with chronic kidney disease (CKD), although hyperkalemia (high serum potassium) is also a well-recognized complication of CKD, the prevalence rates of hyperkalemia (14% - 20%) and hypokalemia (12% - 18%) are similar [23]. When kidneys are functioning normally the amount of K^+ in the diet is sufficient for use by the body and the excess is usually excreted through urine and sweat. When hypokalemia occurs (as observed in the study groups), there is an imbalance resulting from a dysfunction in

the normal process or rapid loss of urine or sweat without replacement of sufficient potassium. Hypokalemia has also been reported to impair the ability of the kidneys to concentrate urine, resulting in excessive urination (polyuria)

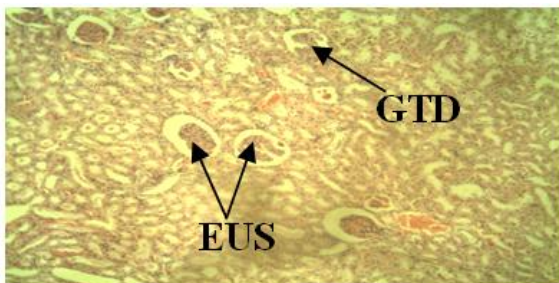
and excessive thirst (polydipsia). The excessive excretion of K⁺ in the urine (kaliuresis) which caused the hypokalemia in the study groups may be evidence of kidney disorders in the study groups among other factors [22].



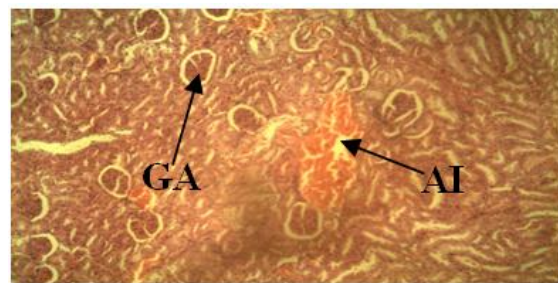
Group 4. Fed with 10 g of Cattle Hide processed with firewood plus 90 g of standard growers marsh rat pellet feed and water



Group 5. Fed with 20 g of Cattle Hide processed with firewood plus 80 g of standard growers marsh rat pellet feed and water

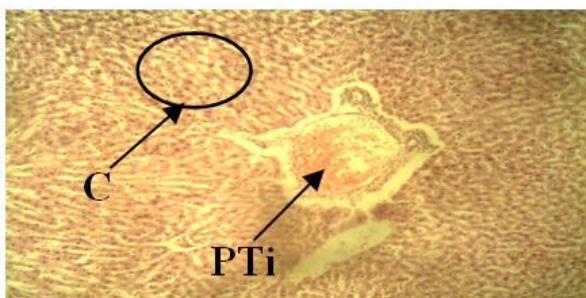


Group 6. Fed with 40 g of Cattle Hide processed with firewood plus 60 g of standard growers marsh rat pellet feed and water

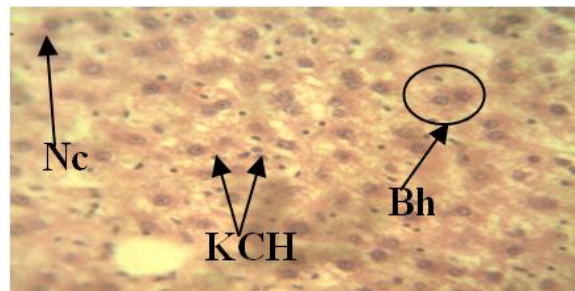


Group 7 (control). Fed with 100% standard growers mash pellets feed and water

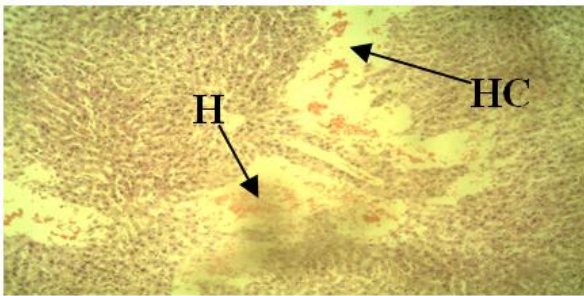
Plate 4. Photomicrograph of the kidney tissues of Wistar rats (male) fed with different concentrations (10 g, 20 g, and 40 g) of the Cattle hide processed with firewood (group 4-6) respectively while group 7 is the control. Stain: H and E. ×100;GA = glomerular atrophy;DG = damaged glomeruli;OA = occluded artery;GT = glomerular tuft;GTD = glomerular tuft degeneration;EUS = enlarged urinary space;AI = acute inflammation



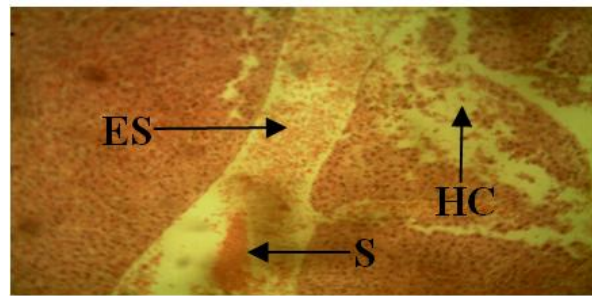
Group 1. Fed with 10 g of Cattle Hide processed with scrap tyre plus 90 g of standard growers marsh rat pellet feed and water



Group 2. Fed with 20 g of Cattle Hide processed with scrap styre plus 80 g of standard growers marsh rat pellet feed and water




Group 3. Fed with 60 g of Cattle Hide processed with scrap styre plus 40 g of standard growers marsh rat pellet feed and water

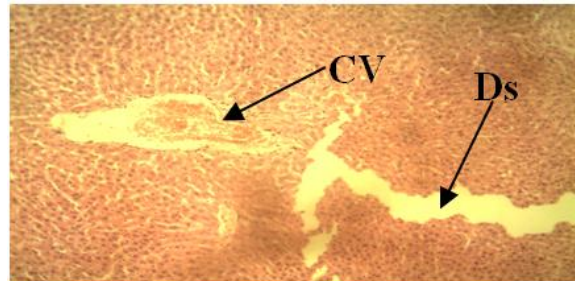


Group 7 (control): Fed with 100% standard growers mash pellets feed and water

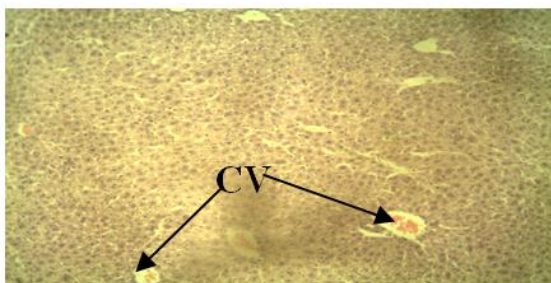
Plate 5. Photomicrograph of the liver tissues of Wistar rats (male) fed with different concentrations (10 g, 20 g, and 40 g) of the Cattle hide processed with scrap tyre, while group 7 is the control; Stain: H and E. $\times 100$; C = Cytoplasmic vacoulation; PTi = Portal triad inflammation; Nc = Necrotic cells; Bh = Binucleation of hepatocytes; KCH = Kupfer cells hyperplasia; H = Hyperemia; HC = distortion of hepatic chord; S = Congestion of sinusoid; ES = enlarged sinusoid



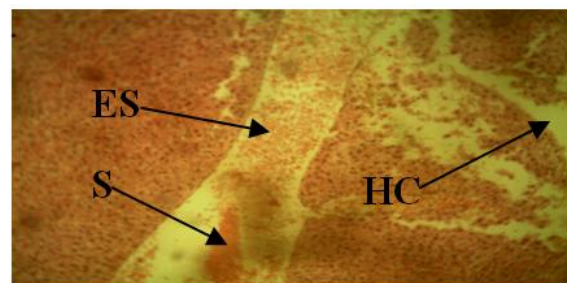
Group 4. Fed with 10 g of Cattle Hide processed with firewood plus 90 g of standard growers marsh rat pellet feed and water.



Group 5. Fed with 20 g of Cattle Hide processed with firewood plus 80 g of standard growers marsh rat pellet feed and water

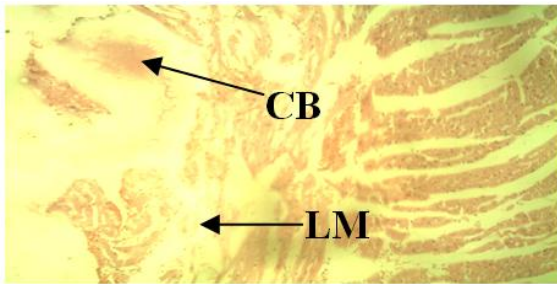


Group 6. Fed with 40 g of Cattle Hide processed with firewood plus 60 g of standard growers marsh rat pellet feed and water.

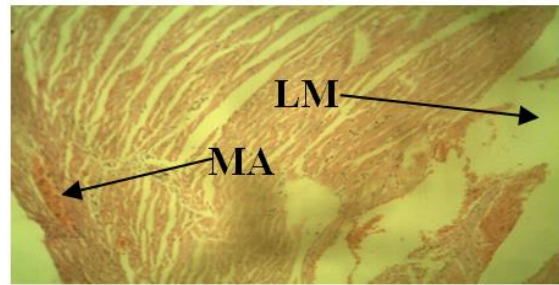


Group 7 (control). Fed with 100% standard growers mash pellets feed and water.

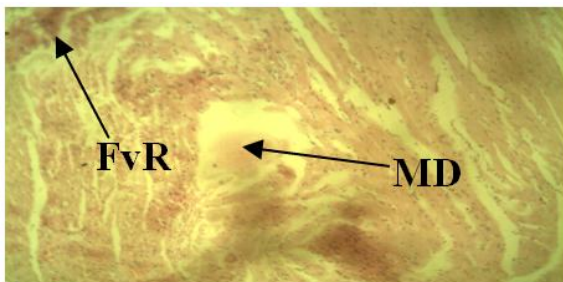Plate 6. Photomicrograph of the liver tissues of Wistar rats (male) fed with different concentrations (10 g, 20 g, and 40 g) of the Cattle hide processed with firewood (group 4-6) respectively while group 7 is the control. Stain: H and E. $\times 100$; N = multi focal necrosis; CV = congested central vein; DS = dilation of sinusoid; HC = distortion of hepatic chord; S = Congestion of sinusoid; ES = enlarged sinusoid.



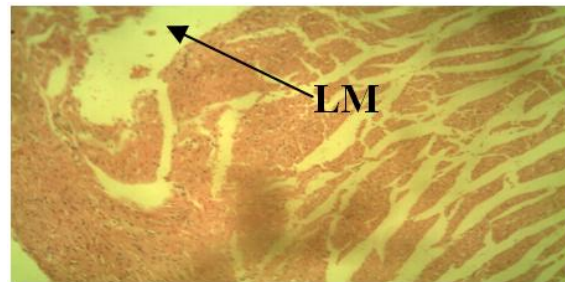
Group 1. Fed with 10 g of Cattle Hide processed with scrap tyre plus 90 g of standard growers marsh rat pellet feed and water



Group 2. Fed with 20 g of Cattle Hide processed with scrap tyre plus 80 g of standard growers marsh rat pellet feed and water



Group 3. Fed with 40 g of Cattle Hide processed with scrap tyre plus 60 g of standard growers marsh rat pellet feed and water

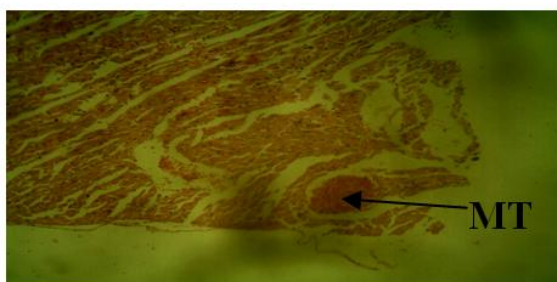


Group 7 (control). Fed with 100% standard growers mash pellets feed and water.

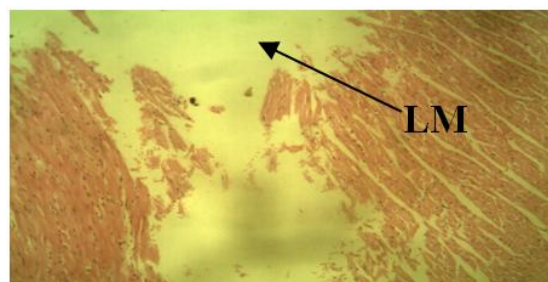
Plate 7. Photomicrograph of the heart tissues of Wistar rats (male) fed with different concentrations (10 g, 20 g, and 40 g) of the Cattle hide processed scrap tyre (group 1-3) respectively. Stain: H and E. $\times 100$; CB = congested blood; LM = loss of myofibres; MA = minor arthritis; FvR = fibrovascular response; MD = myocardial degeneration.

According to Zahra, the extremely high bicarbonate and low chloride (hypochloremia) in the study group 3 is almost certainly due to metabolic alkalosis [24]. This alkalosis is maintained and potentiated by the kidneys' inability to excrete excess bicarbonate because of hypochloremia. Hypokalemia is frequently associated with metabolic alkalosis because kaliuresis is increased in response to low H^+ concentration [24]. All the groups fed with the hide singed with firewood (4-6) showed no significant ($p < 0.05$) difference compared to the control while the groups (1-2) fed with the hide singed with scrap tyre showed significant ($p < 0.05$) decrease in serum bicarbonate concentration except group 3 which showed significant ($p < 0.05$) increase compared to the control and other study groups. Elevated serum bicarbonate concentration has been linked with heart failure intensification and death in patients with chronic kidney disease in a frightening rate [25]. Also metabolic acidosis leads to chronic kidney disease (CKD); in elderly CKD patients,

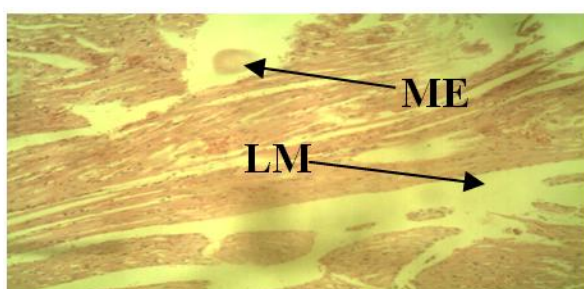
serum bicarbonate levels is independently associated with CKD progression, and a high serum bicarbonate level is associated with a low risk of CKD progression provided it is within range [26]. There was an observed significant ($p < 0.05$) decrease in serum chloride concentrations (hypochloremia) of study groups 2, 3 and 6 when compared to the control. Chloride (Cl^-) is the major anion associated with sodium in extracellular fluid (ECF). The kidneys are charged with the maintenance of total body chloride balance. The kidneys comfortably maintain homeostasis because each of the kidney is composed of about 1 million functional units and nephrons. Part or all of the Cl^- filtered by the initial portion of each of the nephron and the glomerulus, will be reabsorbed as a result of both active and passive transport processes along the tubules comprising each nephron. The ability of the nephrons to reabsorb chloride maintains the serum (and ECF) chloride concentration within a narrow range [27]. The inability of the kidney to reabsorb the chloride led



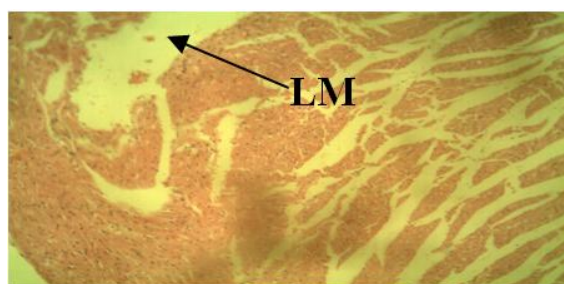
Group 4. Fed with 10 g of Cattle Hide processed with firewood plus 90 g of standard growers marsh rat pellet feed and water



Group 5. Fed with 20 g of Cattle Hide processed with firewood plus 80 g of standard growers marsh rat pellet feed and water



Group 6. Fed with 40 g of Cattle Hide processed with firewood plus 60 g of standard growers marsh rat pellet feed and water



Group 7 (control). Fed with 100% standard growers mash pellets feed and water

Plate 8. Photomicrograph of the heart tissues of Wistar rats (male) fed with different concentrations (10 g, 20 g, and 40 g) of the Cattle hide processed with firewood (group 4-6) respectively while group 7 is the control. Stain: H and E. $\times 100$; MT = Minor thrombosis; ME = minor edema; LM = loss of myofibres

to the hypochloremia observed in groups 2, 3, and 6. This could be attributed to over-hydration and or congestive heart failure where chloride is retained with sodium retention but is diluted by excess total body water.

Except group 6, all the study groups when compared to the control showed significant ($p < 0.05$) increase in their serum urea concentrations with group 3 having the highest concentration. Urea is a waste product of protein metabolism and digestion formed in the liver and excreted by the kidneys in urine. Therefore urea is directly associated to the metabolic function of the liver and the excretory function of the kidney. Kidney disease has been associated with reduced urea excretion and its consequent rise in the blood concentration as observed in the study groups [28]. In fact, nearly all renal diseases cause an inadequate excretion of urea, which in turn causes the blood concentration to rise above normal [29-32]. Groups 1, 2, 3, 4 and 5 had significantly increased ($p < 0.05$) urea concentration compared to the control. There was no significant ($p < 0.05$) difference in the

sodium-potassium ($\text{Na}^+\text{-K}^+$) ratio of all the study groups compared to the control or among themselves.

When environmental exposure to harmful chemicals occur, the liver has been considered the major target organ for most of these chemicals indicted in eliciting toxic effects [33]. Using serum bilirubin concentration, AST, and ALP the integrity of the liver could be evaluated. All the study groups except 2, 5 and 6 showed significant ($p < 0.05$) increase in the serum bilirubin concentration when compared to the control. Serum bilirubin is an endogenous anion derived from hemoglobin degradation from the red blood cell, abnormal levels in the serum is an indication of underlying liver disease as observed in study groups 1, 3 and 4 [34]. The observed increment in the serum activities of AST in serum of group 2, 3, 4, 5, and 6 may be mainly due to the leakage of these enzymes from the liver cytosol into the blood stream as a result of liver damage (necrosis as shown in the histopathology study of the liver tissues). Study groups 3, 5, and 6 showed significant ($p < 0.05$)

increase in their serum alanine aminotransferase (ALT) when compared to the control. ALT is found predominately in the liver; lesser quantities are found in the kidneys, heart, and skeletal muscle. Injury or disease affecting the liver functioning part of the organ (parenchyma) will cause a release of this hepatocellular enzyme into the bloodstream, therefore elevating the ALT serum levels. Most ALT serum level increases are due to liver dysfunction. ALT serum levels are quite specific markers for hepatocellular disease indicators, mildly increased levels results to myocardial infarction, moderately increased level results to hepatic tumor while significantly increased levels result to hepatic necrosis as observed in the liver tissue examination of groups 2 and 4 rats [32]. The ALT/AST ratios of only study groups 1, and 4 were significantly ($p < 0.05$) low compared to the control and is evidence of hepatocellular disease. In viral hepatitis the ALT/AST ratio is greater than 1, while in hepatocellular disease the ratio is less than 1 u/L [32]. Group 3 rats are the only group with a significant ($p < 0.05$) increase in alkaline phosphatase (ALP) and creatine kinase (CK) concentrations. Increased levels of ALP as observed with group 3 may signify primary cirrhosis, primary or metastatic liver tumor, and myocardial infarction among others [32]. Study groups 2, and 3 showed significant ($p < 0.05$) increase in the serum lactate dehydrogenase (LDH) concentration compared to the control while groups 1, 4, 5 and 6 showed no significant ($p < 0.05$) difference compared to the control. Groups 1, 2, 3 and 6 showed significant increase ($p < 0.05$) in their Troponin-I concentration when compared to the control. Cardiac troponins are the biochemical markers for cardiac disease [32]. Cardiac troponins become elevated sooner and remain elevated longer than CK. This expands the time window of opportunity for diagnosis and thrombolytic treatment of myocardial injury. Any rise in creatine levels is only observed if there is marked damage to functional nephrons [35].

Plate 3 shows the photomicrograph of kidney tissues for groups 1 to 3 which were fed with the hide singed with scrap tyre and the control (group 7). In group 1, clear glomerular atrophy was observed with minor cystic space. According to Leh, glomerular atrophy is an acquired reduction of the size of the capillary loops of the kidney associated with wasting as from death and reabsorption of cells, reduced function or malfunction, or hormonal changes [36]. Group 2 showed enlarged cystic space with presence of

congested blood. The blood vessels especially the artery were also occluded. According to another report, simple kidney cysts are abnormal fluid-filled sacs that form in the kidneys [37]. The report further stated that the cause of simple kidney cysts is not fully understood though obstruction of tubules (tiny structures within the kidney that collect urine) or deficiency of blood supply to the kidneys may play a role [37]. Group 3 showed acute inflammations and glomerular atrophy. While in group 7 (control) the glomeruli were intact although minor acute inflammation was observed.

Plate 4 shows the photomicrograph of kidney tissues for groups 4 to 6 fed with the hide singed with firewood and the control (group 7). In group 4 the glomeruli were damaged with loss of glomerular contents, there was also the presence of arteries with minor occlusion. Renal artery occlusion (RAO) is a rare but significant cause of kidney loss which may be caused by renal artery thrombosis [38]. Group 5 showed minor atrophy of the glomerular tuft with slight distention of the Bowman's space. In group 6 atrophy of glomerular tuft appeared more severe with enlarged urinary space. While in group 7 (control) the glomeruli were intact although minor acute inflammation was observed.

Plate 5 showed the photomicrograph of liver tissues for groups 1, 2 and 3 fed with the hide singed with scrap tyre and the control (group 7). In group 1, portal triad inflammation was observed with cytoplasmic vacuolations. Vacuolation of the cytoplasm is a famous morphological phenomenon observed in mammalian cells after exposure to bacterial or viral pathogens as well as to various natural and artificial low molecular weight compounds. Vacuolation often accompany necrosis; however, its role in necrotic process remains unclear [39]. In the liver, as in every vascularized tissue, cell death (necrosis) evokes an inflammatory reaction which is morphologically manifested by the appearance of inflammatory cells together with edema and congestion around parenchymal cells which in the case of the liver are damaged hepatocytes or damaged bile ducts or damaged blood vessels. Portal inflammation may involve all or some portal fields. In group 2, Kupfer cell hyperplasia, binucleation (double nuclei) of hepatocytes and necrosis of the hepatocytes was observed. Kupfer cells reside within the lumen of the liver sinusoids; therefore they are the first to be exposed to materials absorbed from the

gastrointestinal tract [39]. Hepatocytes are indeed the major cell type in the liver, they might represent primary modulators of hepatic immunity, especially in the setting of chronic liver injury, where non-injured hepatocytes in close proximity are predisposed to inflammatory mediators as bystanders [40]. Group 3 showed distortion of the hepatic chords with loss of hepatocytes, and hyperemia (the buildup of blood). Distortion of hepatic chords is certainly a sign of cirrhosis [40]. Cirrhosis is a consequence of chronic liver disease characterized by replacement of liver tissue by dense fibrous scar tissue as well as regenerative nodules formation which result in widespread distortion of normal hepatic architecture [40]. The control (group 7) showed congestion, and enlargement of the sinusoid, with distortion of hepatic cord. The reason for these occurrences in the control is inexplicable.

Plate 6 showed photomicrograph of liver tissues for groups 4, 5, and 6 fed with the hide singed with firewood and group 7 (control). In group 4, multifocal necrosis was observed. Group 5 showed enlargement of the sinusoids and congestion of the central vein. In group 6 the central veins were also congested, while group 7 (control) showed congestion, and enlargement of the sinusoid, with distortion of hepatic cord.

Plate 7 shows the photomicrograph of the heart tissues for groups 1 to 3 fed with the hide singed with scrap tyre and the control (group 7). In Group 1, there was typical cardiac muscle (myocardium), blood congestion and degeneration of the myofibres which led to myonecrosis. In Group 2, minor arteritis appeared due to inflammatory infiltrates of the lymphocytes, and neutrophils which led to narrowing and obliteration of the lumen which is still at the early stage of arteritis. Loss of myofiber was also observed. Group 3 showed fibrovascular responses with prominent granulation tissues and myocardial degeneration due to circulatory disturbances especially infarction which creates hypoxia and death of myofibers. In Group 7, there was edema and the presence of diffused degenerated myofibers which are observable conditions that led to cardiomyopathy. The above condition showed progressive murine cardiomyopathy, and why these occurred in the control is inexplicable.

Plate 8 shows the photomicrograph of the heart tissues for groups 4 to 6 fed with the hide singed with firewood and the control (group 7). In group

4, there appeared the presence of minor thrombosis with typical endocardial myxomatous change usually consisting of focal or diffuse thickening due to presence of myxomatous tissue. In Groups 5 and 6, there was an observed degeneration of the myofibers. In Group 7, there was edema and the presence of diffused degenerated myofibers which are observable conditions that led to cardiomyopathy.

4. CONCLUSION

The consumption of cattle hides singed with firewood or scrap tyre as sources of fuel poses significant health hazard to the vital organs of the body like kidney, liver and heart with the hide singed with scrap tyre posing the higher level of risk. Consuming these hides could cause such health challenges as hyponatraemia, hypokalemia, hypochloremia, chronic kidney disease (CKD), cirrhosis, congestive heart failure etc. With the findings of this study, it is advised that eating of scrap tyre or firewood singed cattle hides (*Kanda, Ponmo, or Welle*) should be discouraged.

ETHICAL APPROVAL

As per international standard or university standard written ethical approval has been collected and preserved by the authors.

KEY MESSAGES

There is a danger of contaminating hides when they are singed with tyre or firewood. This contamination makes the hide unhealthy for consumption and has been shown by this study to cause damages to the severity of the heart, liver and kidney of Wistar rats studied.

DISCLAIMER

The products used for this research are commonly and predominantly used products in our area of research and country. There is absolutely no conflict of interest between the authors and producers of the products because we do not intend to use these products as an avenue for any litigation but for the advancement of knowledge. Also, the research was not funded by the producing company rather it was funded by personal efforts of the authors.

COMPETING INTERESTS

Authors have declared that no competing interests exist.

REFERENCES

1. Obiri-Danso K, Hogarh JN, Antwi-Agyei P. Assessment of the contamination of singed hides from cattle and goats by heavy metals in Ghana. *African Journal for Environmental Science and Technology*. 2008;2(8):217-221.
2. Okiei W, Ogunlesi M, Alabi F, Osiughwu B, Sojinrin A. Determination of toxic metal [2] concentrations in flame treated meat products, Ponmo. *African Journal of Biochemistry Research*. 2009;3(10): 332-339.
3. Kirk BL. Potential dioxin release associated with tyre derived fuel use in a cement Kiln Gallatin county, Montana. University of Idaho, Principles of Environmental Toxicology; 2000. [Online] Available:http://www.webpages.uidaho.edu/etox/resources/case_studies/dioxtir3.pdf [Accessed on 8th August, 2017]
4. Air Resources Board. Report on air emissions from waste tyre burning in California. California Environmental Protection Agency; 2005. [Online] Available: http://www.arb.ca.gov/ei/tyre/2005_tyre_burning_report.pdf [Accessed on 10th January, 2017]
5. Luch A. The carcinogenic effects of polycyclic aromatic hydrocarbons. Imperial College Press, London. 2005;489.
6. Asthana SR, Patil RK. Use of alternative fuels in Indian cement industry. *Adv Energy Res*. 2006;1: 347-350.
7. Hassanien MA. Risk assessment of atmospheric toxic pollutants over Cairo, Egypt. *Cairo Univ. J. Environ. Sci*. 2007;5:37-57.
8. Haines G, McCulloch M, Wong R. End-of-life tyre management LCA: A comparative analysis for Alberta recycling management authority. The Pembina Institute; 2010. [Online] Available:<http://www.albertarecycling.ca/docs/about-us/lifecycle-assessment-final-report---tyres.pdf?Status=Tempandsfvrsn=2> [Accessed on September 8th 2017]
9. Ziadat A, Sood E. An environmental impact assessment of the open burning of scrap tyres. *Journal of Applied Sciences*. 2014;14(21): 2695-2703.
10. Woko EC, Ibegbulem CO, Alisi CS. Polycyclic aromatic hydrocarbon, heavy metal, derivable metabolic water and energy content of cattle hides processed by singeing. *IOSR Journal of Environmental Science, Toxicology and Food Technology (IOSR-JESTFT)*. 2021;14(7):07-13.
11. Johnson S. Kidney health and kidney disease basics; 2017. [Online] Available:<https://www.healthline.com/health/kidney-disease> [Accessed on December 5th, 2019]
12. Alisi CS, Onyeze GO, Ojiako OA, Osuagwu CG. Evaluation of the protective potential of chromolaena odorata linn. extract on carbon tetrachloride-induced oxidative liver damage. *International Journal of Biochemistry Research & Review*. 2011;1(3): 69-81.
13. Gao HY, Li GY, Lou MM, Li XY, Wei XY, Wang JH. Hepatoprotective effect of Matrine salvianolic acid B salt on Carbon Tetrachloride-Induced Hepatic Fibrosis. *Journal of Inflammation*. 2012;9(16). DOI <https://doi.org/10.1186/1476-9255-9-16>
14. Weinhaus AJ, Roberts KP. Anatomy of the human heart. In: Iazzo PA (eds) *Handbook of cardiac anatomy, Physiology, and devices*. Humana press Inc., Totowa, NJ. 2005;51-79.
15. Rettner R. Heavy Metals May Pose Another Health Risk: Heart Disease. [Online] Available:<https://www.livescience.com/63467-heavy-metals-heart-disease.html> [Accessed on December 5th, 2019]
16. Kopel E, Kivity S, Morag-Koren N, Segev S, Sidi Y. Relation of serum lactate dehydrogenase to coronary artery disease. *American Journal of Cardiology*. 2012;110(12): 1717–1722.
17. Gupta A, Akki A, Wang Y, Leppo MK, Chacko VP, Foster DB, et al. Creatine kinase-mediated improvement of function in failing mouse hearts provides causal evidence the failing heart is energy starved. *Journal of Clinical Investigation*. 2011;122(1): 291-302.
18. Dasgupta A, Wahed A. Cardiac markers. In *Textbook of Clinical chemistry, immunology and laboratory quality control: a comprehensive review for board preparation, certification, and clinical practice*. Elsevier publishers, San Diego, CA. 2014;127-144.
19. Drury RA, Wallington A, Cameroun SR. In *Carleton's Histological Techniques*. Oxford University Press, New York. 1967;1-420.

20. Tsering D, Qi Q. Electrolyte and acid-base disorders in chronic kidney disease and end stage kidney failure. *Blood Purit.* 2017;43:179-188.
21. Chatterjea MN, Rana S. Metabolism of minerals and trace elements. In: *Textbook of Medical Biochemistry (7th ed)* New Delhi: Taypee Brothers. 2007;570–594.
22. National Organisation for Rare Disorder (NORD). Hypokalemia. Rare disease database; 2003. Available: <https://rarediseases.org/rare-diseases/hypokalemia> [Accessed On 25th July, 2018]
23. Gilligan S, Raphael LK. Hyperkalemia and hypokalemia in CKD: prevalence, risk factors, and clinical outcomes. *Advances in Chronic Kidney Disease Journal* 2017. Available: <https://doi.org/10.53/j.ackd.2017.06.004> [Accessed on 30th December, 2017]
24. Zahra SY, Hong KL, Mark AC. Hyponatremia, hypokalemia, hypochloremia, and other abnormalities. *Clinical chemistry.* 2016;62: 6.
25. Khitan ZJ. Elevated serum bicarbonate concentration in chronic kidney disease: A call to find the cause. *Journal of the American Heart Association.* 2015;4(4): e001997.
26. Kanda E, Masumi AI, Yoshida M, Kuriyama R, Shigai T. High serum bicarbonate level within the normal range prevents the progression of chronic kidney disease in elderly chronic kidney disease patients. *BMC Nephrology.* 2013;14(4): 1471-2369.
27. Morrison G. Serum Chloride. In: Walker HK, Hall WD, and Hurst JW. Editors. *Clinical Methods: The History, Physical, and Laboratory Examinations.* 3rd edition. Boston: Butterworths; 1990. Available: <https://www.ncbi.nlm.nih.gov/books/NBK309/> [Accessed on 10th January, 2018]
28. Higgins C. Urea and the clinical value of measuring blood urea concentration; 2016. [Online] Available: www.acutecare.org [Accessed on March 21th, 2018]
29. Gnanamani A, Sudha M, Deepa G, Sudha M, Deivanai K, Sadulla S. Hematological and biochemical effects of polyphenolics in animal models. *Chemosphere.* 2008;72:1321-1326.
30. Hayes A. Principles and methods of toxicology. New York: Informa Healthcare USA, Inc. 2008; 65.
31. Mukinda JT, Eagles FK. Acute and sub-chronic oral toxicity profile of the aqueous extract of polygala fruticosa in female mice and rats. *J. Ethnopharmacol.* 2010;128:236-240.
32. Dickson A. Lab values and their meanings. Fraser Health Authority, and Professional Practice Integration Manual. 2011;7-19.
33. Kataria A, Trasande L, Trachtman H. The effects of environmental chemicals on renal function. *Nat Rev Nephrol.* 2015;11(10): 610–625.
34. Thapa BR, Walia A. Liver Function Test and Their Interpretation. *Indian Journal of Pediatrics.* 2007;74(7): 663-671.
35. Lameire N, Van-Biesen W, Vanholder R. Acute renal failure. *The Lancet.* 2005;365: 417–430.
36. Leh S, Hultstrom M, Rosenberger C, Iversen MB. Afferent arteriopathy and glomerula collapse but not segmental sclerosis induce tubular atrophy in old spontaneously hypertensive rats. *Virchows Arch.* 2011;459(1): 99- 108.
37. Torres VE, Grathan JJ. Cysts disease of the kidney. In: Brenner BM, ed. *Brenner and Rector's the kidney*, 8th ed. Philadelphia: Saunders Elsevier. 2008;(2):1451-1453.
38. Wright MPJ, Persad RA, Cranston DW. Renal Artery Occlusion. *BJU International.* 2001;87:9-12.
39. Shubin V A, Demidyuk VI, Komissarov AA, Rafieva ML, Kostrov VS. Cytoplasmic vacuolization in cell death and survival. *Oncotarget.* 2016;7(34): 55863-55889.
40. Ishibashi H, Nakamura M, Komori A, Migita K, Shimoda S, Liver architecture, cell function, and disease. *Seminars in Immunopathology.* 2009;31(3):399-409.

© 2021 Woko et al.; This is an Open Access article distributed under the terms of the Creative Commons Attribution License (<http://creativecommons.org/licenses/by/4.0>), which permits unrestricted use, distribution, and reproduction in any medium, provided the original work is properly cited.

Peer-review history:
The peer review history for this paper can be accessed here:
<https://www.sdiarticle4.com/review-history/74143>