



## **Mango (*Mangifera indica* L) Seed Kernel: Proximate Properties and Effect on Normal and Monosodium Glutamate-Hepato-Compromised Wistar Rats**

**Anthony Cemaluk C. Egbuonu<sup>1\*</sup>, Okechukwu C. Atasi<sup>2</sup>, Christian C. Ezeala<sup>1</sup> and Gift E. Ejike<sup>1</sup>**

<sup>1</sup>Department of Biochemistry, Michael Okpara University of Agriculture, Umudike, Nigeria.

<sup>2</sup>Department of Biochemistry, Abia State University, Uturu, Nigeria.

### **Authors' contributions**

*This work was carried out in collaboration between all authors. Author ACCE designed the study, wrote the protocol and approved the first draft of the manuscript. Author CCE carried out the experiments under supervision and wrote the first draft of the manuscript. Authors GEE and OCA managed the analyses of the study. All authors read and approved the final manuscript.*

### **Article Information**

DOI: 10.9734/IJBCRR/2017/38639

#### Editor(s):

(1) Muhammad Farhan Jahangir Chughtai, Assistant Professor NUR International University, Lahore, Pakistan.

#### Reviewers:

(1) Maha Zaki Rizk, Egypt.

(2) Luk Bahadur Chetry, Rajiv Gandhi University, India.

Complete Peer review History: <http://www.sciencedomain.org/review-history/23178>

**Original Research Article**

**Received 4<sup>th</sup> November 2017**  
**Accepted 8<sup>th</sup> January 2018**  
**Published 14<sup>th</sup> February 2018**

### **ABSTRACT**

Monosodium glutamate, MSG, a widely used flavour enhancer could induce hepatic injury in humans while mango (*Mangifera indica* L) seed kernel, MSK, a common fruit waste could be nutritive and therapeutic. Thus, this study investigated the proximate properties of MSK and the effect of MSK on normal and monosodium glutamate-hepato-compromised Wistar rats using standard protocols involving five groups (n=4) viz: control (distilled water, 2 ml/kg), MSG (8 g/kg), MSK ethanolic extract, MSKE (0.3 g/kg), MSG (8g/kg) + MSKE (0.2 g/kg) and MSG (8 g/kg) + MSKE (0.4 g/kg) respectively fed *via* gavage daily for 14 days. Proximate content of MSK revealed total carbohydrate (71.99%), moisture (10.53%), crude protein (5.68%), ash (4.31%), fat (4.29%), and crude fiber (3.20%). The determined serum bio-indicators of hepatic function (alanine aminotransferase, aspartate aminotransferase and alkaline phosphatase activity and total bilirubin concentration) in the rats exposed to MSG alone which were significantly (p<0.05) higher than those

\*Corresponding author: E-mail: [tonycemalukegbuonu@yahoo.com](mailto:tonycemalukegbuonu@yahoo.com), [egbuonu.anthony@mouaau.edu.ng](mailto:egbuonu.anthony@mouaau.edu.ng);

in the control were reduced ( $p < 0.05$ ) dose dependently following concomitant exposure of the rats to MSG and increasing concentration of MSKE. Multifocal necrosis with periportal infiltration of mononuclear inflammatory leucocytes in the liver histology of MSG-treated rats contrasted the normal hepatic histo-architecture in the control and MSKE-treated rats. The study highlighted the dietary potential of MSK and confirmed a definite MSG-induced adverse effect on the liver histology and serum functional indices of rats, probably ameliorated on concomitant exposure with MSKE. Further studies to exploit MSK in diets and drugs could reduce its waste status hence were warranted.

**Keywords:** Total bilirubin; alanine aminotransferase, alkaline phosphatase, aspartate aminotransferase.

## 1. INTRODUCTION

Monosodium glutamate (MSG) improves food flavour but with adverse effects including on the liver of animals [1-5]. The liver plays a major role in protein and amino acids metabolism among other metabolic, synthetic and regulatory processes [6]. Plant wastes could contribute to environmental pollution [7]. However, potentials exist to utilize plant wastes for new food sources and drugs development thereby reducing the possible adverse environmental impact [8-10].

Mango by-products, peels and seeds, contain high levels of various health-enhancing substances and exhibited cytoprotective effect on liver injury [11,12]. In particular, *Mangifera indica* L. seed kernel which, currently, is not utilized for commercial purposes but discarded as waste showed promising biochemical effects in recent studies [13-15]. These warranted the present study aimed at determining the proximate property of *Mangifera indica* L. seed kernel and the effect of the ethanolic extract on normal and monosodium glutamate-hepato-compromised Wistar rats. The liver is a major organ central to xenobiotic detoxification hence unique in detecting possible adverse effects of novel diets and drugs.

## 2. MATERIALS AND METHODS

### 2.1 Sample Procurement and Identification

A commercially available brand of MSG (99% purity) was used in this study. It was procured from *Ubani* market, a daily food condiments market in Umuahia, south east Nigeria. Chemicals and solvents used in this study were products of reputable companies. They were purchased from reputable chemical dealers and used without further purification. This study was conducted between June and August, 2016. Fresh mango fruits collected from a particular

mango tree were purchased from *Orie ugba*, a fruit and foodstuff market in Umuahia, Abia state, Nigeria. The mango fruits were identified and authenticated as *Mangifera indica* L (German variety) by a taxonomist in the department of Plant Science and Biotechnology, Michael Okpara University of Agriculture Umudike, Nigeria.

### 2.2 Sample Preparation and Extraction

The mango fruits were thoroughly washed with tap water. The fleshy part of the fruits was removed to obtain the seed stones which were sun-dried for three days. The sun-dried seed stones were carefully cut with clean table knife to remove the stony seed coat and obtain the seed kernels. The kernels thus obtained were chopped with home choice knife into bits and sun-dried for one week (seven days). The dry mango seed kernels were pulverized using Arthur Thomas Laboratory Mill, Crypto Model, USA. The pulverized mango seed kernel was extracted with ethanol (98 %) as described earlier [16].

### 2.3 Animal Study

#### 2.3.1 Animal procurement and exposure groups

Twenty adult male Wistar rats (weight range, 104-170 g) used in this study were procured from the animal house of the Faculty of Biological Sciences, University of Nigeria, Nsukka. The rats were acclimatized for 2 weeks and then randomized (based on weight) to five experimentation groups with sample size of four rats. Rats in the control group were sham-dosed with distilled water (without either the extract or MSG) while rats in the MSG group were fed intoxicating dose (8000 mg/kg body weight) of MSG according to Mariyamma et al. [17] and as in several recent studies [13-15,18-20]. Rats in the extract group were fed mango seed kernel extract at 300 mg/kg body weight while rats in

the MSG + low extract group were concomitantly fed the mango seed kernel extract (200 mg/kg body weight) and intoxicating dose of MSG (8000 mg/kg body weight) whereas rats in the MSG + high extract group were co-administered 400 mg/kg body weight of the mango seed kernel extract and intoxicating dose of MSG (8000 mg/kg body weight). The exposure was *per oral* and daily for 14 days.

### **2.3.2 Sacrifice, blood sample collection and preparation**

After 2 weeks (14 days) exposure, the rats were sacrificed the next day after overnight fast by cardiac puncture technique and the blood sample of the respective rats was collected individually into clean polystyrene tubes. The respective blood sample thus collected was centrifuged at 3000 rpm for 10 minutes. The resultant serum was respectively collected into polystyrene tubes and stored in deep freezer for the determination of serum alanine aminotransferase (ALT), aspartate aminotransferase (AST) and alkaline phosphatase (ALP) activity as well as serum total bilirubin (TBIL) concentration.

### **2.3.3 Ethical consideration**

This study which is a continuation of our line of studies on the evaluation of biochemical effects of mango seed kernel extract on normal and monosodium glutamate-challenged experimental models considered and adhered to the standard ethical use of experimental animals. Throughout out the experimentation (acclimatization and exposure periods), all rats were housed at 25°C in stainless steel cages under normal daylight/dark cycle and humid tropical condition. The rats were allowed free access to rats' feed (Vital feed, Jos Nigeria) and tap water, and generally received humane care in accordance with the guidelines of the National institute of Health, USA for ethical treatment of laboratory animals as approved (by consensus consent after the presentation of the study proposal) by the various (departmental and college) ethical committees of Michael Okpara University of Agriculture Umudike, Nigeria.

### **2.4 Determination of Proximate Content**

Proximate content viz: moisture, ash, fibre, fat and protein was determined as described previously [21-23]. The total carbohydrate content of MSK was estimated as the Nitrogen free extract (NFE) by arithmetic difference using the relation: Total CHO % = 100 - (fibre + protein + Moisture + ash + fats).

### **2.5 Determination of Seric Chemistry Parameters**

Determination of serum bilirubin was according to instruction provided in Randox™ assay kit based on the method of Jendrassik and Grof [24]. The method was based on the principle that bilirubin could react with diazotized sulphanilic acid in an alkaline medium to form a blue coloured complex which could be measured with a spectrophotometer and calculated to give the concentration of bilirubin in the serum sample.

The serum activity for AST and ALT was determined using a Randox™ commercial kits according to the method of Reitman and Frankel [25]. The method was based on the colorimetric estimation of oxaloacetate (for AST) or pyruvate (for ALT) produced through transamination of aspartate or alanine respectively on reacting with 2-4-dinitrophenyl hydrazine (DNPH). The intensity of the resultant brown-colored hydrazone was measured with a colorimeter after 5 minutes at 540 nm and the activity (AST or ALT) was read up from standard curve.

The serum ALP activity was determined using a Randox™ commercial assay kit according to the method of King and Armstrong [26]. This was based on the colorimetric estimation, at 520 nm, of red colored complex formed following the hydrolysis of phenyl phosphate by alkaline phosphatase to release hydroxybenzene (aside phenol and phosphate) which combines with 4-aminophenazone to form a red complex in a reaction catalyzed by potassium ferricyanide (K<sub>2</sub>Fe(CN)<sub>2</sub>). The alkaline phosphatase activity (IU/L) was calculated from the relation:

$$\text{ALP (IU/L)} = \frac{\text{Abs of sample}}{\text{Abs of standard}} \times \text{conc of standard}$$

### **2.6 Histopathological Examination**

Collected sample (liver) was fixed in 10% phosphate buffered formalin for a minimum of 48 hours. The tissue was subsequently trimmed, dehydrated in 4 grades of alcohol (70%, 80%, 90% and absolute alcohol), cleared in 3 grades of xylene and embedded in molten wax. On solidifying, the blocks were sectioned, 5µm thick, with a rotary microtome, floated in water bath and incubated at 60°C for 30 minutes. The 5µm thick sectioned tissues were subsequently cleared in 3 grades of xylene and rehydrated in 3 grades of alcohol (90%, 80% and 70%). The sections were stained with Hematoxylin for 15

minutes. Blueing was achieved with ammonium chloride. Differentiation was done with 1% acid alcohol before counterstaining with Eosin. Permanent mounts were made on degreased glass slides using a mountant; DPX. Prepared slides were examined with a Motic™ compound light microscope using x4, x10 and x40 objective lenses. Photomicrographs were taken using a Motic™ 9.0 megapixels microscope camera at x100 and x400 magnifications.

## 2.7 Method of Statistical Analysis

Analysis of variance (ANOVA) and least significance difference (LSD) were carried out on the data at 95% confidence level using SPSS statistical software package, version 20. Results were expressed as mean  $\pm$  standard deviation (SD).

## 3. RESULTS AND DISCUSSION

### 3.1 Results

As shown on Table 1, the proximate content of MSK in decreasing order revealed that total carbohydrate (71.99%) was highest followed by moisture (10.53%), crude protein (5.68%), fat (4.29%) and ash (4.31%) while crude fiber (3.20%) was the least.

The determined serum alanine aminotransferase, aspartate aminotransferase and alkaline phosphatase activity (IU.l<sup>-1</sup>), respectively in the rats exposed to MSG alone (129.55, 152.50, 238.67) which was significantly ( $p < 0.05$ ) higher than that in the control (74.48, 116.68, 34.85) and Extract-exposed group (34.18, 145.75, 137.25) reduced ( $p < 0.05$ ) dose dependently following concomitant exposure of the rats to 200 mg/kg (39.50, 151.00, 173.25) and 400 mg/kg (36.62, 149.71, 169.67) of MSKE (Table 2).

**Table 2. Effect of pulverized mango (*M. indica*) seed kernel extract, MSKE, on the activity (IU/L) of alanine aminotransferase, ALT, aspartate aminotransferase, AST, and alkaline phosphatase, ALP, and concentration of total bilirubin of normal and monosodium glutamate-challenged rats' serum**

| Groups  | ALT (IU/L)        | AST (IU/L)        | ALP (IU/L)        | TBIL (mg/dl)    |
|---|-------------------|-------------------|-------------------|-----------------|
| Control (Distilled water 2 ml/kg b.w)               | 74.48 $\pm$ 5.13  | 116.68 $\pm$ 1.31 | 34.85 $\pm$ 0.92  | 0.33 $\pm$ 0.03 |
| MSG 8000 (mg/kg b.w)                                | 129.55 $\pm$ 9.83 | 152.50 $\pm$ 0.87 | 238.67 $\pm$ 1.31 | 1.76 $\pm$ 0.03 |
| Extract 300 (mg/kg b.w)                             | 34.18 $\pm$ 0.68  | 145.75 $\pm$ 0.77 | 137.25 $\pm$ 1.30 | 0.85 $\pm$ 0.05 |
| MSG 8000 (mg/kg b.w) + low Extract 200 (mg/kg b.w)  | 39.50 $\pm$ 1.05  | 151.00 $\pm$ 1.01 | 173.25 $\pm$ 0.86 | 1.24 $\pm$ 0.01 |
| MSG 8000 (mg/kg b.w) + high Extract 400 (mg/kg b.w) | 36.62 $\pm$ 1.23  | 149.71 $\pm$ 1.09 | 169.67 $\pm$ 1.04 | 1.17 $\pm$ 0.22 |

Value presented as mean  $\pm$  SEM of sample size,  $n = 4$  rats. + denotes higher by; - denotes lower by. Significant difference at  $P = .05$

**Table 1. Proximate composition (%) of pulverized mango (*M. indica*) seed kernel, MSK**

| Proximate parameter | Composition in MSK (%) |
|---------------------|------------------------|
| Total carbohydrate  | 71.99 $\pm$ 0.06       |
| Moisture content    | 10.53 $\pm$ 0.02       |
| Crude protein       | 5.68 $\pm$ 0.02        |
| Ash content         | 4.31 $\pm$ 0.01        |
| Fat                 | 4.29 $\pm$ 0.01        |
| Crude fibre         | 3.20 $\pm$ 0.01        |

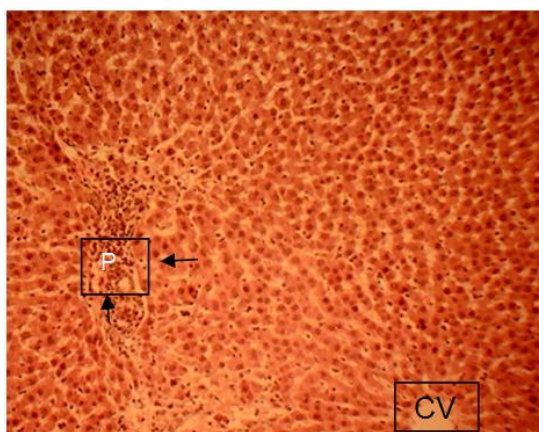
Value presented as mean  $\pm$  SEM of triplicate determinations

Similarly, the determined serum total albumin concentration (mg.dl<sup>-1</sup>) in the rats exposed to MSG alone (1.76) which was significantly ( $p < 0.05$ ) higher than that in the control (0.33) and Extract-exposed group (0.85) reduced ( $p < 0.05$ ) dose dependently following concomitant exposure of the rats to 200 mg/kg (1.24) and 400 mg/kg (1.17) of MSKE (Table 2).

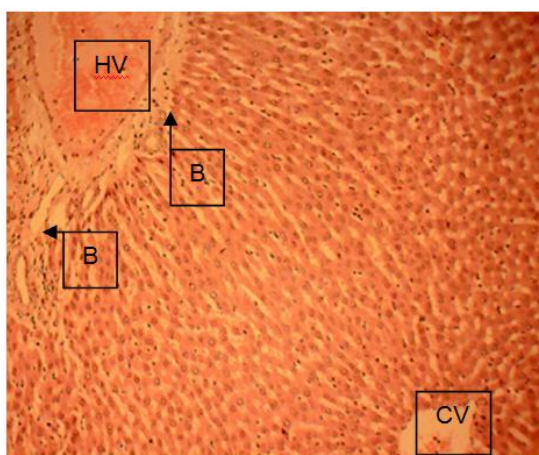
### 3.1.1 Histopathological observations

Sections from the MSG group showed a mild periportal infiltration of mononuclear inflammatory leucocytes (arrow) and multifocal areas of hepato-cellular necrosis with mononuclear leucocytic infiltration (Fig. 1).

Sections of the liver collected from the animals in the other groups including the control as compared to the MSG-exposed group showed normal hepatic histo-architecture viz: normal hepatic lobules with normal hepatocytes arranged in radiating cords around the central veins (CV) with the hepatocytes (arranged in cords) radiating towards the portal areas characteristic of normal hepatic artery, hepatic vein (HV) and bile duct (B) (Figs. 2, 3, 4, 5).



**Fig. 1. Photomicrograph of liver sections of rats exposed to MSG showing damaged Portal area (P) as mild periportal infiltration of mononuclear inflammatory leucocytes (arrow) and multifocal areas of hepatocellular necrosis with mononuclear leucocytic infiltration. H&E: ×100**

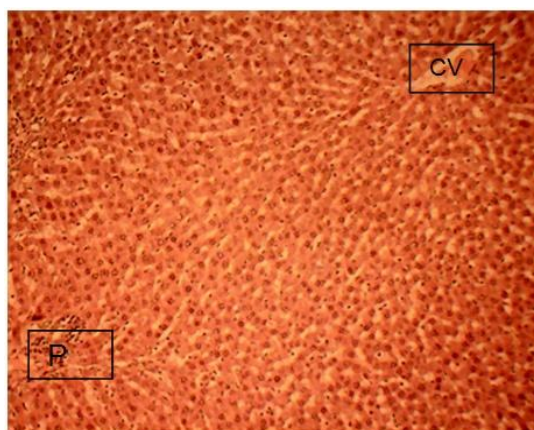


**Fig. 2. Photomicrograph of liver sections of rats exposed to MSKE alone showing normal central veins (CV) with normal hepatocytes arranged in radiating cords towards the portal areas characteristic of normal hepatic artery, hepatic vein (HV) and bile duct (B). H&E: ×100**

### 3.2 Discussion

Monosodium glutamate, MSG, a widely used flavour enhancer could induce hepatic injury in humans while mango (*Mangifera indica L*) seed kernel, MSK, a common fruit waste could be nutritive and therapeutic. Thus, this study investigated the proximate properties of MSK

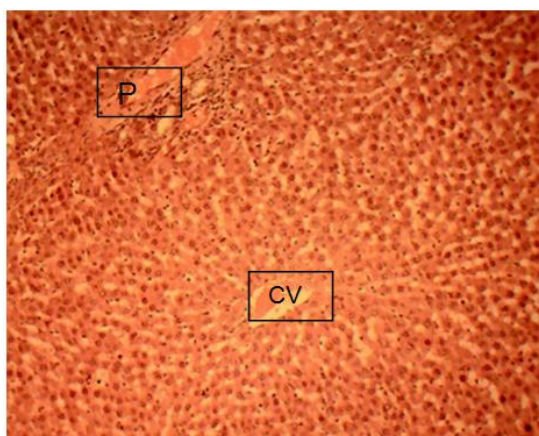
and the effect of MSK on normal and monosodium glutamate-hepato-compromised Proximate content of MSK were: total carbohydrate (71.99%), moisture (10.53%), crude protein (5.68%), ash (4.31%), fat (4.29%), and crude fiber (3.20%) which suggest that MSK could have dietary potential. In particular, the total carbohydrate content of MSK compared with the value range (70.12% - 77.90%) obtained in previous studies [27-28] and far higher than that (30.85%) in *Terminalia catappa* endocarp [29]. This indicated that mango seed could serve as a good alternative carbohydrate-energy source. The crude fibre content compared with that (5.72%) reported by Nzewi and Egbuonu [30] and higher than that (2.40 and 2.02, respectively) reported by Fowomola [27] and Nzikou et al. [31] but far lower than that (36.33%) reported for *Terminalia catappa* endocarp [29] indicating that MSK could not offer high satiety (appetite satisfaction) or enhanced peristaltic movement of food through the alimental canal that could prevent constipation [32]. The moisture content of mango seed kernel obtained from this work was slightly higher when compared to the value range (5.00% - 9.8%) reported in previous studies [29-34] though lower than that reported by Nzikou et al. [31]. The observed moisture content was considered moderately high to ensure ease of transportation of nutrients and other necessary metabolic reactions and low to ensure long shelf life for the mango seed kernel flour [34].



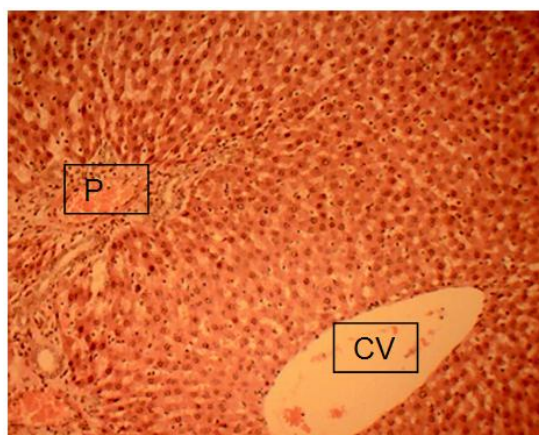
**Fig. 3. Photomicrograph of liver sections of rats in the control group showing normal Central vein (CV); Portal area (P). H&E: ×100**

The ash percentage obtained (4.31%) was slightly higher than that (3.07%) reported by Egbuonu [9] for *Citrullus lanatus* rind and seed

but lower than that (9.05%) reported by Abulude et al. [32] and that (11.03%) reported by Anuforo et al. [29] implying moderate mineral supplying potential of MSK. The protein content of this study (5.68%) was within the range (5.20-8.28%) obtained from many varieties of mango in previous studies [34,35] and *Terminalia catappa* endocarp [29] suggesting that MSK could be a good dietary protein source. Also, MSK may be a good source of fat and oil as the fat and oil content obtained in this study (4.29%) was in the upper limit of the range (1.94% - 5.68%) obtained in previous studies [27,32,34,36] though lower compared to that (8.53) in *Terminalia catappa* endocarp [29].



**Fig. 4. Photomicrograph of liver sections of rats exposed to MSG + Low MSKE showing normal Central vein (CV) and Portal area (P). H&E: ×100**



**Fig. 5. Photomicrograph of liver sections of rats exposed to MSG + high MSKE showing normal Central vein (CV); Portal area (P). H&E: ×100**

The determined serum bio-indicators of hepatic function (alanine aminotransferase, aspartate aminotransferase and alkaline phosphatase activity and total bilirubin concentration) in the rats exposed to MSG alone which were significantly ( $p < 0.05$ ) higher than those in the control were reduced ( $p < 0.05$ ) dose dependently following concomitant exposure of the rats to MSG and increasing concentration of MSKE. Bilirubin is the catabolic product of haem metabolism via the activities of the liver enzyme UDP-glucuronyltransferase [37] hence an indicator of liver function and integrity. Increased activity of ALP aside indicating liver damage could be indicating bone diseases [37,5]. Thus, the results indicated MSG-related hepatotoxicity and possibly bone dysfunctions in the rats which perhaps were significantly and dose-dependently ameliorated by MSKE. Toxic assault on the liver associated with an increase in the studied indicators of liver function [38,39] and MSG-induced hepatic damage was reported earlier [5]. Multifocal necrosis with periportal infiltration of mononuclear inflammatory leucocytes in the liver histology of MSG-treated rats contrasted the normal hepatic histo-architecture in the control and MSKE-exposed groups. This seemingly confirmed the seric chemistry results that further suggested MSKE-related amelioration of MSG-induced hepatic assault and damage.

#### 4. CONCLUSION

The study highlighted the dietary potential of MSK and confirmed a definite MSG-induced adverse effect on the liver histology and serum functional indices of rats, probably ameliorated on concomitant exposure with MSKE. Further studies to exploit MSK in diets and drugs could reduce its waste status hence were warranted.

#### ETHICAL APPROVAL

All authors hereby declare that "Principles of laboratory animal care" (NIH publication No. 85-23, revised 1985) were followed, as well as specific national laws where applicable. All experiments have been examined and approved by the appropriate ethics committee.

#### COMPETING INTERESTS

Authors have declared that no competing interests exist.

## REFERENCES

- Husarova, V, Ostatnikova, D. Monosodium glutamate toxic effect and their implication for human intake: A review. *Journal of Medical Research*. 2013;2013:1-12. DOI:10.5171/2013.608765.
- Egbuonu, ACC, Ezeanyika, LUS, Ejikeme, PM, Obidoa, O. Histomorphologic alterations in the liver of male Wistar rats treated with L-arginine glutamate and monosodium glutamate. *Research Journal of Environmental Toxicology*. 2010;4(4): 205-213. DOI:10.3923/rjet.2010.205.213.
- Manal ST, Nawal A. Adverse effects of monosodium glutamate on liver and kidney function in adult rats and potential protective effect of vitamins C and E. *Food and Nutrition Science*. 2012;3:651-659.
- Eweka AO. Histological studies of the effects of monosodium glutamate on the kidney of adult Wistar rats. *The Internet Journal of Health*. 2007;6(2):1-6.
- Egbuonu ACC, Obidoa O, Ezeokonkwo CA, Ezaeanyika LUS, Ejikeme PM. Hepatotoxic effects of low dose oral administration of monosodium glutamate in male albino rats. *African Journal of Biotechnology*. 2009;8(13):3031-3035. DOI:10.5897/AJB09.209.
- Elaine NM, Katja M. Human anatomy and physiology. 9<sup>th</sup> edition. New Mastering A and P with Pearson E Text. Benjamin-Cummings Publication Company. 2012;939. ISBN 978032185120.
- Maisuthisakul P, Pasuk S, Ritthiruangdej P. Antioxidant properties of phenolic phytochemical from various cultivars of Thai mango seed kernel. *Asian Journal of Food and Agro-Industry*. 2008;1:87-88.
- Maryam F, Mohammed EB. Evaluation of physiology properties of Iranian mango seed kernel oil. 2<sup>nd</sup> International Conference on Nutrition and Food Science IPCBEE. 2013;53.
- Egbuonu ACC. Assessment of some antinutrient properties of watermelon (*Citrullus lanatus*) rind and seed. *Research Journal of Environmental Sciences*. 2015a;9(5):225-232. DOI:10.3923/rjes.2015.
- Egbuonu, ACC. Comparative investigation of the antibacterial and antifungal potentials of the extracts of watermelon (*Citrullus lanatus*) rind and seed. *European Journal of Medicinal Plants*. 2015b;9(4):1-7. DOI:10.9734/EJMP/2015.
- Lima L, Tania A, Carlos L, Policarpo A, Alvaro J, Susana J, Patricia S, Lucia P, Maria A. *In vitro* cytotoxic, antifungal, trypanocidal and leishmanicidal activities of acetogenins isolated from *Annona cornifolia* A.St.Hil. (Annonaceae). *Annals of Brazilian Academy of Sciences*. 2014;86(2):829-839.
- Yao P, Nussler A, Liu LG, Hao LP, Song FF, et al. Quercetin protects human hepatocytes from ethanol derived oxidative stress by inducing heme oxygenase-1 via the MAPK/Nrf2 pathways. *Journal of Hepatology*. 2007;47:253-261.
- Egbuonu ACC, Ejike GE. Effect of pulverized *Mangifera indica* (mango) seed kernel on monosodium glutamate-intoxicated rats' serum antioxidant capacity, brain function and histology. *EC Pharmacology and Toxicology*. 2017;4(6):228-243.
- Egbuonu ACC, Ekwuribe GA. Pulverized *Mangifera indica* (mango) seed-kernel modulated serum lipid profile in monosodium glutamate-challenged rats. *Journal of Applied Biotechnology*. 2017;5(2):72-87.
- Egbuonu ACC, Oriji SO. Pulverized *Mangifera indica* (mango) seed kernel mitigated monosodium glutamate-intoxicated rats' kidney histology and bio-functions. *Journal of Nutritional Health and Food Science*. 2017;5(2):1-7.
- Egbuonu ACC. Comparative investigation of the proximate and functional properties of watermelon (*Citrullus lanatus*) rind and seed. *Research Journal of Environmental Toxicology*. 2015c;9(3):160-167. DOI:10.3923/rjet.2015.
- Mariyamma T, Sujatha KS, Sisilamma G. Protective effect of *Piper longum* Linn. on monosodium glutamate induced oxidative stress in rats. *Indian Journal of Experimental Biology*. 2009;47:86-192.
- Egbuonu ACC, Opara CI, Akachukwu D, Onyedikachi UB. Effect of ethanolic extract of avocado pear (*Persea americana*) seed on normal and monosodium glutamate-compromised rats' hepatic histomorphology and serum bio-functional parameters. *Research Journal of Environmental Sciences*. 2018;12(2):53-62.

19. Mbah UO, Egbonu ACC. Ameliorative potentials of egg plant (*Solanum melongena* Linn) fruit ethanolic extract on monosodium glutamate-intoxicated rats' lipid profile, haematology and heart histology. International Journal of Biochemistry Research and Review. 2017a;18(3):1-10.
20. Mbah UO, Egbonu ACC. Ethanolic extract of *Solanum melongena* Linn fruit mitigated monosodium glutamate-induced oxidative stress. International Journal of Biochemistry Research & Review. 2017b;18(2):1-8:
21. Egbonu ACC, Ogele OM, Amaraihu KL. Comparative evaluation of the proximate composition and antibacterial activity of ground *Musa paradisiaca* (plantain) peels and leaves. British Biotechnology Journal. 2016a;15(2):1-9.  
DOI: 10.9734/BBJ/2016/27151.)
22. Egbonu ACC, Harry EM, Orji IA. Comparative proximate and antibacterial properties of milled *Carica papaya* (pawpaw) peels and seeds. British Journal of Pharmaceutical Research. 2016b;12(1):1-8.  
DOI: 10.9734/BJPR/2016/26808.)
23. Egbonu ACC, Osuji CA. Proximate compositions and antibacterial activity of *Citrus sinensis* (sweet orange) peel and seed extracts. European Journal of Medicinal Plants. 2016;12(3):1-7.  
DOI:10.9734/EJMP/2016/24122.)
24. Jendrassik L, Grof P. Biochemistry of Elements. In Jendrassik Is Berlina grandiflora (Leguminosae) toxic in rats? 1938;297:81-82.
25. Reitman S, Frankel S. A colorimetric method for the determination of serum glutamic oxalacetic and glutamic pyruvic transaminases. American Journal of Clinical Pathology. 1957;28:56-63.
26. King EJ, Armstrong AR. A convenient method for determining serum and bile phosphatase activity. Canadian Medical Association Journal. 1934;31:376-381.
27. Fowomola MA. Some nutrient and anti-nutrients contents of mango (*Mangifera indica*) seed. African Journal of Food Sciences. 2010;4(8):472-476.
28. Egbonu ACC, Nzewi DC, Egbonu ONC. Effect of soaking prior to oven-drying on some nutrient and anti-nutrient properties of bitter yam (*Dioscorea dumetorum*). Journal of Nutrition and Food Science. 2014;4(280):1-4.  
DOI:10.4172/2155-9600.1000280.
29. Anuforo PC, Achi NK, Egbonu ACC, Egu EU. Proximate analysis and determination of some selected vitamins and minerals contents of *Terminalia catappa* endocarp flour. Journal of Nutritional Health and Food Sciences. 2017;5(5):1-4.
30. Nzewi D, Egbonu ACC. Effect of boiling and roasting on the proximate properties of asparagus bean (*Vigna sesquipedalis*). African Journal of Biotechnology. 2011;10(54):11239-11244.  
DOI: 10.5897/AJB11.452.
31. Nzikou JM, Kimbonguila A, Matos L, Loumouamou B, Pambou-Tobi NPG, Ndangui CB, Abena AA, Silou TH, Scher J, Desobry S. Extraction and characteristics of seed kernel oil from mango (*Mangifera indica*). Research Journal of Environmental and Earth Sciences. 2010;2(1):31-35.
32. Abulude FO, Eluyode WO, Adesanya OAE, Koumah, TA. Proximate and selected mineral composition of *Mangifera indica* L. and *Persea Americana* seed found in Nigeria. Agricultural Journal. 2006;1(2):72-76.
33. Egbonu ACC, Nzewi DC. Influence of blanching on some nutrient and anti-nutrient compositions of bitter yam (*Dioscorea dumetorum*). British Journal of Applied Science and Technology. 2016;6(2):1-8.  
DOI:10.9734/BJAST/2016/25650.
34. Akinyemi SOS, Akin-Idowu PE, Oduntan OO, Egbekunle KO. Chemical composition of the seed kernel flour of some mango (*Mangifera indica* L.) varieties. Journal of Biological and Chemical Research. 2015;32(1):160-173.
35. Kayode RMO, Sani A, Apata DF, Joseph JK, Olorunsanya OA, Annongu AA, Obalowu MA. Physicochemical and antinutritional characterization of the kernels of some mango (*Mangifera indica*) cultivars grown in western parts of Nigeria. Food Science and Quality Management. 2013;22:1-8.
36. Egbonu ACC, Nzewi DC. Evaluation of some nutritional and sensory characteristics of bread-fruit (*Teculia africana*) cooked with various food-waste ash infusions. Research Journal of Medicinal Plant. 2014;8(6):277-282.  
DOI:10.3923/rjmp.2014.



37. Mauro P, Renze B, Wouter W. In: Tietz test book of clinical chemistry and molecular diagnostics. 4<sup>th</sup> edition. Carl, A.B. Edward, R. David, E. B., editors. Elsevier. 2006;Enzyme:604-626.
38. Emelike CU, Dapper DV. Biochemical effects of oral administration of aqueous extract of *Hibiscus sabdariffa* on Wistar albino rats. IOSR Journal of Dental and Medical Sciences. 2013;9(1):35-39
39. Izunya AM, Nwaopara AO, Aigbiremolen A, Odiike MAC, Oaikhenana GA, Bankole JK, Ogarah PA. Morphological and biochemical effect of crude Aqueous extract of *manginifera indica L.* (Mango) stem bark on the liver of Wistar rat. Research Journal of Applied Science, Engineering and Technology. 2010;2(5):460-465.

---

© 2017 Egbuonu et al.; This is an Open Access article distributed under the terms of the Creative Commons Attribution License (<http://creativecommons.org/licenses/by/4.0>), which permits unrestricted use, distribution, and reproduction in any medium, provided the original work is properly cited.

*Peer-review history:*  
*The peer review history for this paper can be accessed here:*  
<http://www.sciencedomain.org/review-history/23178>