



# Malignant Melanoma of the Anorectal Region: A Case Study and Review of the Contemporary Treatment Options

Rakshita Ramesh Bhat <sup>a\*</sup> and Namitha Prakash <sup>a</sup>

<sup>a</sup> Department of Medical Oncology, Mangalore Institute of Oncology, Pumpwell, Mangalore, India.

## Authors' contributions

*This work was carried out in collaboration between both authors. Authors RRB and NP wrote the original draft and edited and revised the manuscript. Author RRB obtained the images. Both authors read and approved the final manuscript.*

## Article Information

DOI: 10.9734/JCTI/2023/v13i1225

## Open Peer Review History:

This journal follows the Advanced Open Peer Review policy. Identity of the Reviewers, Editor(s) and additional Reviewers, peer review comments, different versions of the manuscript, comments of the editors, etc are available here: <https://www.sdiarticle5.com/review-history/95913>

Case Study

Received: 25/11/2022

Accepted: 29/01/2023

Published: 30/01/2023

## ABSTRACT

**Aims:** Anorectal melanoma, an uncommon malignancy of mucosal origin accounts for 0.05 per cent of all colorectal malignancies and 1 per cent of tumours of the anal canal. The typical clinical presentation includes local pain, palpable mass, bleeding, change in bowel habits, and weight loss. The symptoms are somewhat nondescript and unremarkable and can be easily confused with other conditions native to the region. Hence, a careful and timely assessment is imperative in treating this condition.

**Presentation of Case:** A case involving a 54-year-old male who presented with a 3-month history of rectal bleeding and pain. Further assessment revealed a malignant melanoma of the anal canal. After undergoing laparoscopic abdominoperineal resection, the patient was on 6 cycles of dacarbazine. He was subsequently found to have liver metastasis. He subsequently started oral Temozolomide for 2 cycles. He has been on close follow-up for the last 6 months and the disease has not progressed since.

**Discussion:** The course of evaluation in suspected cases of anorectal melanoma is a rectal examination, biopsy and histopathologic examination. Immunohistochemistry aids in the

\*Corresponding author: Email: rakshitarbhat74@gmail.com;

confirmation of the diagnosis. Laparoscopic abdominoperineal resection demonstrates good response rates. Adjuvant chemotherapy in anorectal melanoma can be given in patients following surgical resection of the primary anorectal tumour and with a high risk of recurrence. Targeted therapies like c-kit inhibitors, BRAF inhibitors, anti-CTLA-4 antibodies and anti-PD-1 antibodies can also be used.

**Conclusion:** Melanomas of the anorectal region present a diagnostic dilemma and carry poor prognoses. Despite an aggressive management approach, the disease maintains an average five-year survival rate of 20%.

*Keywords: Mucosal melanoma; bleeding per rectum; dacarbazine.*

## ABBREVIATIONS, ACRONYMS

*HMB-45* : Human Melanoma Black 45  
*CTLA-4* : cytotoxic T-lymphocyte-associated antigen 4  
*PD-1* : programmed cell death 1  
*APR* : abdominoperineal resection

## 1. INTRODUCTION

Anorectal mucosal melanomas are rare and account for approximately 0.05 per cent of all colorectal malignancies and 1 per cent of all anal canal cancers [1]. The primary site of origin is the rectum or anal canal but remains undetermined in most cases [2]. Although uncommon, it is highly malignant and an especially aggressive disease with a poor prognosis. Patients can present with a range of symptoms like palpable mass, bleeding, pain in the anorectal region, change in bowel habits, and loss of weight. The condition is easily confused with haemorrhoids, adenocarcinoma, polyps etc. Since these symptoms are also common in other tumours of the anorectal region, a careful evaluation is necessary to promptly arrive at the diagnosis. The rarity and resemblance of the clinical presentation can lead to misdiagnosis and delay in management. It is also occasionally an incidental finding when a specimen of hemorrhoidectomy or resected anal polyp is observed.

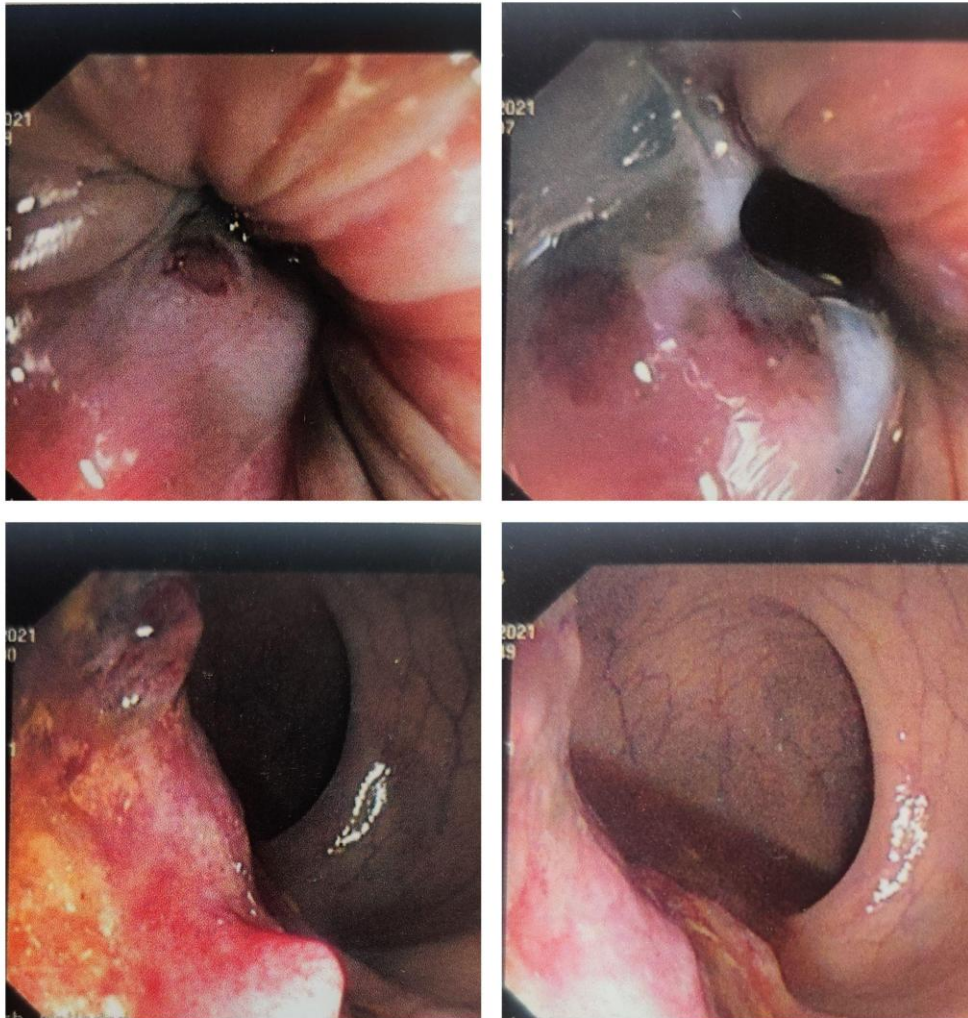
A majority of the cases occur at the mucocutaneous junction, and the rest of them occur in the skin of the anal verge, the transitional epithelium of the anal canal, or the rectal mucosa. The site of origin does not have prognostic relevance [3]. Most cases present with lesions with a thickness of >2 mm, regional lymph node involvement which is observed in more than 60% of the cases [2], and distant metastases which are observed in more than 30% of the cases [4].

The course of evaluation to arrive at a diagnosis is a rectal examination, biopsy and histopathologic examination, ultrasound of the abdomen and pelvis, and CT scan or PET-CT to confirm the diagnosis and evaluate distant metastasis.

The mainstay of management of anorectal melanoma is surgical resection. A wide local, sphincter-sparing excision or abdominoperineal resection is performed depending on the site, size, and extent of the tumour [5]. Inguinal lymphadenectomy is performed in patients with clinically apparent nodal disease. Along with surgical resection, the other modalities of management are adjuvant radiation therapy, chemotherapy, and immunotherapy.

## 2. PRESENTATION OF CASE

A case involving a male patient in his fifties with no significant past medical history, who presented with complaints of blood in stools and pain during defecation for 3 months. On digital rectal examination, an ulcero-proliferative growth was palpated 4 cm from the anal verge, with no active bleeding. Laboratory parameters like haemoglobin, hematocrit, total WBC count, and platelet count were within normal limits. The patient underwent a colonoscopy (Fig. 1) at a local hospital and presented with a biopsy report of a fibroepithelial polyp and tubular adenoma with mild dysplasia. Microscopy revealed an infiltrating tumour composed of sheets and nests of malignant spindle cells with pleomorphic vesicular nuclei, prominent nucleoli and cytoplasmic melanin pigment.



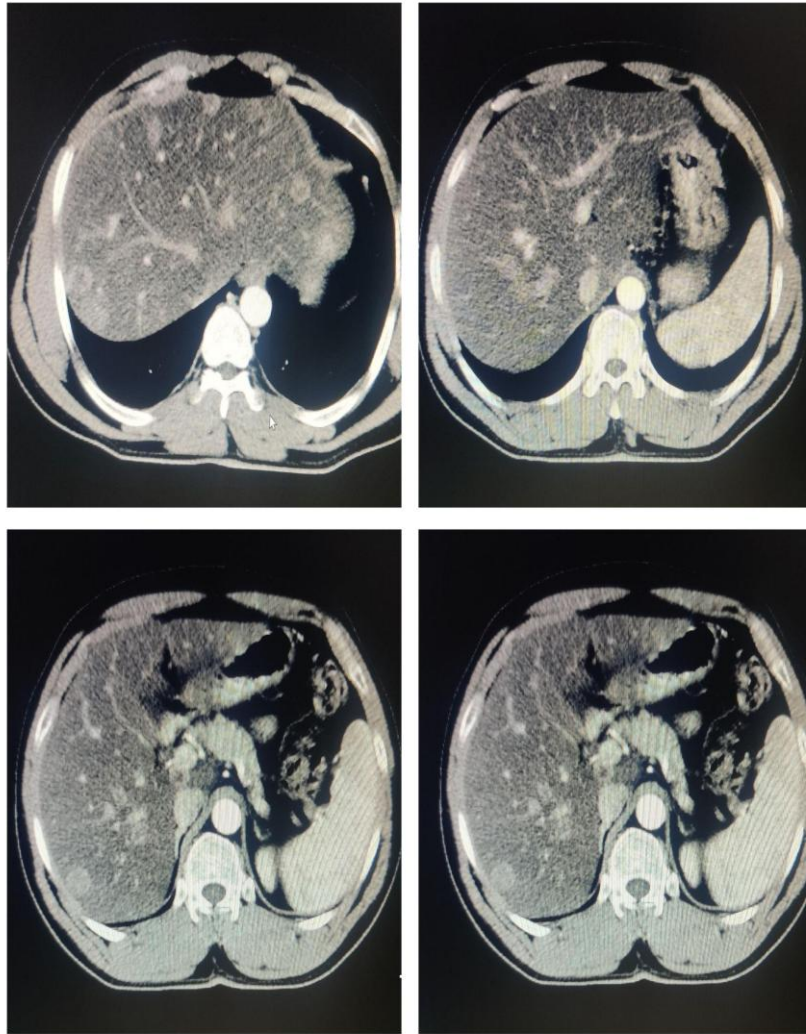**Fig. 1. Colonoscopy images showing an ulceroproliferative growth in the lower rectum with patches of pigmentation**

He underwent laparoscopic abdominoperineal resection, with intra- and peri-operative periods being uneventful. An ulceroproliferative greyish-white tumour was resected from the lower rectum measuring 8.2x3.2x2.2 cm. The tumour was present below the level of the anterior peritoneal reflection. The adjacent bowel wall was unremarkable. Negative resection margins (both proximal and distal) were achieved. Histology confirmed malignant melanoma of the rectum. The tumour invaded the subserosa. Lymphovascular and perineural invasions were identified. 9 out of the 10 lymph nodes removed, showed tumour deposits. The TNM staging was determined to be pT3N2b.

Plain and contrast CT of the thorax were performed and there was no evidence of pulmonary metastases. Ultrasonography of the

abdomen and pelvis revealed three round hypoechoic lesions in both lobes of the liver which were indeterminate for metastases. CECT of the abdomen and pelvis was later performed (Fig. 2).

The patient was administered six cycles of Dacarbazine. An ultrasound of the abdomen was taken after the completion of 5 cycles of dacarbazine which showed hypoechoic lesions in the liver indeterminate for metastasis. A CECT performed after the completion of the 6th cycle confirmed liver metastasis. The patient subsequently started oral temozolomide 100 mg once daily for 2 weeks, given for 2 cycles. He had no adverse reactions to the same. He has been on a close follow-up for 6 months and the disease has not progressed since.



**Fig. 2. Multiple (more than 15) hyper-enhancing, round lesions were seen in both lobes of the liver, the largest measuring 4x2.4 cm in segment VIII of the liver, suggestive of hepatic metastases. Metastatic abdominal, pelvic and left inguinal adenopathy was also noted in the IVC region, left common iliac and left inguinal region. The largest nodes measured 2.8x1.9 cm, 1.5x1.4 cm, and 2.1x2 cm respectively**

### 3. DISCUSSION

Melanomas are tumours arising from melanocytes, which are melanin-producing cells derived from embryonic neural crest cells. Malignant melanomas of the mucosal lining are rare and account for roughly 1.3% of melanomas [2]. The presence of melanocytes in intestinal mucosa from the stomach to the distal rectum is contentious. But, they have been found to be present within the transition zone beneath the dentate line and increase in number distally toward the anoderm [6].

Mucosal melanomas bear a worse prognosis than their cutaneous counterparts. The sites of

occurrence are the respiratory, alimentary, and genitourinary tracts. Malignant melanomas of the GI are rare and account for 1-3% of all GI malignancies [7], and arise from the anorectal region and rarely, the small intestine. The incidence increases with age with the median age of occurrence being 70 years and is more common in females than males [8].

The risk factors for anorectal mucosal melanoma are not solidly established. Even though cutaneous melanoma is associated with exposure to ultraviolet light, the anatomic location makes ultraviolet exposure an unlikely



risk factor here. There is insufficient information to substantiate the role of human papillomavirus in the tumorigenesis of anorectal melanoma, but there has been recent epidemiologic data to suggest that there is an increased risk associated with human immunodeficiency virus infection [9].

In understanding the pathogenesis of anorectal melanoma, one must never forget to examine the role of c-KIT and BRAF mutations. The subtypes of melanomas arising from different parts of the body have variable c-kit or BRAF mutation frequencies. There are very few studies in the literature that have examined c-kit and BRAF mutation status in melanomas that occur in the anus and rectum. In a study conducted by Ni S et al., wherein 40 cases of anorectal melanoma were analysed for c-KIT and BRAF mutations, 7 patients were found to have c-KIT mutations, which indicates that a subset of anorectal melanomas have activating c-kit mutations, suggesting that kinase inhibitors such as imatinib may be used to treat this subset of melanoma patients. CD117 expression was detected in 16 of the 40 cases, and 3 of these 16 cases also had c-kit mutations. BRAF mutation was detected in 2 patients [10].

ARM is an aggressive tumour with symptoms such as alteration in bowel habits, mass per rectum, rectal pain, and bleeding. Patients usually present with metastatic disease due to difficulty in the determination of the primary site, and non-specific clinical presentation.

Anorectal melanomas closely resemble benign tumours and require extensive evaluation to arrive at the diagnosis. The main diagnostic modalities are rectal examination, colonoscopy, a histological examination of the lesion, MRI, CT, and/or a PET scan. Immunohistochemistry is used to determine the presence of protein S-100, melanoma antigen HMB-45, Melan-A, and Mart-1 antibodies. This aids in the confirmation of the diagnosis.

Distant hepatic, pulmonary, and bone metastases are common findings in most patients at the time of presentation. A modification of the AJCC 8th Edition cutaneous melanoma staging system is used to stage mucosal melanomas, which classifies them into stages I, II, and III [11].

The preferred line of management is a wide local, negative margin, sphincter-sparing excision

unless otherwise indicated. Abdominoperineal resection is indicated in patients with bulky local disease and a risk of local recurrence, as it provides better local control than local excision. There is still some debate as to which is the single best choice of surgery and there have been multiple studies analysing the long-term outcomes of all surgical options. Although some studies suggested better local control with abdominoperineal resection (APR), the procedure itself is accompanied by a high morbidity rate and functional limitations. Most patients, however, have metastatic disease at presentation or ultimately develop distant metastasis. Therefore, it is up to the treating physician to determine the extent to which surgery can alleviate the burden and weigh the risk-benefit of the available surgical options, depending on the quality of life and individual patient preference [5, 12, 13].

Our patient underwent a laparoscopic abdominoperineal resection. van der Pas et al. conducted a trial wherein 1103 patients were randomly assigned to the laparoscopic and open surgery groups. Patients in the laparoscopic surgery group lost less blood than those in the open surgery group. However, laparoscopic procedures took longer. In the laparoscopic surgery group, bowel function returned sooner and hospital stay was shorter, reduced time to resumption of a normal diet and time to first defecation, as well as an improved physical function with less fatigue and fewer pelvic and urinary function at three months after operation [14].

Achieving negative margins seems to be the most important surgical prognostic factor. In a series of 251 cases from the Swedish National cancer registry, the five-year survival rates post-surgical excision for those in whom negative margins were obtained was 19 per cent, compared with 6 per cent in those in whom local excision was not possible [15].

Inguinal lymphadenectomy is performed in patients with apparent nodal disease. Radiotherapy is usually administered as an adjuvant, predominantly in patients who have undergone a sphincter-sparing excision.

Adjuvant chemotherapy in anorectal melanoma can be contemplated in patients following surgical resection of the primary anorectal tumour and with a high risk of recurrence. Dacarbazine is a frequently used agent in

metastatic melanoma and initiates a partial response in patients four to six months after treatment [16]. However, there is ongoing debate as to whether dacarbazine is a valid choice in the era of immune checkpoint therapy. Although immune checkpoint inhibitors are the preferred approach in patients with advanced or metastatic cutaneous melanoma, there is still limited evidence for their clinical use in mucosal melanoma. Therefore, even though dacarbazine is not the preeminent chemotherapy of choice in the modern-day management of melanoma, it can still be a logical choice in the management of progressive metastatic mucosal melanoma.

Platinum or capecitabine/temozolomide regimens can be considered. Temozolomide demonstrates efficacy equal to that of dacarbazine and is an oral alternative for patients with advanced metastatic melanoma [17]. Results of phase 2 randomised trial study published by Lian et al., revealed that both temozolomide-based chemotherapy and high-dose interferon(HDI) are effective and safe as adjuvant therapies for resected mucosal melanoma as compared with observation alone. However, HDI tends to be less effective than temozolomide-based chemotherapy for patients with resected mucosal melanoma with respect to relapse-free survival [18].

Despite the myriad of treatment choices mentioned above, advanced melanoma has for the most part remained an incurable condition. Targeted therapies have gained substantial traction over recent years. These include c-kit inhibitors, BRAF inhibitors, anti-CTLA-4 antibodies and anti-PD-1 antibodies. The absence of superior research designs for targeted therapy is something that still needs to be accounted for, as most of the available literature is of retrospective nature. A subset of tumours harbouring activating *KIT* mutations has been found to respond to c-Kit inhibitor-based therapy, with improved patient survival at advanced tumour stages [19]. PD-1 (programmed death ligand-1) monoclonal antibodies, nivolumab and pembrolizumab have been shown to prolong the median progression-free survival significantly in patients with mucosal melanoma [20].

#### 4. CONCLUSION

Melanomas of the anorectal region are mucosal in origin. They are aggressive tumours with poor prognoses. Presenting symptoms are non-

specific and do not aid in the definitive diagnosis of the disease. Confirmatory diagnostic modalities include histopathological evaluation and immunohistochemistry. The presence of metastatic lesions can be confirmed with an MRI, CT or PET scan. Surgical resection is the main treatment. It enables a definite diagnosis and can improve the symptom-free survival of the patient. Adjuvant radiotherapy, chemotherapy, and immunotherapy are the other treatment options. Despite an aggressive management approach, the disease maintains an average five-year survival rate of 20%.

#### CONSENT

Written informed consent was obtained from the patient for the publication of this case report and accompanying images.

#### ETHICAL APPROVAL

As per international standard or university standard written ethical approval has been collected and preserved by the author(s).

#### ACKNOWLEDGEMENTS

This research received no specific grant from any funding agency in the public, commercial, or not-for-profit sectors.

#### COMPETING INTERESTS

Authors have declared that no competing interests exist.

#### REFERENCES

1. Cagir B, Whiteford M, Topham A, Rakinic J, Fry R. Changing epidemiology of anorectal melanoma. *Dis Colon Rectum*. 1999;42(9):1203-1208. Available: <https://pubmed.ncbi.nlm.nih.gov/10496563/>
2. Chang AE, Karnell LH, Menck HR. The national cancer data base report on cutaneous and noncutaneous melanoma: a summary of 84,836 cases from the past decade. The American College of Surgeons Commission on Cancer and the American Cancer Society. *Cancer*. 1998;83(8):1664-1678. Available: [https://doi.org/10.1002/\(sici\)1097-0142\(19981015\)83:8<1664::aid-cnrcr23>3.0.co;2-g](https://doi.org/10.1002/(sici)1097-0142(19981015)83:8<1664::aid-cnrcr23>3.0.co;2-g)
3. Bello DM, Smyth E, Perez D, Khan S, Temple LK, Ariyan CE et al. Anal versus

- rectal melanoma: does site of origin predict outcome? *Diseases of the colon and rectum*. 2013;56(2):150-157.  
Available:<https://doi.org/10.1097/DCR.0b013e31827901dd>
4. Cooper PH, Mills SE, Allen Jr MS. Malignant melanoma of the anus: report of 12 patients and analysis of 255 additional cases. *Diseases of the colon and rectum*. 1982;25(7):693-703.  
Available:<https://doi.org/10.1007/BF02629543>
  5. Bullard KM, Tuttle TM, Rothenberger DA, Madoff RD, Baxter NN, Finne CO et al. Surgical therapy for anorectal melanoma. *Journal of the American College of Surgeons*. 2003;196(2):206-211.  
Available:[https://doi.org/10.1016/S1072-7515\(02\)01538-7](https://doi.org/10.1016/S1072-7515(02)01538-7)
  6. Fenger C, Lyon H. Endocrine cells and melanin-containing cells in the anal canal epithelium. *The Histochemical Journal*. 1982;14(4):631-639.
  7. Anwar S, Welbourn H, Hill J, Sebag-Montefiore D. Adenocarcinoma of the anal canal—a systematic review. *Colorectal Dis*. 2013;15(12):1481-1488.  
Available:<https://doi.org/10.1111/codi.12325>
  8. Sutherland CM, Chmiel JS, Henson DE, Winchester DP. Patient characteristics, methods of diagnosis, and treatment of mucous membrane melanoma in the United States of America. *Journal of the American College of Surgeons*. 1994;179(5):561-566.  
Available:<https://pubmed.ncbi.nlm.nih.gov/7952459/>
  9. Burgi A, Brodine S, Wegner S. Incidence and risk factors for the occurrence of non-AIDS-defining cancers among human immunodeficiency virus-infected individuals. *Cancer*. 2005;104(7):1505-1511.  
Available:<https://pubmed.ncbi.nlm.nih.gov/16104038/>
  10. Ni S, Huang D, Chen X, Huang J, Kong Y, Xu Y et al. C-kit gene mutation and CD117 expression in human anorectal melanomas. *Human Pathology*. 2012;43(6):810-807.  
Available:<https://doi.org/10.1016/j.humpath.2011.08.005>
  11. Keung EZ, Gershenwald JE. The eighth edition American Joint Committee on Cancer (AJCC) melanoma staging system: implications for melanoma treatment and care. *Expert Review of Anticancer Therapy*. 2018;18(8):775-784.  
Available:<https://doi.org/10.1080/14737140.2018.1489246>
  12. Available:<https://doi.org/10.1080/14737140.2018.1489246>
  13. Heeney A, Mulsow J, Hyland JMP. Treatment and outcomes of anorectal melanoma. *The Surgeon*. 2011;9(1):27-32.  
Available:<https://www.sciencedirect.com/science/article/pii/S1479666X10001721>
  14. Zhang S, Gao F, Wan D. Abdominoperineal resection or local excision? A survival analysis of anorectal malignant melanoma with surgical management. *Melanoma Research*. 2010;20(4):338-341.  
Available:<https://doi.org/10.1097/CMR.0b013e328339b159>
  15. van der Pas MH, Haglind E, Cuesta MA, Fürst A, Lacy AM, Hop WC et al. Laparoscopic versus open surgery for rectal cancer (COLOR II): short-term outcomes of a randomized, phase 3 trial. *The Lancet Oncology*. 2013;14(3):210-218.  
Available:<https://www.sciencedirect.com/science/article/pii/S1470204513700160>
  16. Nilsson PJ, Ragnarsson-Olding BK. Importance of clear resection margins in anorectal malignant melanoma. *The British Journal of Surgery*. 2010;97(1):98-103.  
Available:<https://doi.org/10.1002/bjs.6784>
  17. Middleton M, Grob J, Aaronson N, Fierlbeck G, Tilgen W, Seiter S, et al. Randomized phase III study of temozolomide versus dacarbazine in the treatment of patients with advanced metastatic malignant melanoma. *J Clin Oncol*. 2000;18(1):158-166.  
Available:<https://pubmed.ncbi.nlm.nih.gov/10623706/>
  18. Kim K, Sanguino A, Hodges C, Papadopoulos N, Eton O, Camacho L et al. Biochemotherapy in patients with metastatic anorectal mucosal melanoma. *Cancer* 2004;100:1478-1483.  
Available:<https://acsjournals.onlinelibrary.wiley.com/doi/10.1002/cncr.20113>
  19. Lian B, Si L, Cui C, Chi Z, Sheng X, Mao L, et al. Phase II randomized trial comparing high-dose IFN- $\alpha$ 2b with temozolomide plus cisplatin as systemic adjuvant therapy for resected mucosal melanoma. *Clin Cancer Res*. 2013;19(16):4488-4498.  
DOI: 10.1158/1078-0432.CCR-13-0739
  20. Yang H, Hsiao S, Schaeffer D. Identification of recurrent mutational events in anorectal melanoma. *Mod Pathol*. 2017;30:286-296.

- Available:<https://doi.org/10.1038/modpathol.2016.179>
21. Shoushtari A, Munhoz R, Kuk D. The efficacy of anti-PD-1 agents in acral and mucosal melanoma. Cancer. 2016;122(21):3354-3362. Available:<https://acsjournals.onlinelibrary.wiley.com/doi/full/10.1002/cncr.30259>

© 2023 Bhat and Prakash; This is an Open Access article distributed under the terms of the Creative Commons Attribution License (<http://creativecommons.org/licenses/by/4.0>), which permits unrestricted use, distribution, and reproduction in any medium, provided the original work is properly cited.

*Peer-review history:*  
*The peer review history for this paper can be accessed here:*  
<https://www.sdiarticle5.com/review-history/95913>