

Carotid Body Tumour a Challenging Management: Rare Case Report in Baghdad Radiation Oncology Center, Medical City, Baghdad, Iraq

**Khudair J. Al-Rawaq¹, Manwar A. Al-Naqqash^{2*}, Ahmed S. Al-Shewered³
and Ashraf F. Al-Awadi³**

¹*Radiation Oncology, Department of Surgery, College of Medicine, Baghdad University, Baghdad, Iraq.*

²*Radiation Oncology and Histopathology, Department of Surgery, College of Medicine, Baghdad University, Baghdad, Iraq.*

³*Diplomatic, Radiation Oncology, Baghdad Radiation Oncology Center, Medical City, Baghdad, Iraq.*

Authors' contributions

This work was carried out in collaboration between all authors. Author KJAR wrote the protocol. Author MAAN managed the analysis of the study and literature search. Authors ASAS and AFAA designed the study and wrote the first draft of the manuscript. All authors read and approved the final draft of the manuscript.

Article Information

DOI: 10.9734/JCTI/2018/40034

Editor(s):

(1) Bing Yan, Department of Oncology, Hainan Branch of PLA General Hospital, China.

Reviewers:

(1) Mehmet Düzlü, Gazi University, Turkey.

(2) Luis Pacheco-Ojeda, Ecuador.

(3) Gerardo Caruso, University of Messina, Italy.

(4) Okechi Uchenna Chukwuemeka, College of Medicine, University of Nigeria, Nigeria.

(5) Shivani Chauhan, Meerut Institute of Engineering and Technology, India.

Complete Peer review History: <http://www.sciencedomain.org/review-history/24136>

Case Report

Received 7th January 2018

Accepted 13th March 2018

Published 12th April 2018

ABSTRACT

Background: Paragangliomas are rare asymptomatic painless tumours, originating from paraganglionic bodies of autonomous nerve system. The carotid body tumours are the relatively rare tumour but constitute a majority of head and neck paragangliomas about 70%. These tumours are benign but possess aggressive local growth potential.

The Aim of the Study: The purpose of this case report article is to introduce the challenging we exposed to it during management such cases in our country despite lack many conditions, facilities

*Corresponding author: Email: ahmeds201258@yahoo.com;

and circumstances found in other parts of the world for treatment of CBT, which is the first time study in Iraq.

Case Presentation: We reported a case of the 27-year-old female patient with a left neck swelling that had persisted for 5 years. She was first diagnosed and treated surgically by local excision in 2012. Histopathology revealed the histology of carotid body tumour. She has complained of hypertension, headache, and palpitation. She was observed the gradual onset of growing and pulsating lump on previous surgical scar site. Five years later, the lesion became larger, and she feeling pulsation on lying on left side resulting in discomfort on sleep and deglutition. On physical examination, a pulsating firm painless mass measuring about 6 x 5 x 4 cm in size was found on the left side of her neck. Pulsations were felt on deep palpation and a faint bruit was heard on auscultation. Work up done for her included laboratory tests, neck US, neck CT scan, carotid angiography and slide review of histopathology. All suggested recurrent carotid body tumour.

Conclusion: Over forty years of working in this field, we have only seen 3 cases of CBTs, so it is a very rare tumour. Management of this tumour is a challenging whether it is treated by surgery or radiotherapy. The main step in management is by excluding others tumours can be found in this region. Surgery is a treatment of choice while radiotherapy is standard treatment for recurrent cases.

Keywords: Carotid body tumour; paraganglioma; chemodectoma; glomus cells; carotid arteriography.

ABBREVIATIONS

CBT: Carotid body tumour; COPD: Chronic obstructive pulmonary diseases; CCA: Common carotid artery; ICA: Internal carotid artery; ECA: External carotid artery; PG: Paraganglioma; FNA: Fine needle aspiration; US: Ultra sound; CT: Computed tomography; MRA: Magnetic resonance arteriography; 3D: Three-dimensional; RT: Radiotherapy; CBC: Complete blood pictures; RFT: Renal function tests; LFT: Liver function tests; Gy: Gray; LAP: Lymphadenopathy; SOL: Space occupy lesion.

1. INTRODUCTION

Carotid body tumour (CBT) or chemodectoma is a rare, highly vascular, mostly benign tumour arising from the paraganglia of carotid body [1]. CBTs are nonchromaffin paragangliomas arising from the chemoreceptor cells found at the carotid bifurcation. A tumour is highly vascular; its blood supply is the richest per gram of tissue of any a tumour [1]. The carotid body, which originates in the neural crest, is essential in the body's acute adaptation to fluctuating concentrations of oxygen, carbon dioxide, and pH [2]. The carotid body protects the organs from hypoxic damage by releasing neurotransmitters that increase the ventilatory rate when stimulated [2,3]. There are three different types of CBTs have been described: familial, sporadic and hyperplastic. The sporadic form is the most common type. The familial type (10-20%) is more common in younger patients. The hyperplastic form is very common in patients with chronic hypoxia, which includes those patients living at a high altitude and may be found in patients with COPD and cyanotic heart diseases. The first anatomical description of the carotid body was provided by Albrecht Von Haller in 1743 [2,3,4].

Histologically, carotid body tumours have a characteristic growth pattern often referred to as a zellballen [5,6]. Carotid body tumours occur at any age but are typically diagnosed between the third and sixth decades of life [5,7,8]. The usual presentation is a slow growing mass at the angle of mandible [2,4,9]. Its management must involve thorough evaluation for primary tumour of the thyroid, the oropharynx, and the nasopharynx is essential, since metastases to a cervical lymph node is a much more frequent cause of a neck mass than CBTs [9]. Carotid body tumors can be a diagnostic challenge for the clinician and lack of pre-operative diagnosis has been reported in up to 30% of the cases in different series [4]. The diagnostic work-up of CBT may involve one or more of the following: Doppler US scanning, CT, MRI, MRA, carotid arteriography, and serum and urinary catecholamine level assessment [2]. The treatment modalities for CBTs are surgical excision and/or radiotherapy [5,9,10,11,12,13].

2. CASE PRESENTATION

A 27 year-old female patient presented with a left neck swelling that had persisted for 5 years. She was first treated by local excision in a private

hospital five years ago. Pathology revealed the histology of carotid body paraganglioma. She was in good health for two years before she developed her signs and symptoms of catecholamine excess such as hypertension, headache, palpitation, and weight loss. She was consulted many doctors and clinics for her problem and she kept on medical treatment and follow up. In the last nine months she observed gradual onset of growing and pulsated lump on previous surgical scar site. Suddenly two weeks prior to her presentation to Baghdad Radiation Oncology Center, the mass rapidly increased in size and she felt pulsation on is lying on left side resulting in discomfort on sleep and deglutition. Any information about past surgical data and past history of patient were missed in Iraq war against ISIS which included surgical file, IHC study and others investigations.

2.1 Physical Examination

A pulsating firm painless and well circumscribed mass measuring about 6 x 5 x 4 cm in size was found on the left side of her neck, near the angle of the mandible. There were pressure symptom and mobility is transversely than vertically. Pulsations were felt on deep palpation and a faint bruit was heard on auscultation. She complain of headache, tachycardia and hypertension.

2.2 Work Up

2.2.1 Laboratory tests

CBC, ESR, RFT, LFT, electrolytes balance and urine analysis were done and all were normal values. Catecholamine (vanilmandelic acid) levels in urine or serum was unavailable in our city.

2.2.2 Imaging

CXR and Echo study also done.

2.2.2.1 Neck US

It revealed highly vascular ill-defined hypoechoic solid mass seen above level of Left carotid bifurcation between ICA and ECA measured 35 x 20 mm, reaching up to lower border of parotid gland suggestive of recurrent CBT. Normal other structures.

2.2.2.2 CT scan of neck

It demonstrated a well-circumscribed lobulated hypervascular, hypoechogenic mass with

splaying of the carotid bifurcation. The mass was heterogeneously intense enhancing soft tissue density mass of size 38 x 24 x 25 mm. the findings suggested recurrent CBT. There were no infiltration into adjacent structures is seen. Both thyroid lobes were normal in size, echogenicity, normal isthmus, no cervical LAP, normal both submandibular salivary glands, normal neck vessels and no SOL.

2.2.2.3 Carotid angiography of neck

It showed a well-defined highly vascular blush mass (density is 250 HU while in the carotid artery is 340 HU), is about 33 x 27 x 25 mm, located at the lateral to both ICA and ECA of left carotid arteries and about 2 cms above the carotid bifurcation. Mass is not intrinsic to blood vessels & patency of the artery was preserved. This finding was considered to be consistent with a diagnosis of recurrent CBT. In compares with previous carotid angiography done in June 2012, there was irregular solid oval soft tissue density mass 63 x 39 x 27 mm in size seen in left upper neck in left retro mandibular region beneath left sternomastoid muscle, extending from level of below left parotid gland down to below mandibular angle. It was vascular mass and protruding between ICA and ECA. There was no cervical LAP. The features were CBT. Octreotide scan is not done because of it unavailable in our country and is so much expensive.

2.3 Histopathology

The previous histopathology done in 2012 showed. Grossly there was a globular piece of tissue measured 5 x 3 x 2 cm, with a grey brown cut section, also there were three firm grey nodes. Histologically, the sections showed well defined nests of uniform cuboidal cells (Zellballen) with abundant granular basophilic cytoplasm, separated by highly vascularized fibrous septa. There was no mitoses or necrosis seen. The picture was consistent with carotid body tumour CBT. The three LNs showed reactive follicular hyperplasia. The slide review done and give the same result.

3. TREATMENT

At that time, the mass was quite large in size and attached to left common carotid artery. Therefore, surgery was not suitable, because of very high risk for surgical injury to these vessels and nerves as this was a recurrent case. Finally,

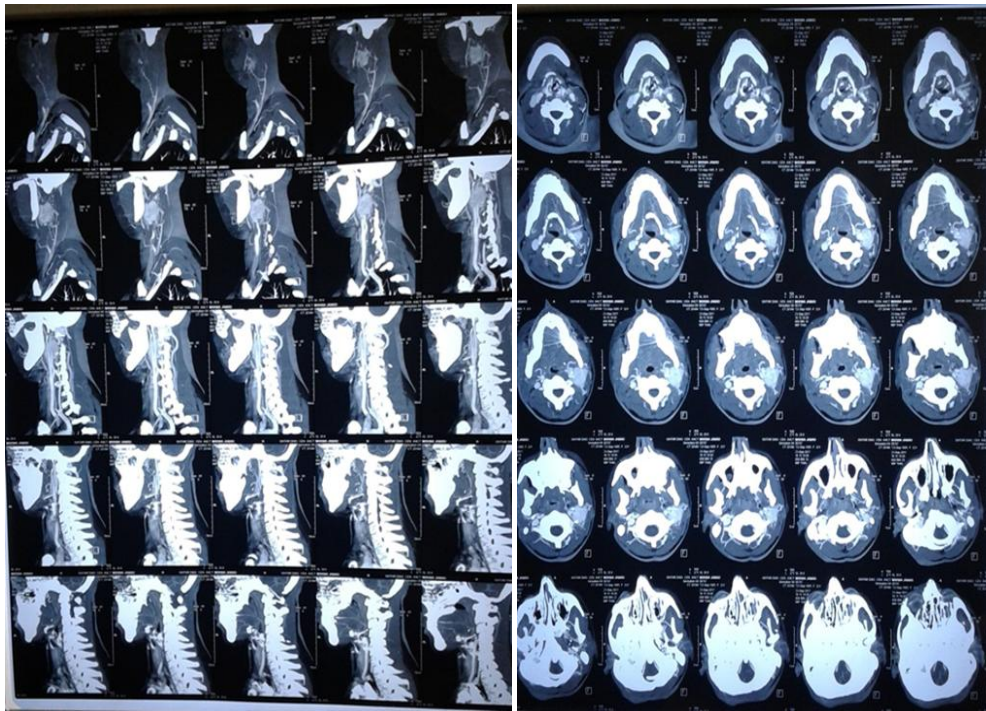


Fig. 1. Head and neck CT scan (axial and sagittal plan)

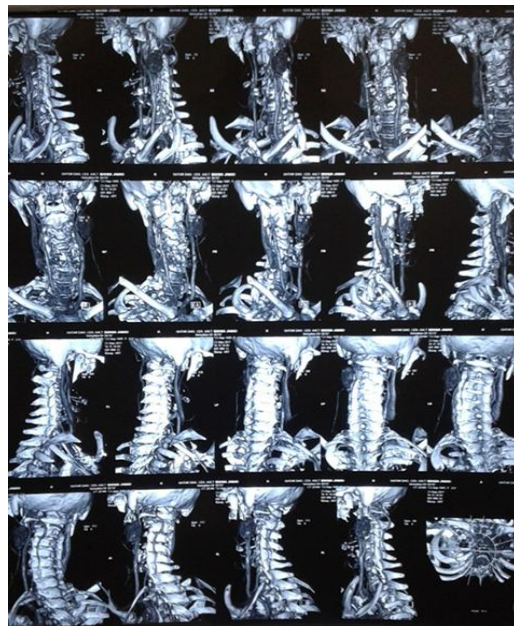


Fig. 2. Carotid angiography

she was referred to our radiotherapy unit for definitive radiotherapy. The radiation technique was 3D-conformal radiotherapy (3D-CRT) with 2 Gy/daily fraction to the total dose of 50 Gray in 25 Fractions. The GTV (gross target volume),

which was defined as gross tumor, was shown on contrast CT scan. The CTV (clinical target volume) was the volume including GTV and 1 cm margin around. The PTV (planning target volume) was the volume including CTV and 1 cm

margin around. The normal tissue constraint was limited within tolerance dose.

4. FOLLOW UP

There was not any complications regarding post radiation courses therapy. Symptoms like hypertension, palpitation, and flushing were disappeared. The tumor size was regressed regarding last neck U/S, and she will wait for the result of neck CT scan and CT angiography. She was planning for follow up every two months in this year.

5. DISCUSSION

Carotid body tumors CBTs are rare and uncommon entities may be found in unilateral or both sides of the neck and in both genders at the different rate of frequency, and they belong mostly to a benign group of tumors and their surgical management is technically challenging. The most common presentation in patients with CBT is a slowly enlarging painless mass in the neck. Locally invasive growth of these tumors subsequently leads to cranial nerve deficits along with compression symptoms like Horner's syndrome, syncope, hoarseness and dysphagia since the carotid body functions as a chemoreceptor organ that is stimulated by hypoxia, hypercapnea, and acidosis, it is involved in the control of blood pressure, heart rate, and respiration [1,3,5,11,13]. CBD are slow growing painless masses localized in the neck, anterior to the sternocleidomastoid muscle at the level of the hyoid bone. As the tumour grows, dysphagia, odynophagia, dysphonia, and symptoms due to compression of cranial nerves IX to XII may be seen. The most commonly involved cranial nerve is the vagus, up to one third of all cases will show cranial nerve palsies [3,5,8,11].

US is the first non-invasive procedure which allows discrimination between the solid and cystic nature of the mass. Carotid arterial angiography is the most valuable diagnostic technique, it is the gold standard for diagnosis is carotid angiography, which serves both diagnostic and treatment purposes. MRI and CT angiography can demonstrate the extent of the tumor and its relationship to adjacent structures [2,7,8].

There are many choices of treatment for CBD including observation, surgery, external beam radiotherapy, and stereotactic radiotherapy.

Surgery is the treatment of choice. The local control by surgery alone is approximately 85-100%. Most of the reports demonstrated local control with radiotherapy alone is approximately 80-90% comparable to surgery [10,11,13]. Depending on the size and location of the lesions, the indication for RT may be either:

1. Primary irradiation in the case of functional or other inoperability.
2. Adjuvant irradiation for R1 to R2 resections.
3. Irradiation of recurrence if there is progression after surgery [2,12].

Treatment with radiotherapy can achieve comparable local control and less morbidity than surgical resection in paraganglioma. Regarding definitive radiation treatment of CBTs. There are many techniques, protocols and radiation dose ranges of treatment. Although stereotactic radiotherapy has been increasingly used and their results have been generally accepted, conventional radiotherapy and 3D radiotherapy are still commonly used in the place where stereotactic radiotherapy is not available. Many reports used a radiation dose of 45 Gy in 25 fractions, with a daily dose of 1.8 Gy [3,5,6,12]. Continued follow-up is necessary, however, as recurrence and metastasis may occur years later [12].

6. CONCLUSION

CBT is a rare paraganglionic tumour affecting both sex of reproductive age. Treatment of choice is surgery. Radiotherapy is standard treatment in recurrent and inoperable cases. Since late recurrences are known, patients should be adequately followed up so that recurrences can be identified early and treatments offered. The limitation of this study is that Immunohistochemistry was not done to support the histological diagnosis and was because the markers for this technique are currently out of stoke in country.

CONSENT

All authors declare that 'written informed consent was obtained from the patient (or other approved parties) for publication of this case report and accompanying images.

ETHICAL APPROVAL

All authors hereby declare that all experiments have been examined and approved by the

appropriate ethics committee and have therefore been performed in accordance with the ethical standards laid down in the 1964 Declaration of Helsinki.

COMPETING INTERESTS

Authors have declared that no competing interests exist.

REFERENCES

1. Abdulsalam YT. Carotid body tumours: A review. *International Journal of Clinical Medicine*. 2015;6:119-13. Available:<http://dx.doi.org/10.4236/ijcm.2015.63017>
2. Gupta B, Mitra JK. Anaesthetic management of chemodectoma excision. *The Indian Anesthetists', Forum*; 2014. Available:www.theiaforum.org
3. Shibuyaa Y, Umedab M, Yoshikawab T, et al. Carotid body tumour: Case report. *Oral Oncology*. 2002;38:313-317. Available:[http://dx.doi.org/10.1016/S1368-8375\(01\)00057-4](http://dx.doi.org/10.1016/S1368-8375(01)00057-4)
4. Tayyab M, Khan, MR, Sophie Z. Presentation and management of carotid body tumors. *Journal of Pakistan Medical Association*. (Serial Online). 2003;53. Available:http://www.jpma.org.pk/full_article_text.php?article_id=227
5. Wang SJ, Wang MB, Barauskas TM, Calcaterra TC. Surgical management of carotid body tumors. *Otolaryngology Head and Neck Surgery*. 2000;123:202-206. Available:<http://dx.doi.org/10.1067/mhn.2000.106709>
6. Wieneke JA, Smith A. Paraganglioma: Carotid body tumor. *Head and Neck Pathology*. 2009;3:303-306. Available:<http://dx.doi.org/10.1007/s12105-009-0130-5>
7. Boedeker CC. Paragangliomas and paraganglioma syndromes. *GMS Current Topics in Otorhinolaryngology, Head and Neck Surgery* [Serial Online]; 2011. Available:<http://www.egms.de/static/en/journals/cto/2012-10/cto000076.shtml>
8. O'Neill S, O'Donnell M, Harkin D, Loughrey M, Lee B, Blair P. A 22-Year northern Irish experience of carotid body tumours. *Ulster Medical Journal*. 2011;80:133-140.
9. Patetsios P, Gable DR, Garrett WV, Lamont JP, Kuhn JA, Shutze WP, et al. Management of carotid body paragangliomas and review of a 30-year experience. *Annals of Vascular Surgery*. 2002;16:331-338. Available:<http://dx.doi.org/10.1007/s10016-001-0106-8>
10. Ferreira J, Canedo A, Braga S, Vasconcelos J, Gouveia R, Martins V, et al. Carotid body tumours resection with ultrasound dissector. *Chinese Medical Journal*. 2013;126:586-588.
11. Suarez C, Rodrigo JP, Mendenhall WM, Hamoir M, Silver CE, Grégoire V, et al. Carotid body paragangliomas: A systematic study on management with surgery and radiotherapy. *European Archives of Oto-Rhino-Laryngology*, (Serial Online). 2013;271:23-34. Available:<http://link.springer.com/article/10.1007/s00405-013-2384-5>
12. Gunderson LL, Tepper JE. *Clinical radiation oncology: Benign diseases, glomus tumor or chemodectoma*. 4th ed. Elsevier, Inc. 2016;1375-6.
13. Casciato DA, Territo MC. *Manual of clinical oncology: Miscellaneous neoplasms, paragangliomas*. 7th ed. Lippincott Williams & Wilkins, a Wolters Kluwer business. USA; 2012.

© 2018 Al-Rawaq et al.; This is an Open Access article distributed under the terms of the Creative Commons Attribution License (<http://creativecommons.org/licenses/by/4.0>), which permits unrestricted use, distribution, and reproduction in any medium, provided the original work is properly cited.

Peer-review history:
The peer review history for this paper can be accessed here:
<http://www.sciencedomain.org/review-history/24136>